

**DARIUS M. MOSHFEGHI, MD**

Cole Eye Institute, The Cleveland Clinic

HILEL LEWIS, MDProfessor and Chairman, Division of
Ophthalmology; Director, Cole Eye Institute,
The Cleveland Clinic

Age-related macular degeneration: Evaluation and treatment

ABSTRACT

Any patient age 50 or older with distorted vision or vision loss may have age-related macular degeneration and should be immediately referred to an ophthalmologist. Early diagnosis and treatment are essential to preserve the current level of vision. We outline risk factors, clinical signs, what happens to the retina, and what treatments are currently available, as well as recommendations about vitamin and mineral supplementation.

KEY POINTS

Hypertension should be maximally controlled and all patients who smoke should be encouraged to quit, as smoking leads to a poorer outcome.

In accordance with the results of the Age-Related Eye Disease study, patients over age 55 with evidence of macular degeneration should take vitamin C 500 mg, vitamin E 400 IU, beta-carotene 15 mg (unless the patient smokes), and zinc (80 mg) every day.

For patients with the dry form of macular degeneration, visits to an ophthalmologist every 6 months and daily home Amsler grid testing are sufficient to monitor the disease, usually beginning at age 50.

In patients with the wet form of macular degeneration, laser photocoagulation is effective in juxtafoveal and extrafoveal neovascularization, but not in most cases if the new vessel growth is subfoveal.

P RIMARY CARE PHYSICIANS attuned to the signs and symptoms of age-related macular degeneration can help patients preserve their vision by referring them for immediate evaluation by an ophthalmologist, as well as controlling any hypertension and encouraging smoking cessation.

Age-related macular degeneration is the leading cause of new blindness in patients older than 60 years in the United States.¹⁻⁸ It tends to progress slowly, but when it reaches the point of choroidal neovascularization, the loss of sharp, central vision needed to read street signs and fine print and to recognize faces can be sudden, severe, and irreversible. Early diagnosis is critical to preserve vision and prevent additional loss.

In this article, we outline the clinical signs and visual symptoms that should suggest age-related macular degeneration. We also discuss treatments, as well as dietary supplements that lower the risk of progression of the condition.

PREVALENCE AND INCIDENCE

In population-based studies, the prevalence of age-related macular degeneration ranged from 1.2% to 1.8% and increased with age.^{2,3,6,7,10} In 1992, Klein et al⁷ estimated that about 640,000 people in the United States age 75 or older have signs of advanced macular degeneration, and 315,000 people will develop late-stage macular degeneration over a 5-year period.⁹ However, it is currently estimated that there are approximately 14 million Americans with age-related macular degeneration, with 1 million new cases per year.

Drusen

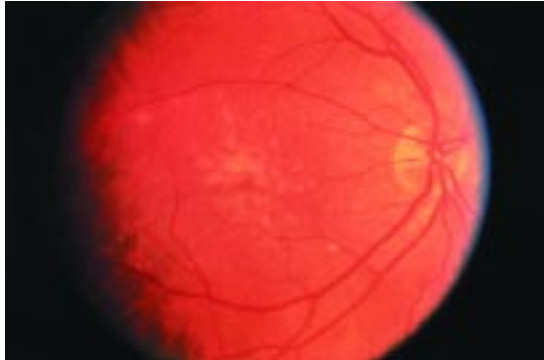


FIGURE 1. Numerous soft drusen are noted to coalesce beneath the retina in the macula.

■ RISK FACTORS

Although epidemiologic studies suggested a wide variety of risk factors,¹⁻¹⁵ including female gender,⁷ a recent meta-analysis¹⁰ concluded that the only significant ones are:

- Age > 50 years
- White race
- Smoking.

■ MACULAR DEGENERATION HAS TWO FORMS

Age-related macular degeneration exists in two forms: atrophic (“dry”) and exudative (“wet”). About 80% to 85% of people with macular degeneration have the dry form. Wet macular degeneration accounts for 15% to 20% of cases, but 90% of the severe loss of vision due to the disorder.

■ ATROPHIC (‘DRY’) MACULAR DEGENERATION

Macular degeneration usually starts with tiny yellow subretinal deposits called drusen (**FIGURE 1**). Many patients older than 50 years develop drusen, most commonly in the macula. Drusen do not affect vision, and most people with drusen do not develop macular degeneration. However, one must have drusen to develop age-related macular degeneration.

Over time, drusen can coalesce and lead to geographic atrophy of the macula (**FIGURE 2**), with loss of retinal pigment epithelium, degeneration of the overlying photoreceptors, and gradual loss of central visual acuity.

Atrophy

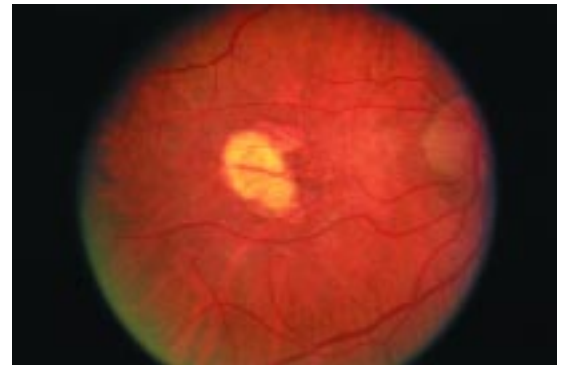


FIGURE 2. Atrophy with sharply delimited borders and visible choroidal vessels overlying the fovea.

Because it tends to progress slowly, dry macular degeneration does not usually cause sudden, severe vision loss. But it can progress to the wet form, so patients should be encouraged to see their ophthalmologist regularly.

Treatment of dry macular degeneration is usually limited to vision aids. No treatment exists for the dry form once it involves the center of the fovea.

■ EXUDATIVE (‘WET’) MACULAR DEGENERATION

Wet macular degeneration is characterized by choroidal neovascularization—abnormal growth of blood vessels in the choroid membrane that underlies the retina. The neovascularization extends anteriorly through a defect in the Bruch membrane to the space under the retinal pigment epithelium, under the sensory retina, or both places, leading to accumulation of subretinal fluid, blood, lipid, or all three (**FIGURE 3**).

This condition can progress rapidly and cause permanent vision loss, so early diagnosis and treatment and regular visits to the ophthalmologist are critical.

Clinical features of choroidal neovascularization

Patients with choroidal neovascularization may report diminished, distorted, or blurred visual acuity (**TABLE 1**). Patients with hemorrhage often describe a cloud or haze obscuring their vision; occasionally, they see “floaters” or

The wet form is much less common but more damaging than the dry form

Choroidal neovascular membrane

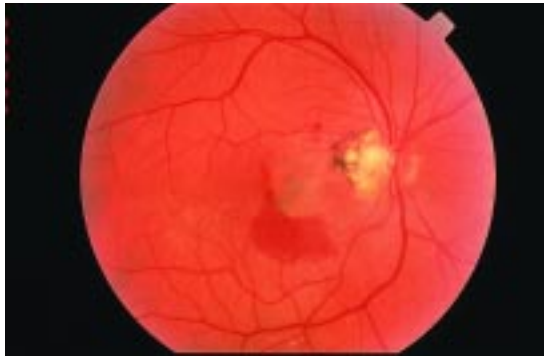

FIGURE 3. A choroidal neovascular membrane with subretinal hemorrhage and lipid exudates.

Pigment epithelial detachment

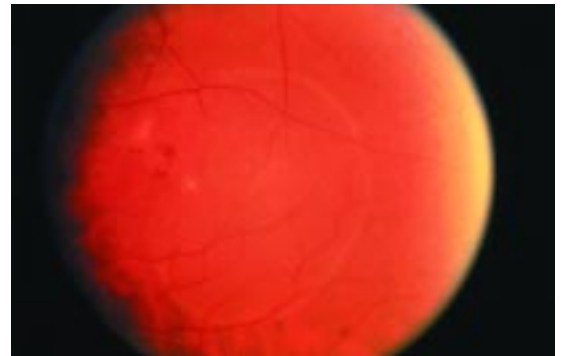


FIGURE 4. A pigment epithelial detachment with a blister-like appearance in the macula.

TABLE 1

Common symptoms of age-related macular degeneration

- Decreased visual acuity
- Metamorphopsia
- Blurred visual acuity
- Dark spot in the visual field (scotoma)
- Foggy vision/haze
- Difficulty reading
- Floaters
- Sparks or flashes (photopsia)

Wet macular degeneration can progress rapidly and cause permanent vision loss

flashing lights, similar to the symptoms of retinal detachment. Patients who report any distortion of their visual acuity should contact an ophthalmologist immediately for an evaluation.

On funduscopic examination, choroidal neovascularization may present as detachment of the pigment epithelium, subretinal fluid, subretinal hemorrhage, subepithelial or intraepithelial lipid, vitreous hemorrhage, pigment epithelial tear, or, in the late stage, a disciform scar.

Pigment epithelial detachment is a well-demarcated, dome-shaped elevation of the retinal pigment epithelium sometimes accompanied by pigment clumping.¹⁶ The fluid may be clear or mildly turbid, and the detachment may have a blister-like appearance (**FIGURE 4**). A pigment epithelial detachment does not necessarily mean that choroidal neovascularization is present, since coalesced drusen can

lead to a localized pigment epithelial detachment.

Subretinal blood and lipid and subretinal fluid are strongly associated with choroidal neovascularization.¹⁶ Subretinal hemorrhage can track under the macula, leading to a sudden and considerable decrease in visual acuity (**FIGURE 5**).

Vitreous hemorrhage occurs when subretinal blood breaks through the retina.

A **pigment epithelial tear** can result when choroidal neovascularization exerts tractional forces on the retinal pigment epithelium monolayer.

Disciform scar. In long-standing cases, choroidal neovascularization most often results in a disciform scar, characterized by subretinal fibrosis and lipid exudation (**FIGURE 6**).

Angiographic features of choroidal neovascularization

After undergoing an ocular examination, patients with suspected wet macular degeneration then undergo intravenous fluorescein angiography, which helps confirm the diagnosis and identify the type of neovascularization and the extent of the problem. This test is contraindicated in patients who are pregnant or who have liver disease.

Fluorescein angiography involves taking a rapid series of photographs (not radiographs) of the back of the eye for up to 30 minutes after injecting fluorescein or indocyanine green into an arm vein. The angiographic appearance of choroidal neovascularization in age-related macular degeneration is classified as either classic or occult.



Subretinal hemorrhage

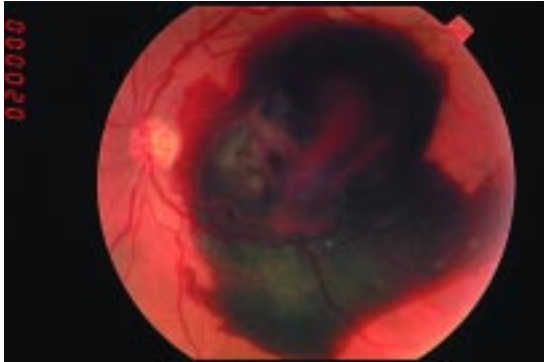


FIGURE 5. A subretinal hemorrhage within the macular region.

Classic neovascularization is defined as “an area of choroidal hyperfluorescence with well-demarcated boundaries” discernible early during angiography.¹⁷ Early in the study the hyperfluorescence can appear lace-like; in later frames, leakage and pooling of the fluorescein dye can obscure the original boundaries of the choroidal neovascularization (FIGURE 7).¹⁷ The classic type is uncommon in age-related macular degeneration.

Occult neovascularization refers either to fibrovascular pigment epithelial detachments or to late leakage from an undetermined source.¹⁷ Late leakage can appear as an area of speckled hyperfluorescence and dye pooling in the subretinal space in the late phases of angiography; these areas do not correspond to drusen or areas of atrophy of the retinal pigment epithelium. Occult neovascularization accounts for the vast majority of cases of choroidal neovascularization in patients with wet macular degeneration.

■ OVERVIEW OF TREATMENTS

The treatment of macular degeneration depends on the findings on funduscopic examination and fluorescein angiography and on the results of previous interventions.

A number of treatments are available, each with its own specific indications; these include:

- Laser photocoagulation
- Ocular photodynamic therapy
- Macular translocation
- Submacular surgery
- Vitamin supplements.

Disciform scar

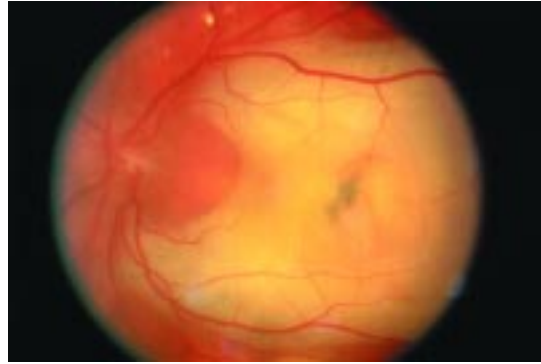


FIGURE 6. A disciform scar with subretinal fibrosis overlies the macula.

■ LASER PHOTOCOAGULATION

Laser photocoagulation of abnormal choroidal blood vessels is the most commonly used treatment for preserving vision in patients with wet macular degeneration.

Macular Photocoagulation Study

The Macular Photocoagulation Study, a prospective, multicenter, controlled trial, evaluated the effectiveness of laser photocoagulation for the treatment of wet macular degeneration.¹⁸ The study had three arms, based on the location of the neovascularization with respect to the fovea:

- **Extrafoveal** (200–2,500 μm from the center of the foveal avascular zone)
- **Juxtafoveal** (within 1–200 μm of the fovea)
- **Subfoveal** (beneath the fovea).

Results of extrafoveal argon laser treatment. This arm was terminated early because the treatment was beneficial: at 6 months, severe visual loss had occurred in 25% of treated patients vs 60% of untreated patients ($P < .001$).¹⁸ The benefit persisted at 3 years (52% vs 68%; $P < .004$)¹⁹ and at 5 years (46% vs 64%).²⁰ At 6 months, the relative risk of developing severe visual loss from baseline was 1.5 among untreated patients vs treated patients ($P = .001$).²⁰ However, lesions recurred in 54% of treated patients by the end of 5 years.²⁰

Results of juxtafoveal krypton laser treatment. At 3 years, severe visual loss had occurred in 49% of treated patients vs 58% of untreated patients ($P = .02$).²¹ The benefit

Laser is the most common treatment for wet macular degeneration

Classic choroidal neovascularization

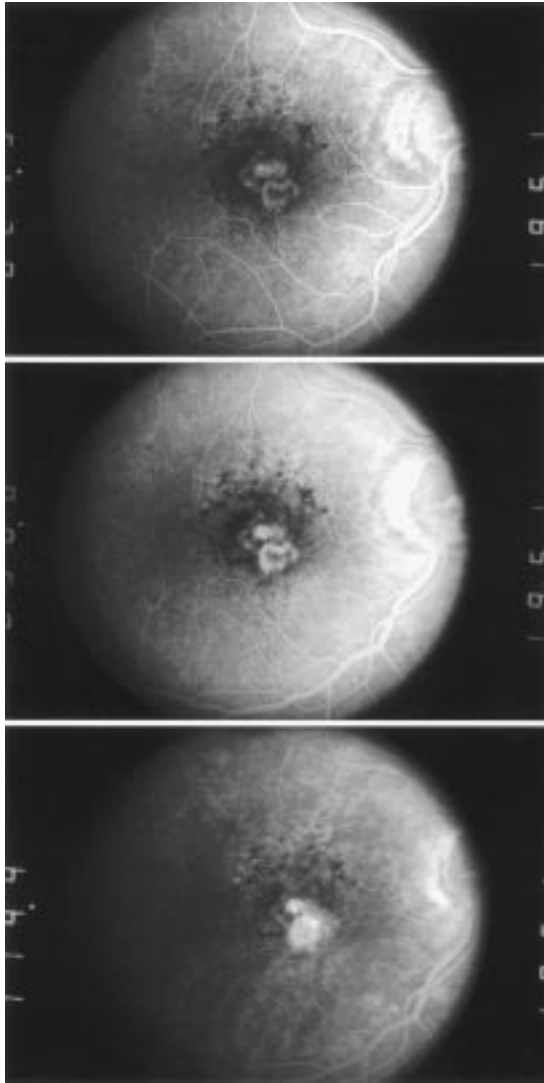


FIGURE 7. Classic choroidal neovascularization on early- and late-frame angiography.

Laser to the fovea poses risk of vision loss

was greatest among patients without hypertension.²¹ Persistent choroidal neovascularization, defined as angiographic evidence of choroidal neovascularization with 6 weeks of treatment, was detected in 32% of patients.²² The relative risk of severe visual loss from baseline among untreated patients vs treated patients was 1.2 from 6 months through the 5-year follow-up ($P = .04$).²³ The relative risk among untreated normotensive patients vs treated normotensive patients was 1.82.²³ The rate of recurrent choroidal neovascular-

ization was 41.7% by 5 years, with an estimated 78% rate of persistence or recurrence at 5 years.²³

Results of subfoveal argon or krypton laser treatment. Laser photocoagulation to the fovea carries the risk of immediate, irrecoverable loss of central visual acuity. At 3 months, severe visual loss had occurred in 20% of laser-treated eyes vs 11% of untreated eyes.²⁴ By 24 months, however, this trend had reversed itself, with severe visual loss in 20% of treated eyes vs 37% of untreated eyes.²⁴ These benefits persisted at 4 years (22% vs 47%; $P = .002$).²⁵ Lesions persisted or recurred in 51% of treated eyes.²⁴

Treatment of recurrent lesions. This arm of the study also included an evaluation of argon or krypton laser photocoagulation for recurrent choroidal neovascularization resulting in large losses of visual acuity in patients with subfoveal involvement.²⁶ By 24 months, severe visual loss had occurred in 9% of laser-treated eyes vs 28% of untreated eyes.²⁶ These benefits persisted at 3 years (12% vs 36%; $P = .009$).²⁵

The investigators concluded that laser photocoagulation is warranted for the subgroup of patients with subfoveal choroidal neovascularization with the following features:

- Classic type
- Well-demarcated boundaries
- No larger than 3.5 disc areas (1 disc area = 1.77 mm²).²⁷

The rate of persistent choroidal neovascularization was 13%, with a 3-year rate of recurrence of 35%.²⁸ The investigators concluded that patients with smaller subfoveal lesions and moderate or poor visual acuity tended to have better outcomes than those with larger lesions and moderate or good visual acuity.²⁹

Currently, we do not recommend photocoagulation for subfoveal choroidal neovascularization.

■ OCULAR PHOTODYNAMIC THERAPY FOR SUBFOVEAL LESIONS

The Macular Photocoagulation Study demonstrated the efficacy of laser photocoagulation for extrafoveal and juxtafoveal choroidal neovascularization. However, few patients with



subfoveal lesions qualified for this treatment because either their lesions were too large, the lesions had poorly defined boundaries, they had visual acuity better than 20/200, or they had no evidence of classic neovascularization.^{25,26,29} This, combined with the high rates of persistence and recurrence, prompted the search for alternative therapies.

One such new therapy is ocular photodynamic therapy, which involves the injection of a lipophilic photosensitizer, verteporfin (Visudyne), intravenously over 10 minutes. The dye is allowed to reach the choroidal circulation, at which time it is activated by a 689-nm diode laser. The laser activation excites the photosensitizer to a triplet state, creating oxygen species that damage endothelial cells, which ultimately occludes the neovascular membranes by activating the clotting cascade.^{30,31} Studies in nonhuman primates demonstrated this vascular occlusion both angiographically and histologically,^{32–35} and phase 1 and 2 studies were promising.^{36,37}

Evidence of effectiveness

The Treatment of Age-Related Macular Degeneration with Photodynamic Therapy study³⁸ consisted of two identical randomized, multicenter, controlled trials designed to determine if ocular photodynamic therapy with verteporfin could reduce the risk of moderate visual loss (loss of < 15 letters or approximately 3 lines of vision on a Snellen test) in patients with wet macular degeneration with subfoveal choroidal neovascularization.³⁸

At 1-year follow-up, 61% of treated eyes vs 46% of placebo-treated eyes showed no evidence of progression to moderate visual loss ($P < .001$).³⁸ Patients with predominantly classic-type neovascularization had a more pronounced treatment benefit (67% of treated eyes vs 39% of placebo-treated eyes showed no progression to moderate visual loss, $P < .001$).³⁸ There was no treatment benefit in patients whose lesions were less than 50% classic.³⁸ The 2-year results supported these findings.³⁹

Recommendations

Ocular photodynamic therapy is currently recommended for patients with predominantly classic subfoveal choroidal neovascularization

related to wet macular degeneration. Over 2 years, a patient receives a median of 5.6 treatments.³⁹ Patients tolerate the procedure well, with the most frequent complications being visual disturbance, reaction at the injection site, photosensitivity reactions, and infusion-related back pain.⁴⁰ Following treatment, patients are cautioned to avoid exposure to sunlight for a period of 48 hours.⁴⁰

A recent study demonstrated that this procedure is somewhat more effective than placebo at preventing visual loss in patients with purely occult lesions, but approval has not yet been granted for this treatment.

■ MACULAR TRANSLOCATION

Macular translocation is the surgical relocation of the central neurosensory retina or fovea intraoperatively or postoperatively specifically for the management of macular disease.⁴¹

The rationale for macular translocation is to preserve foveal photoreceptors from an area of recent damage (ie, subretinal fluid or hemorrhage) by moving them to an area with relatively healthy retinal pigment epithelium.⁴¹ Once the fovea has been translocated, the choroidal neovascularization (which remains in place anchored to the underlying retinal pigment epithelium) can be treated using traditional photocoagulation, thereby sparing the foveal photoreceptors.

Numerous techniques have been described and tested^{42–56}; however, macular translocation is still considered experimental and awaits rigorous testing in controlled clinical trials.⁵⁷

■ SUBMACULAR SURGERY

Submacular surgery is another intervention still considered experimental and in need of rigorous testing in controlled clinical trials. It was developed as an alternative to macular photocoagulation for subfoveal choroidal neovascularization secondary to ocular histoplasmosis.^{58–61} The technique involves a standard three-port pars plana vitrectomy with removal of the posterior hyaloid, creation of a retinotomy away from the foveal center, and mechanical removal of the choroidal neovascularization with forceps.

Ocular photodynamic therapy is recommended for classic subfoveal choroidal neovascularization



Gass⁶² postulated that removal of the choroidal neovascularization in age-related macular degeneration would result in stripping of the retinal pigment epithelium, with subsequent poor visual outcome, whereas in ocular histoplasmosis the neovascularization is removed without damaging the retinal pigment epithelium, with a resultant increase in visual acuity. To date, most reports have supported this contention.^{63,64}

However, enough success was seen that several trials of the procedure were started.^{65–67} The first results, published in 2000, indicated that, for patients with recurrent extrafoveal or juxtafoveal choroidal neovascularization secondary to age-related macular degeneration following laser photocoagulation, there was no difference in outcome between repeat laser photocoagulation or submacular surgery.⁶⁸ Furthermore, a companion report indicated no lifestyle change between the two treatment groups.⁶⁹ Further reports are expected in the next few years.

■ VITAMIN SUPPLEMENTATION

The Age-Related Eye Disease Study

The Age-Related Eye Disease Study was a multicenter, randomized, controlled double-blind study to evaluate the effects of high doses of vitamin C, vitamin E, beta-carotene, and zinc on the progression of age-related macular degeneration and visual acuity.⁷⁰

The study divided patients into four categories of macular degeneration:

- Category 1—a total drusen area < 63 μm and visual acuity $\geq 20/32$ in both eyes
- Category 2 (mild macular degeneration)—multiple small drusen, single or nonextensive intermediate drusen (63–124 μm), pigment abnormalities, or a combination of these in one or both eyes, and visual acuity $\geq 20/32$ in both eyes
- Category 3 (intermediate macular degeneration)—no evidence of advanced disease (ie, atrophy involving the center of the macula or features of choroidal neovascularization) in both eyes and at least one eye with visual acuity $\geq 20/32$, with at least one large drusen (125 μm), extensive intermediate drusen, or geographic atrophy not involving the center of the

macula, or any combination of these

- Category 4—visual acuity $\geq 20/32$ and no advanced macular degeneration in the study eye, and the fellow eye with lesions of advanced degeneration or visual acuity < 20/32 likely due to macular degeneration.⁷⁰

Patients ages 55 to 59 required category 3 or 4 lesions to qualify for the study.⁷⁰

The treatment groups received antioxidants (vitamin C 500 mg, vitamin E 400 IU, and beta carotene 15 mg), or zinc 80 mg with copper 2 mg, or antioxidants with zinc. The control group received placebo. Outcomes were progression to or treatment of advanced macular degeneration and moderate visual loss. The study enrolled 3,640 patients and followed them for an average of 6.3 years.⁷⁰

Results. The risk of developing advanced macular degeneration was lower in patients taking antioxidants plus zinc than in those taking placebo (odds ratio 0.72, 99% confidence interval 0.52–0.98). Those taking antioxidants alone also had a lower risk (odds ratio 0.75, 99% confidence interval 0.55–1.03), as did patients taking zinc alone (odds ratio 0.80, 99% confidence interval 0.59–1.09).⁷⁰

For moderate visual loss, only the antioxidant plus zinc therapy resulted in a reduction of risk (odds ratio 0.73, 99% confidence interval 0.54–0.99). In patients in category 3 or 4, the risk of developing advanced macular degeneration was 20% with antioxidants plus zinc vs 28% with placebo; the probability of a 15-letter decline in visual acuity was 23% vs 29%.⁷⁰

Benefits were seen for patients with dry and wet macular degeneration. Patients who smoked were taken off the beta-carotene formulation because of a risk of malignancy. The authors recommended that patients over age 55 who met study criteria should take antioxidants plus zinc daily, minus the beta-carotene if they smoked.⁷⁰

Our recommendations

We recommend that, in accordance with the results of the Age-Related Eye Disease study, patients over age 55 with evidence of macular degeneration take antioxidants (vitamin C 500 mg, vitamin E 400 IU, beta-carotene 15 mg, unless a smoker) and zinc 80 mg every day.

Patients older than 55 with macular degeneration should take antioxidants

■ THERAPIES UNDER DEVELOPMENT

We need new and better therapies to preserve vision in patients with either form of age-related macular degeneration. The goal of new therapies will be the same as that of current ones: ie, to control the adverse effects of choroidal neovascularization on the foveal photoreceptors and retinal pigment epithelium.

Some areas are especially in need of new treatments. For example, there is currently no therapy for occult choroidal neovascularization, although verteporfin was recently demonstrated to be somewhat more successful than placebo at preventing moderate visual loss.⁷¹ Similarly, no treatments exist for less than predominantly classic subfoveal choroidal neovascularization, geographic atrophy, or disciform scars.

Exciting new approaches undergoing clinical testing include intravitreally injected antiangiogenic agents, newer photodynamic agents, transpupillary thermotherapy, radiation therapy, other forms of vitamin supplementation, and gene therapy.^{72,73}

■ MONITORING PATIENTS WITH MACULAR DEGENERATION

Hypertension should be maximally controlled to keep the blood pressure within the optimal range. All patients who smoke should be encouraged to discontinue this habit, as it may lead to a poorer outcome.

For patients with dry macular degenera-


tion, semiannual visits to an ophthalmologist and daily home Amsler grid testing is sufficient to monitor the disease, usually beginning at age 50.

Patients with wet macular degeneration require closer monitoring, with the frequency based on the clinical findings, response to treatment, and the clinical judgment of the examining ophthalmologist.

Amsler grid testing

Amsler grid testing requires the patient to be situated about 14 inches from the grid and to look at the grid with each eye occluded separately, wearing their spectacle correction with “near add.” Early-stage macular degeneration may cause the patient to see a distortion near the center of the grid. If macular degeneration is advanced, the patient may note a blank spot in the center of the grid. Patients who note any distortion (TABLE 1) should be instructed to contact their ophthalmologist immediately for evaluation.

Amsler grid testing is important in patients with dry macular degeneration, because they may go on to develop choroidal neovascularization, which is potentially treatable if caught early enough.

Keep in mind that dry macular degeneration may not only affect central vision. Any change in Amsler grid status may indicate new choroidal neovascularization affecting the center of vision. Treatment may be possible. 

■ REFERENCES

- Kornzweig AL, Feldstein M, Schneider J. The eye in old age. IV. Ocular survey of over one thousand aged persons with special reference to normal and disturbed visual function. *Am J Ophthalmol* 1957; 44:29–37.
- Kahn HA, Leibowitz HM, Ganley JP, et al. The Framingham Eye Study. I. Outline and major prevalence findings. *Am J Epidemiol* 1977; 106:17–32.
- Leibowitz H, Krueger DE, Maunders LR, et al. The Framingham Eye Study monograph: an ophthalmological and epidemiological study of cataract, glaucoma, diabetic retinopathy, macular degeneration, and visual acuity in a general population of 2631 adults, 1973–1975. *Surv Ophthalmol* 1980; 24(suppl):335–610.
- Klein BE, Klein R. Cataracts and macular degeneration in older Americans. *Arch Ophthalmol* 1982; 100:571–573.
- Ferris FL III. Senile macular degeneration: review of epidemiologic features. *Am J Epidemiol* 1983; 118:132–151.
- Bressler NM, Bressler SB, West SK, Fine SL, Taylor HR. The grading and prevalence of macular degeneration in Chesapeake Bay watermen. *Arch Ophthalmol* 1989; 107:847–852.
- Klein R, Klein BEK, Linton KLP. Prevalence of age-related maculopathy: the Beaver Dam study. *Ophthalmology* 1992; 99:933–943.
- Hyman LG, Lilienfeld AM, Ferris FL III, Fine SL. Senile macular degeneration: a case control study. *Am J Epidemiol* 1983; 118:213–227.
- Klein R, Klein BEK, Jensen SC, Meuer SM. The five-year incidence and progression of age-related maculopathy: the Beaver Dam Eye study. *Ophthalmology* 1997; 104:7–121.
- Smith W, Assink J, Klein R, et al. Risk factors for age-related macular degeneration: pooled findings from three continents. *Ophthalmology* 2001; 108:697–704.
- Ferris FL III, Fine SL, Hyman L. Age-related macular degeneration and blindness due to neovascular maculopathy. *Arch Ophthalmol* 1984; 102:1640–1642.
- Goldberg J, Flowerdew G, Smith E, Brody JA, Tso MOM. Factors associated with age-related macular degeneration: an analysis of data from the first national health and nutrition examination survey. *Am J Epidemiol* 1984; 128:700–710.
- The Eye Disease Case-Control Study Group. Risk factors for neovascular age-related macular degeneration. *Arch Ophthalmol* 1992; 110:1701–1708.
- Kahn HA, Leibowitz HM, Ganley JP, et al. The Framingham Eye Study. II. Association of ophthalmic pathology with single variables previously measured in the Framingham Heart Study. *Am J Epidemiol* 1977;



- 106:33–41.
15. **Cruickshanks KJ, Klein R, Klein BEK, Nondahl DM.** Sunlight and the 5-year incidence of early age-related maculopathy. *Arch Ophthalmol* 2001; 119:246–250.
 16. **Bressler NM, Bressler SB, Fine SL.** Neovascular (exudative) age-related macular degeneration. In: Ryan SJ, Schachat AP, editors. *Retina*, 3rd ed. St. Louis: Mosby, 2001:1100–1135.
 17. **Macular Photocoagulation Study Group.** Subfoveal neovascular lesions in age-related macular degeneration. Guidelines for evaluation and treatment in the macular photocoagulation study. *Arch Ophthalmol* 1991; 109:1242–1257.
 18. **Macular Photocoagulation Study Group.** Argon laser photocoagulation for senile macular degeneration. Results of a randomized clinical trial. *Arch Ophthalmol* 1982; 100:912–918.
 19. **Macular Photocoagulation Study Group.** Argon laser photocoagulation for neovascular maculopathy: three-year results from randomized clinical trials. *Arch Ophthalmol* 1986; 104:694–701.
 20. **Macular Photocoagulation Study Group.** Argon laser photocoagulation for neovascular maculopathy. five-year results from randomized clinical trials. *Arch Ophthalmol* 1991; 109:1109–1114.
 21. **Macular Photocoagulation Study Group.** Krypton laser photocoagulation for neovascular lesions of age-related macular degeneration. results of a randomized clinical trial. *Arch Ophthalmol* 1990; 108:816–824.
 22. **Macular Photocoagulation Study Group.** Persistent and recurrent neovascularization after krypton laser photocoagulation for neovascular lesions of age-related macular degeneration. *Arch Ophthalmol* 1990; 108:825–831.
 23. **Macular Photocoagulation Study Group.** Laser photocoagulation for juxtafoveal choroidal neovascularization: Five-year results from randomized clinical trials. *Arch Ophthalmol* 1994; 112:500–509.
 24. **Macular Photocoagulation Study Group.** Laser photocoagulation of subfoveal neovascular lesions in age-related macular degeneration: results of a randomized clinical trial. *Arch Ophthalmol* 1991; 109:1220–1231.
 25. **Macular Photocoagulation Study Group.** Laser photocoagulation of subfoveal neovascular lesions of age-related macular degeneration: updated findings from two clinical trials. *Arch Ophthalmol* 1993; 111:1200–1209.
 26. **Macular Photocoagulation Study Group.** Laser photocoagulation of subfoveal recurrent neovascular lesions in age-related macular degeneration. Results of a randomized clinical trial. *Arch Ophthalmol* 1991; 109:1232–1241.
 27. **Macular Photocoagulation Study Group.** Subfoveal neovascular lesions in age-related macular degeneration: guidelines for evaluation and treatment in the Macular Photocoagulation Study. *Arch Ophthalmol* 1991; 109:1220–1231.
 28. **Macular Photocoagulation Study Group.** Persistent and recurrent neovascularization after laser photocoagulation for subfoveal choroidal neovascularization of age-related macular degeneration. *Arch Ophthalmol* 1994; 112:489–499.
 29. **Macular Photocoagulation Study Group.** Visual outcome after laser photocoagulation for subfoveal choroidal neovascularization secondary to age-related macular degeneration: the influence of initial lesion size and initial visual acuity. *Arch Ophthalmol* 1994; 109:480–488.
 30. **Schmidt-Erfurth U, Hasan T.** Mechanisms of action of photodynamic therapy with verteporfin for the treatment of age-related macular degeneration. *Surv Ophthalmol* 2000; 45:195–214.
 31. **Miller JW, Walsh AW, Kramer M, et al.** Photodynamic therapy of experimental choroidal neovascularization using lipoprotein-delivered benzoporphyrin. *Arch Ophthalmol* 1995; 113:810–818.
 32. **Kramer M, Miller JW, Michaud N, et al.** Liposomal benzoporphyrin derivative verteporfin photodynamic therapy. Selective treatment of choroidal neovascularization in monkeys. *Ophthalmology* 1996; 103:427–438.
 33. **Husain D, Miller JW, Michaud N, Connolly E, Flotte TJ, Gragoudas ES.** Intravenous infusion of liposomal benzoporphyrin derivative for photodynamic therapy of experimental choroidal neovascularization. *Arch Ophthalmol* 1996; 114:978–985.
 34. **Husain D, Kramer M, Kenny AG, et al.** Effects of photodynamic therapy using verteporfin on experimental choroidal neovascularization and normal retina and choroid up to 7 weeks after treatment. *Invest Ophthalmol Vis Sci* 1999; 40:2322–2331.
 35. **Reinke MH, Canakis C, Husain D, et al.** Verteporfin photodynamic therapy retreatment of normal retina and choroid in the cynomolgus monkey. *Ophthalmology* 1999; 106:1915–1923.
 36. **Miller JW, Schmidt-Erfurth U, Sickenberg M, et al.** Photodynamic therapy with verteporfin for choroidal neovascularization caused by age-related macular degeneration: results of a single treatment in a phase 1 and 2 study. *Arch Ophthalmol* 1999; 117:1161–1173.
 37. **Schmidt-Erfurth U, Miller JW, Sickenberg M, et al.** Photodynamic therapy with verteporfin for choroidal neovascularization caused by age-related macular degeneration: results of retreatments in a phase 1 and 2 study. *Arch Ophthalmol* 1999; 117:1177–1187.
 38. **Treatment of Age-related Macular Degeneration with Photodynamic Therapy (TAP) Study Group.** Photodynamic therapy of subfoveal choroidal neovascularization in age-related macular degeneration with verteporfin: one-year results of 2 randomized clinical trials—TAP Report 1. *Arch Ophthalmol* 1999; 117:1329–1345.
 39. **Treatment of Age-related Macular Degeneration with Photodynamic Therapy (TAP) Study Group.** Photodynamic therapy of subfoveal choroidal neovascularization in age-related macular degeneration with verteporfin. Two year results of 2 randomized clinical trials—TAP Report 2. *Arch Ophthalmol* 2001; 119:198–207.
 40. **Sickenberg M, Schmidt-Erfurth U, Miller JW, et al.** A preliminary study of photodynamic therapy using verteporfin for choroidal neovascularization in pathologic myopia, ocular histoplasmosis syndrome, angioid streaks, and idiopathic causes. *Arch Ophthalmol* 2000; 118:327–336.
 41. **Eong KGA, Pieramici DJ, Fujii GY, et al.** Macular translocation: unifying concepts, terminology, and classification. *Am J Ophthalmol* 2001; 131:244–253.
 42. **Ninomiya Y, Lewis JM, Hasegawa T, Tano Y.** Retinotomy and foveal translocation for surgical management of subfoveal choroidal neovascular membranes. *Am J Ophthalmol* 1996; 122:613–621.
 43. **Imai K, Loewenstein A, de Juan E Jr.** Translocation of the retina for management of subfoveal choroidal neovascularization I: Experimental studies in the rabbit eye. *Am J Ophthalmol* 1998; 125:627–634.
 44. **de Juan E Jr, Loewenstein A, Bressler NM, Alexander J.** Translocation of the retina for management of subfoveal choroidal neovascularization II: A preliminary report in humans. *Am J Ophthalmol* 1998; 125:635–646.
 45. **Fujikado T, Ohji M, Saito Y, Hayashi A, Tano Y.** Visual function after foveal translocation with scleral shortening in patients with myopic neovascular maculopathy. *Am J Ophthalmol* 1998; 125:647–656.
 46. **Fujikado T, Ohji M, Hayashi A, Kusaka S, Tano Y.** Anatomic and functional recovery of the fovea after foveal translocation surgery without large retinotomy and simultaneous excision of a neovascular membrane. *Am J Ophthalmol* 1998; 126:839–842.
 47. **Akduman L, Karavellas MP, MacDonald JC, Olk RJ, Freeman WR.** Macular translocation with retinotomy and retinal rotation for exudative age-related macular degeneration. *Retina* 1999; 19:418–423.
 48. **Lewis H, Kaiser PK, Lewis S, Estafanous M.** Macular translocation for subfoveal choroidal neovascularization in age-related macular degeneration: A prospective study. *Am J Ophthalmol* 1999; 128:135–146.
 49. **de Juan E JR, Vander JF.** Effective macular translocation without scleral imbrication. *Am J Ophthalmol* 1999; 128:380–382.
 50. **Lin SB, Glaser BM, Gould DM, Baudo TA, Lakhnpal RR, Murphy RP.** Scleral unfolding for macular translocation. *Am J Ophthalmol* 2000; 130:76–81.
 51. **Pieramici DJ, de Juan E Jr, Fujii GY, et al.** Limited inferior macular translocation for the treatment of subfoveal choroidal neovascularization secondary to age-related macular degeneration. *Am J Ophthalmol* 2000; 130:419–428.
 52. **Fujii GY, Pieramici DJ, Humayun MS, et al.** Complications associated with limited macular translocation. *Am J Ophthalmol* 2000; 130:751–762.



53. **Glacet-Bernard A, Simon P, Hamelin N, Coscas G, Soubrane G.** Translocation of the macula for management of subfoveal choroidal neovascularization: Comparison of results in age-related macular degeneration and degenerative myopia. *Am J Ophthalmol* 2001; 131:78-89.

54. **Fujii GY, Humayun MS, Pieramici DJ, Schachat AP, Eong KGA, de Juan E Jr.** Initial experience of inferior limited macular translocation for subfoveal choroidal neovascularization resulting from causes other than age-related macular degeneration. *Am J Ophthalmol* 2001; 131:90-100.

55. **Fujikado T, Ohji M, Kusaka S, et al.** Visual function after foveal translocation with 360-degree retinotomy and simultaneous torsional muscle surgery in patients with myopic neovascular maculopathy. *Am J Ophthalmol* 2001; 131:101-110.

56. **Lewis H.** Macular translocation with chorioscleral unfolding: A pilot clinical study. *Am J Ophthalmol* 2001; 132:156-163.

57. **American Academy of Ophthalmology.** Macular translocation. *Ophthalmology* 2000; 107:1015-1018.

58. **Thomas MA, Kaplan HJ.** Surgical removal of subfoveal neovascularization in the presumed ocular histoplasmosis syndrome. *Am J Ophthalmol* 1991; 111:1-7.

59. **Thomas MA, Grand MG, Williams DF, Lee CM, Pesin SR, Lowe MA.** Surgical management of subfoveal choroidal neovascularization. *Ophthalmology* 1992; 99:952-968.

60. **Berger AS, Kaplan HJ.** Clinical experience with the surgical removal of subfoveal neovascular membranes. Short-term postoperative results. *Ophthalmology* 1992; 99:969-976.

61. **Thomas MA, Dickinson JD, Melberg NS, Ibanez HE, Dhaliwal RS.** Visual results after surgical removal of subfoveal choroidal neovascular membranes. *Ophthalmology* 1994; 101:1384-1396.

62. **Gass JDM.** Biomicroscopic and histopathologic considerations regarding the feasibility of surgical excision of subfoveal neovascular membranes. *Am J Ophthalmol* 1994; 118:285-298.

63. **Berger AS, Conway M, Del Priore LV, Walker RS, Pollack JS, Kaplan HJ.** Submacular surgery for subfoveal choroidal neovascular membranes in patients with presumed ocular histoplasmosis. *Arch Ophthalmol* 1997; 115:991-996.

64. **Lewis H, Vanderbrug Medendrop S.** Tissue plasminogen activator-assisted surgical excision of subfoveal choroidal neovascularization in age-related macular degeneration. A randomized, double-masked trial. *Ophthalmology* 1997; 104:1847-1852.

65. **Bressler NM.** Submacular surgery: are randomized trials necessary? *Arch Ophthalmol* 1995; 113:1557-1560.

66. **Lewis H.** Subfoveal choroidal neovascularization: is there a role for submacular surgery. *Am J Ophthalmol* 1998; 126:127-129.

67. **Sternberg P Jr, Capone A Jr.** Submacular surgery: A millennium update. *Arch Ophthalmol* 2000; 118:1428-1430.

68. **Submacular Surgery Trials Pilot Study Investigators.** Submacular Surgery Trials randomized pilot trial of laser photocoagulation versus surgery for recurrent choroidal neovascularization secondary to age-related macular degeneration: I. Ophthalmic outcomes. *Submacular Surgery Trials Pilot Study Report Number 1. Am J Ophthalmol* 2000; 130:387-407.

69. **Submacular Surgery Trials Pilot Study Investigators.** Submacular Surgery Trials randomized pilot trial of laser photocoagulation versus surgery for recurrent choroidal neovascularization secondary to age-related macular degeneration: II. Quality of life outcomes. *Submacular Surgery Trials Pilot Study Report Number 2. Am J Ophthalmol* 2000; 130:408-418.

70. A randomized, placebo-controlled, clinical trial of high-dose supplementation with vitamins C and E, beta carotene, and zinc for age-related macular degeneration and vision loss: AREDS report no. 8. *Arch Ophthalmol* 2001; 119:1417-36.

71. **Verteporfin in Photodynamic Therapy (VIP) Study Group.** Verteporfin therapy of subfoveal choroidal neovascularization in age related macular degeneration: 2 year results of a randomized clinical trial including lesions with occult with no classic choroidal neovascularization: VIP Report 2. *Am J Ophthalmol* 2001; 131:541-560.

72. **Aiello LP.** Vascular endothelial growth factor and the eye. Past, present, and future. *Arch Ophthalmol* 1996; 114:1252-1254.

73. **Aiello LP.** Vascular endothelial growth factor. 20th-century mechanisms, 21st-century therapies. *Invest Ophthalmol Vis Sci* 1997; 38:1647-1652.

ADDRESS: Hilel Lewis, MD, Cole Eye Institute, The Cleveland Clinic Foundation, 130, 9500 Euclid Avenue, Cleveland, OH 44195; e-mail lewish@ccf.org.



BRIEF ANSWERS
TO SPECIFIC
CLINICAL QUESTIONS

What questions do you want answered?

We want to know what questions you want addressed in "1-Minute Consult."
All questions should be on practical, clinical topics. You may submit questions by mail, phone, fax, or e-mail.

PLEASE PRINT CLEARLY

Q: _____

NAME _____

ADDRESS _____

CITY _____

STATE _____ ZIP _____

PHONE _____ EMAIL _____

Cleveland Clinic Journal of Medicine, 9500 Euclid Ave., NA32, Cleveland, OH 44195
PHONE 216•444•2661 FAX 216•444•9385 E-MAIL ccjm@ccf.org