

**DEEPA KABIRDAS, MD**Department of Internal Medicine,  
Cleveland Clinic Florida, Weston, FL**AARTI KANWAR, MD**Department of Internal Medicine,  
Cleveland Clinic Florida, Weston, FL**BIANCA AFONSO, MD**Department of Internal Medicine,  
Cleveland Clinic Florida, Weston, FL**MARIANA BERHO, MD**Chairman, Department of Pathology,  
Cleveland Clinic Florida, Weston, FL**HERNAN AVELLA, MD**Department of Internal Medicine,  
Cleveland Clinic Florida, Weston, FL**EDUARDO OLIVEIRA, MD**Chairman, Division of Medicine; Medical  
Director, Intensive Care Unit; Departments  
of Pulmonary and Critical Care Medicine,  
Cleveland Clinic Florida, Weston, FL

# An elderly woman with asthma, eosinophilia, and septic shock

**A** 76-YEAR-OLD WOMAN is admitted with nausea and vomiting of 1 week's duration. She was diagnosed with severe asthma 6 years ago and has been hospitalized for it multiple times, most recently 1 week ago. That hospitalization was complicated by respiratory failure which required intubation and high-dose intravenous corticosteroids. Since then, she has been taking prednisone daily but her asthma remains poorly controlled and she has been using her albuterol inhaler every day as rescue therapy. She has not traveled recently or had contact with anyone who is sick. She was born in Cuba and moved to Florida 20 years ago.

On physical examination she is afebrile and her vital signs are normal. Lung examination reveals bilateral coarse breath sounds with a prolonged expiratory phase. She has mild epigastric tenderness, but no rigidity or guarding. The remainder of the physical examination is unremarkable.

Her white blood cell count is high, with 17.5% eosinophils (normal 0–4) and an absolute eosinophil count of  $2.905 \times 10^9/L$  (normal 0–0.4). A chest radiograph shows bilateral diffuse chronic interstitial changes.

## DIFFERENTIAL DIAGNOSIS

**1** Which of the following conditions is associated with asthma and eosinophilia?

- Atopic asthma
- Churg-Strauss syndrome
- Allergic bronchopulmonary aspergillosis
- Parasitic infestation
- Eosinophilic pneumonia
- Bronchocentric granulomatosis

All of these conditions can cause asthma and eosinophilia.

### Atopic asthma

“Extrinsic asthma,” “allergic asthma,” and “atopic asthma” are terms that can be used interchangeably. They refer to the onset of wheezing, cough, and shortness of breath upon contact with an allergen. Several outdoor and indoor allergens have been known to trigger the cascade of events leading to asthma symptoms. Outdoor allergens include pollen and grass; indoor allergens include house dust mites, animal proteins (particularly cat and dog allergens), cockroaches, and fungi. Based on exposure, symptoms may be seasonal or perennial. The reaction is immunologic and is mediated by immunoglobulin E (IgE).

Atopy is assessed by three methods: skin test reactivity, serum IgE levels, and blood eosinophilia.<sup>1</sup> Allergy skin testing commonly involves skin prick tests using a panel of several different allergens. Blood radioallergosorbent tests (RASTs) involve blood measurement of the minute quantities of IgE antibody specifically directed at a particular antigen.<sup>2</sup> Serum IgE levels appear to be closely linked with both asthma and airway hyperresponsiveness whether or not asthma is present.<sup>3</sup> An elevated blood eosinophil count may indicate a tendency to atopy; however, marked elevation ( $> 3.0 \times 10^9/L$ ) should prompt consideration of alternative diagnoses.<sup>4</sup>

### Churg-Strauss syndrome

Churg-Strauss syndrome, or allergic granulomatous angiitis, is a rare syndrome that affects small and medium-sized arteries and veins. It is a multisystem disorder characterized by allergic

**Her asthma is poorly controlled despite prednisone therapy, and her eosinophil count is high**

rhinitis, asthma, and prominent peripheral blood eosinophilia. Although the exact cause of Churg-Strauss syndrome is unknown, it is most likely autoimmune. Its clinical elements occur in three sequential phases: prodromal, eosinophilic, and vasculitic.

Other manifestations include palpable purpura, eosinophilic gastroenteritis, mononeuritis multiplex, and cardiac and renal involvement. Eosinophilia is occasionally missed because of rapid, spontaneous, or steroid-induced reductions or fluctuations in eosinophil counts. Approximately 38% to 59% of patients test positive for antineutrophil cytoplasmic antibody (ANCA).<sup>5</sup> Lung biopsy is the gold standard for diagnosis.<sup>6</sup>

High-dose corticosteroid treatment for 6 to 12 weeks is usually effective. Cyclophosphamide (Cytoxan), azathioprine (Azasan), and immune globulin have also been used. Responsiveness to treatment can be monitored by following the eosinophil count and sedimentation rate. Persistence of ANCA positivity does not adequately reflect disease activity.<sup>7</sup>

#### Allergic bronchopulmonary aspergillosis

Allergic bronchopulmonary aspergillosis is a hypersensitivity response to the fungus *Aspergillus fumigatus* that occurs in patients with asthma. Some of the diagnostic features are a history of asthma, immediate skin test reactivity to *Aspergillus* antigens, precipitating serum antibodies to *A fumigatus*, serum total IgE concentration greater than 1,000 ng/mL, and peripheral blood eosinophilia ( $> 0.5 \times 10^9/L$ ). Central bronchiectasis and lung infiltrates on chest radiography are other characteristic features. Repeated episodes can lead to progressive pulmonary fibrosis, especially in the upper lung fields.

Corticosteroids are very effective for controlling this disease, and the clinical response should be monitored with serial monthly or bimonthly measurement of the serum total IgE concentration. Itraconazole (Sporanox) can be considered for poor responsiveness to corticosteroids, relapsing disease, and corticosteroid-dependent disease, and in cases of corticosteroid toxicity.<sup>8</sup>

#### Parasitic infestation

*Ascaris lumbricoides*, hookworms, *Strongyloides*

*stercoralis*, and *Toxocara canis* have life cycles in which infecting larvae reach the lungs via the bloodstream and penetrate into alveoli to cause Löffler syndrome,<sup>9</sup> characterized by cough, wheezing, peripheral blood eosinophilia, and chest radiographic infiltrates.

Anthelmintic therapy is the mainstay of management. In ascari pneumonia, if symptoms are severe, systemic corticosteroids will diminish both the symptoms and the eosinophilia.<sup>10</sup> Although rarely necessary, corticosteroids may ameliorate the pulmonary manifestations of hookworm infestation and toxocariasis. In contrast, patients with chronic strongyloidiasis may develop asthma that paradoxically worsens with corticosteroid use.<sup>11,12</sup>

Several organisms, such as *Paragonimus* lung flukes and cestodes, can directly invade the pulmonary parenchyma, causing echinococcosis and, less commonly, cysticercosis and producing pulmonary manifestations with eosinophilia.

Tropical pulmonary eosinophilia is a form of eosinophilic pneumonia due to a distinct immune response to blood-borne microfilarial stages of the lymphatic filariae *Wuchereria bancrofti* and, less commonly, *Brugia malayi*.

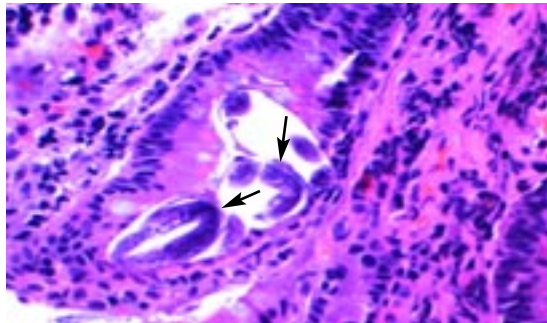
#### Eosinophilic pneumonia

“Eosinophilic pneumonia” is a heterogenous group of lung diseases characterized by pulmonary eosinophilia and infiltrates, with or without increased peripheral eosinophils in the blood. Primary or idiopathic eosinophilic pneumonia includes acute eosinophilic pneumonia and chronic eosinophilic pneumonia.

The finding on chest radiography of “photographic negative” pulmonary edema is pathognomonic of chronic eosinophilic pneumonia. Bronchoalveolar lavage specimens with eosinophilia of greater than 40% associated with peripheral eosinophilia suggest this diagnosis.

Systemic steroids are the mainstay of treatment, with dramatic response occurring within 2 days. Chronic eosinophilic pneumonia rarely resolves spontaneously. Patients continue to be steroid-responsive and respond to corticosteroid doses at levels similar to those prior to the relapse. As a result, the outcome for most patients is excellent despite frequent recurrences and the occasional need for prolonged therapy.

**Very high eosinophil counts raise the suspicion of a diagnosis other than atopic asthma**



**FIGURE 1.** *Strongyloides* larvae in the duodenal crypts (hematoxylin and eosin stain, × 4,000).

### Bronchocentric granulomatosis

Bronchocentric granulomatosis is an uncommon pathologic entity characterized by necrotizing granulomatous inflammation of bronchi.<sup>13</sup> There are two distinct groups of patients.

About one-half of patients with bronchocentric granulomatosis also have allergic bronchopulmonary aspergillosis,<sup>14</sup> and hence have asthma and eosinophilia. In this group, bronchocentric granulomatosis is a result of a complex tissue response to airway colonization by fungal organisms. Tissue and peripheral eosinophilia with hypersensitivity to *Aspergillus* can be demonstrated. The diagnosis is made by surgical lung biopsy. Corticosteroids may be used in these patients.

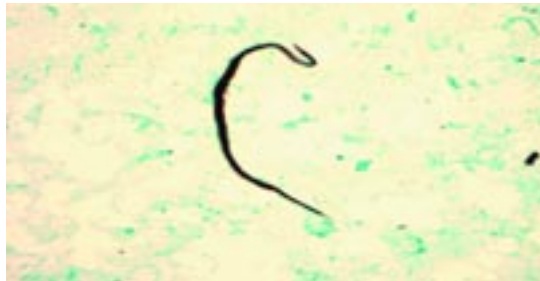The second heterogeneous group of patients with bronchocentric granulomatosis do not have asthma, and the pathogenesis of their granulomatous inflammation is unknown.<sup>15</sup> Peripheral eosinophilia is uncommon in these patients, and they lack evidence of fungal hypersensitivity. No specific therapy is recommended, and many patients recover without treatment.<sup>14</sup>

Infectious causes such as histoplasmosis, blastomycosis, and mycobacterial infections should be excluded as they can cause granulomatous inflammation in the bronchioles mimicking bronchocentric granulomatosis.

### ■ CASE CONTINUED

Although our patient has steroid-resistant asthma, her principal complaint is nausea and vomiting. The initial impression of her disorder is of steroid-induced peptic ulcer.

Upper gastrointestinal endoscopy is performed to evaluate her persistent nausea and



**FIGURE 2.** *Strongyloides* larvae in blood (Giemsa stain, oil immersion).

vomiting; it shows diffuse ulceration in the entire duodenum, with linear ulcers and plaques in the esophagus. She is started on an intravenous proton pump inhibitor. Her asthma is treated with nebulized albuterol and systemic steroids.

Her hospital course is complicated by hypotension and worsening leukocytosis with eosinophilia as high as 35%. She is transferred to the intensive care unit and started on broad-spectrum empirical antibiotics, intravenous steroids, and aggressive fluid resuscitation for sepsis. Duodenal biopsy shows *Strongyloides* larvae within the duodenal crypts (FIGURE 1). Blood cultures are positive for *Klebsiella pneumoniae*, and a parasite consistent with *Strongyloides* (FIGURE 2) is identified.

### ■ DIAGNOSTIC TESTS

**2** Which of the following tests is most sensitive for diagnosing strongyloidiasis?

- Stool ova, parasite
- Serologic tests
- Bronchoalveolar lavage
- Skin testing for immediate hypersensitivity

**Serologic tests** are the most sensitive for the diagnosis of strongyloidiasis. Common serologic tests used in diagnosing strongyloidiasis include the enzyme immunoassay and enzyme-linked immunosorbent assay (ELISA). (Our patient is tested: her serum IgE level is high and her ELISA for *Strongyloides* IgG antibody is positive.) In a study conducted in an endemic region of Thailand, a GPAT (gelatin particle agglutination test) was found to be more practical for screening for strongyloidiasis than the conventional ELISA.<sup>16</sup>

**On chest radiography, chronic eosinophilic pneumonia is the “photographic negative” of pulmonary edema**

Although serologic analysis is the most sensitive test for strongyloidiasis (sensitivity 84% to 92%), it is not specific, and cross-reactions with other nematode infections are possible. However, ELISA can be falsely negative in immunocompromised patients, and anti-strongyloides antibody may persist for several years after treatment.<sup>17</sup> Schaffel et al<sup>18</sup> found that the sensitivity of ELISA for diagnosing strongyloidiasis in immunocompromised patients was 68% and the specificity was 89%.

**Stool tests.** About a quarter of infected patients have negative stool examinations, and ova are almost never observed unless severe diarrhea occurs.<sup>19</sup> Performing multiple stool examinations and specialized tests on stool specimens, including the Baermann concentration technique, concentration with zinc sulfate, and a modified agar plate method, can increase the yield.<sup>20</sup> Aspiration of duodenojejunal fluid or the use of a string test (Enterotest) may improve the likelihood of larval recovery.

**Bronchoalveolar lavage** may reveal the filariform larvae in disseminated strongyloidiasis. There are also case reports in which diagnosis was made by sputum Gram stain.<sup>21,22</sup>

**Skin testing** for immediate hypersensitivity with parasite extracts has been tried experimentally, but this is not widely available, as sterility cannot be guaranteed.<sup>23</sup>

Eosinophilia of 10% to 40% is common during acute infection; it may be as high as 75% to 80%. However, it may be normal in disseminated strongyloidiasis due to coexisting bacterial infection. In chronic infection it is usually intermittent.

#### ■ ROLE OF CORTICOSTEROIDS

**3** In which of the following conditions that cause asthma and eosinophilia are corticosteroids detrimental?

- Allergic bronchopulmonary aspergillosis
- Churg-Strauss syndrome
- Strongyloidiasis
- Ascaris pneumonia
- Hypereosinophilic syndromes

Except strongyloidiasis, most of the other causes of pulmonary eosinophilia improve with corticosteroid therapy. Giving cortico-

steroids to patients with strongyloidiasis can lead to a fatal condition termed “disseminated strongyloidiasis” or “hyperinfection syndrome.” Our patient received high-dose intravenous corticosteroids 1 week earlier, which precipitated the disseminated infection. This therapy was started again during this hospitalization for sepsis and asthma, but it was stopped once disseminated strongyloidiasis was suspected.

Asthma that responds poorly to corticosteroids or that is paradoxically aggravated by them should raise the suspicion of strongyloidiasis, especially in patients from endemic areas and immigrants from developing countries.<sup>24</sup>

Several case reports show that disseminated strongyloidiasis is often accompanied by gram-negative sepsis, as seen in our patient who had *Klebsiella* bacteremia.<sup>25</sup> Enteric flora gain access to extraintestinal sites by bacterial translocation through ulcers induced by the filariform larvae or by being carried on the outer surface of the worm or in the intestinal tract of the larvae themselves.<sup>26</sup>

Disseminated strongyloidiasis has a high case-fatality rate that is increased by concomitant immunosuppression, bacteremia, and delayed diagnosis.<sup>27</sup>

#### ■ LIFE CYCLE OF STRONGYLOIDES

Strongyloidiasis is uncommon, although endemic foci occur in rural areas of the southeastern United States and in tropical and subtropical countries such as those of West Africa, the Caribbean, and Southeast Asia. Populations with higher prevalence rates include patients in long-term institutionalized care and immigrants from developing countries. Strongyloidiasis affects all age groups and has no predilection for either sex.

The infection is acquired when infective (filariform) larvae penetrate the skin during contact with contaminated soil and are then carried by the venous circulation to the lungs, causing asthma-like symptoms.<sup>24</sup> From the lungs, they enter the alveoli, go up the tracheobronchial tree and larynx, are subsequently swallowed, and reach the gastrointestinal tract. Our patient had symptoms of intestinal strongyloidiasis as demonstrated by

**Giving steroids to patients with uncomplicated strongyloidiasis may lead to disseminated strongyloidiasis and sepsis**



the larval form in the duodenal biopsy. In the gut, larvae molt twice and become parasitic adult female worms that produce eggs, yielding noninfective (rhabditiform) larvae. These larvae either can be passed out of the host's body in the feces or, under certain conditions, can cause autoinfection.

### ■ CLINICAL FEATURES OF STRONGYLOIDIASIS

A distinctive characteristic of *S stercoralis* is its ability to persist and replicate within a host for decades while producing minimal or no symptoms. This was seen in our patient, who migrated from an endemic area and remained asymptomatic for a long period of time.<sup>28</sup>

Clinical features range from asymptomatic eosinophilia in an immunocompetent host to hyperinfection syndrome with septic shock in an immunocompromised individual like our patient.

The cutaneous manifestation includes a distinctive eruption termed “larva currens” (“running” larva), which is a serpiginous wheal that rapidly progresses at a rate of 5 to 10 cm per hour and is pathognomonic of *Strongyloides* infection. The feet are the most commonly affected site.

Patients may experience anorexia, nausea, vomiting, and epigastric pain due to duodenitis. Chronic enterocolitis and malabsorption occur due to heavy worm burden. Our patient experienced the above-mentioned symptoms due to intestinal strongyloidiasis.

Pulmonary manifestations occur in both acute and chronic strongyloidiasis. Transpulmonary migration of the larval forms in the acute stage can produce dry cough, dyspnea, wheezing, and hemoptysis. Patients with chronic strongyloidiasis may develop asthma, which paradoxically worsens with corticosteroid use,<sup>11,12</sup> or dyspnea due to restrictive pulmonary disease.<sup>29</sup> Our patient had new-onset asthma that was poorly controlled with steroids.

Hyperinfection syndrome, or disseminated strongyloidiasis, is generally associated with conditions of depressed host cellular immunity, such as acquired immunodeficiency syndrome, and with immunosuppres-

**TABLE 1**

### Risk factors for disseminated strongyloidiasis

- Alcoholism
- Corticosteroids
- Diabetes mellitus
- Hemopoietic stem cell transplantation
- Human immunodeficiency virus infection, acquired immunodeficiency syndrome
- Human T-cell leukemia virus type 1 infection
- Hypogammaglobulinemia
- Immunosuppressive therapy (chemotherapeutic agents, anti-tumor necrosis factor receptor therapy)
- Malignancy (lymphoma, leukemia)
- Organ transplant recipients
- Malnutrition

sive therapy.<sup>30,31</sup> **TABLE 1** presents some of the risk factors for disseminated strongyloidiasis. The massive dissemination of filariform larvae to the lungs, liver, heart, central nervous system, and endocrine glands induces inflammation that may result in symptomatic dysfunction of these organs and even septic shock.<sup>26,32,33</sup> Our patient received high-dose intravenous steroids, which precipitated the disseminated infection and septic shock.

### ■ TREATMENT OF STRONGYLOIDIASIS

**4** Which is the most appropriate treatment for this patient?

- Thiabendazole (Mintezol) 25 mg/kg orally twice daily for 2 days
- Ivermectin (Stromectol) 200 µg/kg orally for 5 to 7 days
- Albendazole (Albenza) 400 mg orally twice daily for 2 days
- Mebendazole (Vermox) 10 mg/kg orally daily for 5 days

In immunocompromised patients with disseminated disease, such as our patient, there is

***S stercoralis* can persist and replicate in a host for decades but cause minimal or no symptoms**

no general agreement about which regimen is most appropriate. Oral ivermectin 200 µg/kg for 5 to 7 days, or a combination of ivermectin and albendazole until the patient responds, is currently used (TABLE 2). Thiabendazole (25 mg/kg orally twice a day, maximum of 3.0 g/day) for 5 to 7 days was previously recommended for disseminated disease. Our patient received thiabendazole for 7 days, which was the drug of choice when she was treated.

Alternative therapies that have been successful in patients with disseminated strongyloidiasis who are unable to receive oral therapy include subcutaneous ivermectin,<sup>34</sup> per rectum ivermectin administration,<sup>35</sup> and a parenteral veterinary formulation of ivermectin.<sup>36</sup>

### Uncomplicated strongyloidiasis

Currently, the treatment of choice for uncomplicated strongyloidiasis is ivermectin 200 µg/kg in a single dose or in two doses given 2 weeks apart.<sup>37,38</sup>

Albendazole (400 mg orally twice daily for 2 to 3 days) also has activity against *Strongyloides*, although clinical experience is limited.<sup>39</sup> Thiabendazole use has declined due to the availability of more efficacious and better-tolerated medications. Mebendazole is far less effective than thiabendazole.<sup>40</sup>

The efficacy of therapy can be documented by follow-up stool examinations in 2 weeks and complete blood counts, serum IgE levels,<sup>41</sup> and parasite-specific IgG levels<sup>42</sup> in 3 months. Eosinophilia persisting for several months after treatment suggests failure to eradicate *Strongyloides* or another cause of the eosinophilia.<sup>37</sup>

The prognosis of uncomplicated strongyloidiasis is generally good. Hyperinfection syndrome, however, has a high mortality rate (up to 80%) because diagnosis is often delayed and because of concomitant immunosuppression and bacteremia.<sup>27</sup>

Treatment of strongyloidiasis improves asthma-like symptoms. This patient's asthma improved considerably after appropriate antiparasitic treatment.

### ■ CASE RESOLUTION

Thiabendazole for disseminated strongyloidiasis and antibiotics for gram-negative

**TABLE 2**

### Treatment of strongyloidiasis<sup>a</sup>

#### Uncomplicated infection

Ivermectin 200 µg/kg single dose or 2 doses given 2 weeks apart orally

Alternative: albendazole 400 mg orally twice daily for 2 to 3 days

#### Disseminated strongyloidiasis or hyperinfection syndrome

Ivermectin 200 µg/kg orally for 5 days

Alternative: ivermectin combined with albendazole until response occurs

<sup>a</sup>Although proven to be effective in the treatment of strongyloidiasis, use of thiabendazole has declined due to the availability of better-tolerated and efficacious medications.

sepsis were started. Her symptoms improved and she was discharged home. On follow-up, her asthma symptoms had significantly improved and she no longer required control or rescue therapy.

### ■ TEACHING POINTS

- Asthma that responds poorly to steroids or that is paradoxically aggravated by steroids should raise the suspicion of an alternative diagnosis such as parasitic infestation, especially in patients from endemic areas and immigrants from developing countries.<sup>24,43,44</sup>
- Unexplained eosinophilia in immunosuppressed patients such as those with acquired immunodeficiency syndrome and recipients of chemotherapy should raise the suspicion of parasitic infestation.
- Giving steroids to these patients may lead to disseminated strongyloidiasis and sepsis, which has a mortality rate of up to 80%.<sup>31</sup>
- Early recognition and appropriate treatment significantly reduces the mortality rate.
- Disseminated strongyloidiasis is often accompanied by gram-negative sepsis due to a concomitant immunosuppressed state.
- Oral ivermectin is the recommended treatment for uncomplicated and disseminated strongyloidiasis. ■

**This patient's asthma improved after appropriate antiparasitic treatment**

## REFERENCES

1. Weiss ST, Speizer FE. Epidemiology and natural history. In: Weiss EB, Stein M, editors. *Bronchial Asthma: Mechanisms and Therapeutics*, 3rd ed. Boston: Little, Brown, 1993:15–25.
2. Wood RA, Phipatanakul W, Hamilton RG, Eggleston PA. A comparison of skin prick tests, intradermal skin tests, and RASTs in the diagnosis of cat allergy. *J Allergy Clin Immunol* 1999; 103:773–779.
3. Sears MR, Burrows B, Flannery EM, Herbison GP, Hewitt CJ, Holdaway MD. Relation between airway responsiveness and serum IgE in children with asthma and in apparently normal children. *N Engl J Med* 1991; 325:1067–1071.
4. Weller PF. Eosinophilia in travelers. *Med Clin North Am* 1992; 76:1413–1432.
5. Sablé-Fourtassou R, Cohen P, Mahr A, et al; French Vasculitis Study Group. Antineutrophil cytoplasmic antibodies and the Churg-Strauss syndrome. *Ann Intern Med* 2005; 143:632–638.
6. Lie JT. Illustrated histopathologic classification criteria for selected vasculitis syndromes. American College of Rheumatology Subcommittee on Classification of Vasculitis. *Arthritis Rheum* 1990; 33:1074–1087.
7. Cohen P, Guillevin L, Baril L, Lhote F, Noel LH, Lesavre P. Persistence of antineutrophil cytoplasmic antibodies (ANCA) in asymptomatic patients with systemic polyarteritis nodosa or Churg-Strauss syndrome: follow-up of 53 patients. *Clin Exp Rheumatol* 1995; 13:193–198.
8. Stevens DA, Moss RB, Kurup VP, et al; Participants in the Cystic Fibrosis Foundation Consensus Conference. Allergic bronchopulmonary aspergillosis in cystic fibrosis—state of the art: Cystic Fibrosis Foundation Consensus Conference. *Clin Infect Dis* 2003; 37(suppl 3):S225–S264.
9. Wilson ME, Weller PF. Eosinophilia. In: Guerrant RL, Walker DH, Weller PF, editors. *Tropical Infectious Diseases: Principles, Pathogens, and Practice*, 2nd ed. Philadelphia: Elsevier Churchill Livingstone, 2006:1478.
10. Gelpi AP, Mustafa A. *Ascaris* pneumonia. *Am J Med* 1968; 44:377–389.
11. Sen P, Gil C, Estrellas B, Middleton JR. Corticosteroid-induced asthma: a manifestation of limited hyperinfection syndrome due to *Strongyloides stercoralis*. *South Med J* 1995; 88: 923–927.
12. Wehner JH, Kirsch CM, Kagawa FT, Jensen WA, Campagna AC, Wilson M. The prevalence and response to therapy of *Strongyloides stercoralis* in patients with asthma from endemic areas. *Chest* 1994; 106:762–766.
13. Liebow AA. The J. Burns Amberson lecture—pulmonary angiitis and granulomatosis. *Am Rev Respir Dis* 1973; 108:1–18.
14. Koss MN, Robinson RG, Hochholzer L. Bronchocentric granulomatosis. *Hum Pathol* 1981; 12:632–638.
15. Clee MD, Lamb D, Clark RA. Bronchocentric granulomatosis: a review and thoughts on pathogenesis. *Br J Dis Chest* 1983; 77:227–234.
16. Sithithaworn J, Sithithaworn P, Janrungsopa T, Suvatanadecha K, Ando K, Haswell-Elkins MR. Comparative assessment of the gelatin particle agglutination test and an enzyme-linked immunosorbent assay for diagnosis of strongyloidiasis. *J Clin Microbiol* 2005; 43:3278–3282.
17. Carroll SM, Karthigasu KT, Grove DI. Serodiagnosis of human strongyloidiasis by an enzyme-linked immunosorbent assay. *Trans R Soc Trop Med Hyg* 1981; 75:706–709.
18. Schaffel R, Nucci M, Carvalho E, et al. The value of an immunoenzymatic test (enzyme-linked immunosorbent assay) for the diagnosis of strongyloidiasis in patients immunosuppressed by hematologic malignancies. *Am J Trop Med Hyg* 2001; 65:346–350.
19. Rosenblatt JE. Clinical importance of adequately performed stool ova and parasite examinations. *Clin Infect Dis* 2006; 42:979–980.
20. Dreyer G, Fernandes-Silva E, Alves S, Rocha A, Albuquerque R, Addiss D. Patterns of detection of *Strongyloides stercoralis* in stool specimens: implications for diagnosis and clinical trials. *J Clin Microbiol* 1996; 34:2569–2571.
21. Smith B, Verghese A, Guiterrez C, Dralle W, Berk SL. Pulmonary strongyloidiasis. Diagnosis by sputum gram stain. *Am J Med* 1985; 79:663–666.
22. Harris RA Jr, Musher DM, Fainstein V, Young EJ, Clarridge J. Disseminated strongyloidiasis: diagnosis made by sputum examination. *JAMA* 1980; 244:65–66.
23. Neva FA, Gam AA, Maxwell C, Pelletier LL. Skin test antigens for immediate hypersensitivity prepared from infective larvae of *Strongyloides stercoralis*. *Am J Trop Med Hyg* 2001; 65:567–572.
24. Nwokolo C, Imohiosen EA. Strongyloidiasis of respiratory tract presenting as ‘asthma’. *Br Med J* 1973; 2:153–154.
25. Newberry AM, Williams DN, Stauffer WM, Boulware DR, Hendel-Patterson BR, Walker PF. *Strongyloides* hyperinfection presenting as acute respiratory failure and gram-negative sepsis. *Chest* 2005; 128:3681–3684.
26. Keiser PB, Nutman TB. *Strongyloides stercoralis* in the immunocompromised population. *Clin Microbiol Rev* 2004; 17:208–217.
27. El Masry HZ, O’Donnell J. Fatal *Strongyloides* hyperinfection in heart transplantation. *J Heart Lung Transplant* 2005; 24:1980–1983.
28. Siddiqui AA, Genta RM, Berk SL. Strongyloidiasis, Chap 111. In: Guerrant RL, Walker DH, Weller PF, editors. *Tropical Infectious Diseases: Principles, Pathogens, and Practice*. Philadelphia: Elsevier Churchill Livingstone, 2006:1274.
29. Lin AL, Kessimian N, Benditt JO. Restrictive pulmonary disease due to interlobular septal fibrosis associated with disseminated infection by *Strongyloides stercoralis*. *Am J Respir Crit Care Med* 1995; 151:205–209.
30. Lessnau KD, Can S, Talavera W. Disseminated *Strongyloides stercoralis* in human immunodeficiency virus-infected patients. Treatment failure and a review of the literature. *Chest* 1993; 104:119–122.
31. Cruz T, Reboucas G, Rocha H. Fatal strongyloidiasis in patients receiving corticosteroids. *N Engl J Med* 1966; 275:1093–1096.
32. Longworth DL, Weller PF. Hyperinfection syndrome with strongyloidiasis. In: Remington JS, Swartz MN, editors. *Current Clinical Topics in Infectious Diseases*. New York: McGraw-Hill, 1986:1.
33. Woodring JH, Halfhill H II, Reed JC. Pulmonary strongyloidiasis: clinical and imaging features. *AJR Am J Roentgenol* 1994; 162:537–542.
34. Pacanowski J, Santos MD, Roux A, et al. Subcutaneous ivermectin as a safe salvage therapy in *Strongyloides stercoralis* hyperinfection syndrome: a case report. *Am J Trop Med Hyg* 2005; 73:122–124.
35. Tarr PE, Miele PS, Peregoy KS, Smith MA, Neva FA, Lucey DR. Case report: rectal administration of ivermectin to a patient with *Strongyloides* hyperinfection syndrome. *Am J Trop Med Hyg* 2003; 68:453–455.
36. Salluh JJ, Feres GA, Velasco E, Holanda GS, Toscano L, Soares M. Successful use of parenteral ivermectin in an immunosuppressed patient with disseminated strongyloidiasis and septic shock. *Intensive Care Med* 2005; 31:1292.
37. Igual-Adell R, Oltra-Alcaraz C, Soler-Company E, Sánchez-Sánchez P, Matogo-Oyana J, Rodríguez-Calabuig D. Efficacy and safety of ivermectin and thiabendazole in the treatment of strongyloidiasis. *Expert Opin Pharmacother* 2004; 5:2615–2619.
38. Zaha O, Hirata T, Kinjo F, Saito A, Fukuhara H. Efficacy of ivermectin for chronic strongyloidiasis: two single doses given 2 weeks apart. *J Infect Chemother* 2002; 8:94–98.
39. Marti H, Haji HJ, Savioli L, et al. A comparative trial of a single-dose ivermectin versus three days of albendazole for treatment of *Strongyloides stercoralis* and other soil-transmitted helminth infections in children. *Am J Trop Med Hyg* 1996; 55:477–481.
40. Beus A. [Comparative study of thiabendazole and mebendazole in *Strongyloidiasis*]. [In Croatian.] *Lijec Vjesn* 1989; 111:98–101.
41. Loutfy MR, Wilson M, Keystone JS, Kain KC. Serology and eosinophil count in the diagnosis and management of strongyloidiasis in a non-endemic area. *Am J Trop Med Hyg* 2002; 66:749–752.
42. Karunajeewa H, Kelly H, Leslie D, Leydon J, Saykao P, Biggs BA. Parasite-specific IgG response and peripheral blood eosinophil count following albendazole treatment for presumed chronic strongyloidiasis. *J Travel Med* 2006; 13:84–91.
43. Stemmermann GN. Strongyloidiasis in migrants. Pathological and clinical considerations. *Gastroenterology* 1967; 53:59–70.
44. Jantz MA, Sahn SA. Corticosteroids in acute respiratory failure. *Am J Respir Crit Care Med* 1999; 160:1079–1100.

ADDRESS: Deepa Kabirdas, MD, Cleveland Clinic Florida, 2950 Cleveland Clinic Boulevard, Weston, FL 33331; e-mail kabird@ccf.org.