

# Advances in noninvasive screening for renovascular disease

JOSEPH V. NALLY, JR, MD; JEFFREY W. OLIN, DO; GARY K. LAMMERT, MD

- **BACKGROUND** Nearly 50 million Americans have hypertension, and renovascular hypertension accounts for perhaps 1% of them.
- **PURPOSE** To review the current recommendations and the available screening tests for renovascular hypertension.
- **SUMMARY** The presence of clinical clues increases the predictive value of screening tests for renovascular hypertension; these include abrupt onset of hypertension before age 30 or after age 55, severe hypertension, accelerated or malignant hypertension, hypertension refractory to a triple-drug regimen, moderate hypertension with diffuse vascular disease, an epigastric bruit, moderate hypertension with unexplained azotemia, and azotemia induced by an angiotensin-converting enzyme inhibitor. Captopril renography and duplex ultrasonography are clinically useful screening tools, but wide variation in accuracy exists among institutions. Magnetic resonance angiography may emerge as an effective clinical test.
- **CONCLUSIONS** A thorough history and physical examination, coupled with judicious use of available screening technology, can help determine if a patient has renovascular hypertension and may benefit from intervention.

■ **INDEX TERMS:** HYPERTENSION; RENOVASCULAR; RENAL SCINTIGRAPHY; DUPLEX ULTRASONOGRAPHY; MAGNETIC RESONANCE ANGIOGRAPHY  
■ CLEVE CLIN J MED 1994; 61:328-336

From the Departments of Nephrology and Hypertension and Cardiovascular Biology (J.V.N.), Vascular Medicine (J.W.O.), and Vascular and Interventional Radiology (G.K.L.), The Cleveland Clinic Foundation.

Address reprint requests to J.V.N., Department of Nephrology and Hypertension, A101, The Cleveland Clinic Foundation, 9500 Euclid Avenue, Cleveland, OH 44195.

**H**YPERTENSION affects nearly 50 million Americans and poses a tremendous public health problem as a risk factor for cardiovascular disease. Renovascular hypertension remains the most common form of potentially correctable hypertension. Advances in renal revascularization—improved surgical techniques, percutaneous renal angioplasty, and renal artery stenting—have generated renewed interest in the development of better noninvasive screening tests to identify patients who have potentially correctable hypertension or renal dysfunction caused by renal artery stenosis. Such screening tests have recently emerged, and others offer promise for the near future.

Recommendations for screening for renal artery stenosis have undergone considerable change in the past decade.<sup>1</sup> This review will focus on the clinical utility of the captopril plasma renin activity (PRA) test, captopril renography, duplex ultrasonography, and magnetic resonance angiography (MRA).

**TABLE 1**  
CLINICAL CLUES TO THE PRESENCE  
OF RENOVASCULAR HYPERTENSION

Abrupt onset of hypertension before age 30 or after age 55
Severe hypertension (diastolic blood pressure > 120 mm Hg)
Accelerated or malignant hypertension (with grade III or IV retinopathy by Keith-Wagener-Barker criteria)
Hypertension refractory to triple-drug therapy
Moderate hypertension and diffuse vascular disease (carotid, coronary, peripheral vascular disease)
Epigastric bruit (especially systolic-diastolic)
Moderate hypertension and unexplained azotemia
Azotemia induced by angiotensin-converting enzyme inhibitor therapy

CLINICAL CLUES

Although renovascular hypertension may affect less than 1% of the unselected hypertensive population, it may account for up to 35% of appropriately screened patients referred to subspecialty centers because of refractory hypertension. Screening begins with a thorough medical history and physical examination to determine if the patient has a small, moderate, or great likelihood of having renovascular hypertension.<sup>2,3</sup> Important clinical clues are summarized in *Table 1*. Subsequent noninvasive screening tests have greater predictive value and are more cost-effective in patients who have a greater likelihood of having renovascular disease. In some patients who have clinical clues suggesting an extremely high likelihood of having renovascular disease, the clinician may elect to forego screening tests and proceed directly to renal angiography for definitive diagnosis. Alternatively, a highly specific screening test may help exclude renovascular hypertension in low-risk patients and may thereby obviate a further invasive evaluation.

PATHOPHYSIOLOGY OF RENOVASCULAR  
HYPERTENSION

Renal artery stenosis is generally caused by either atherosclerosis or fibromuscular dysplasia. Atherosclerosis accounts for nearly two thirds of cases of renal artery stenosis, and atherosclerotic renal artery disease may be recognized incidentally during angiography performed to evaluate an abdominal aortic aneurysm or femoral arterial occlusion. In one such series, nearly 40% of patients had

**TABLE 2**  
SENSITIVITY AND SPECIFICITY OF TESTS  
FOR RENOVASCULAR HYPERTENSION\*

Test	Sensitivity, %	Specificity, %
Intravenous pyelography	75	86
Routine renography	75–85	75–85
Captopril renography	93	95
Plasma renin activity	50–80	84
Captopril plasma renin activity test	74	89
Doppler flow ultrasonography	≈90	90–95

\*Adapted from Mann and Pickering, reference 1

renal artery stenosis of greater than 50%, and 15% to 20% had a greater than 75% stenosis.

It is important to distinguish between true renovascular hypertension and renal artery stenosis alone. Although renal artery stenosis is common, true renovascular hypertension may be much less frequent. Renovascular hypertension is defined as high blood pressure caused by renal hypoperfusion, usually due to renal artery stenosis and activation of the renin-angiotensin-aldosterone system. The hallmark of renovascular hypertension is the overproduction of renin by an ischemic kidney, resulting in high blood pressure due to increased total peripheral resistance (mediated by angiotensin II) and sodium retention (mediated by aldosterone).<sup>4,5</sup>

Understanding the renin-angiotensin-aldosterone cascade and the effects of angiotensin-converting enzyme (ACE) inhibition on it is necessary to understand the provocative captopril screening tests.<sup>6</sup> Captopril, an ACE inhibitor, prevents the conversion of angiotensin I to angiotensin II, blocking both the vasoconstrictor and aldosterone-stimulating effects of angiotensin II. The captopril PRA test, originally described by Mueller and colleagues,<sup>7</sup> assesses the magnitude of the hyperreninemic response to ACE inhibition. Effective blockade of angiotensin II generation may have measurable effects on systemic blood pressure, intrarenal blood flow, and renal function; the latter effects form the pathophysiologic basis of captopril renography.<sup>8</sup>

Reduced renal perfusion due to renal artery stenosis causes preferential postglomerular vasoconstriction (mediated by angiotensin II), which helps maintain the glomerular filtration rate (GFR)

**TABLE 3**  
SENSITIVITY AND SPECIFICITY  
OF THE CAPTOPRIL PLASMA RENIN ACTIVITY TEST

Investigator	No. of patients studied	No. of patients with renal artery stenosis	Sensitivity, %	Specificity, %
Mueller et al <sup>7</sup>	152	49	100	95
Derkx et al <sup>10</sup>	179	89	93	84
Frederickson et al <sup>11</sup>	100	29	100	80
Gosse et al <sup>12</sup>	114	11	73	84
Hansen et al <sup>13</sup>	47	11	91	89
Postma et al <sup>14</sup>	149	44	38	93
Svetkey et al <sup>15</sup>	66	11	73	72
Thibonnier et al <sup>16</sup>	65	14	40	100
Elliott et al <sup>17</sup>	100	59	76	58

CAPTOPRIL PLASMA RENIN ACTIVITY TEST

Routine testing for PRA in hypertensive patients is insensitive because only 50% to 80% of patients with renovascular hypertension have increased PRA.<sup>1</sup> Conversely, 15% of all patients with essential hypertension (a very common problem) also have increased PRA. Therefore, the test's lack of specificity was a cause for clinical concern.

Provocative captopril administration has added to the clinical utility of PRA testing.

In a retrospective series, Mueller and colleagues<sup>7</sup> originally demonstrated that patients with renovascular hypertension have a dramatic increase in PRA after taking captopril, whereas patients with essential hypertension have little response. Other investigators subsequently used similar clinical protocols in prospective studies and found the test has acceptable sensitivity and specificity, with some exceptions (Table 3).<sup>7,10-17</sup>

Patient preparation for the test is vital. Ideally, patients should discontinue their antihypertensive medications, maintain a diet adequate in salt, and have good renal function. Baseline measurements of blood pressure and PRA are obtained before and 1 hour after a captopril challenge (25 to 50 mg orally).

The captopril PRA test is relatively safe and inexpensive and can be performed in an outpatient or office setting. It can also be performed simultaneously with captopril renography. The most important limitations of the test are that it does not provide information about renal artery anatomy or individual kidney involvement or function. In addition, sensitivity and specificity may suffer in patients who have compromised renal function or who cannot discontinue their antihypertensive medications.

CAPTOPRIL RENOGRAPHY

Over three decades ago, considerable enthusiasm accompanied the development of radioisotopic renography for the noninvasive diagnosis of renal artery stenosis. Unfortunately, OIH renography per-

of the stenotic kidney. Captopril reduces post-glomerular resistance and decreases the GFR in the stenotic kidney. In contrast, the contralateral, normal kidney exhibits an increase in GFR, urine flow, and salt excretion despite a reduction in systemic blood pressure in response to captopril. This asymmetric response of renal function, which can be detected by renography, has helped to improve the noninvasive diagnosis of renal artery stenosis.<sup>9</sup>

NONINVASIVE SCREENING TESTS

The recommendations for screening hypertensive patients suspected of having renovascular hypertension have undergone considerable change in the last several years.<sup>1</sup> In the past, intravenous pyelography and renography with iodine-131-orthiodohippurate (OIH) were used to search for a small, underperfused kidney. Intravenous pyelography is now used infrequently because of the radiation dose and the potential nephrotoxic effects of the contrast material. Both intravenous pyelography and OIH renography suffer from suboptimal sensitivity and specificity (Table 2).

The captopril provocation tests have considerably greater diagnostic accuracy and are the subject of several recent reviews.<sup>1-3,8</sup> Doppler flow studies of the renal arteries have evolved and may be an effective screening tool in many centers. In the near future, MRA may also emerge as a clinically useful tool for identifying renovascular hypertension. A brief synopsis of the methods, results, and limitations of these tests follows.

formed no better than intravenous pyelography (Table 2). The utility of renography has been enhanced by combining it with the pharmacologic challenge of ACE inhibition with captopril. As reviewed earlier, effective blockade of the renin-angiotensin-aldosterone system causes the GFR of the stenotic kidney to decrease, and one can measure this effect noninvasively with renography.<sup>18</sup> Several small anecdotal series have led to larger clinical studies of captopril renography that are now available for critical review. We offer the following recommendations, based on the observations of the International Consensus Committee on Captopril Renography and subsequent pivotal studies, regarding how to prepare the patient, select the radionuclide, and interpret the results.<sup>19-21</sup>

Patients undergoing captopril renography should be well hydrated and ingest an unrestricted salt diet, but they do not need to discontinue their antihypertensive medications before the study, except for ACE inhibitors. After the baseline blood pressure is measured, captopril (25 to 50 mg by mouth, crushed) is administered and a renogram is obtained using either technetium-99m-diethylenetriaminepenta-acetic acid (Tc-DTPA), technetium-99m-mercaptoacetyl-triglycine (Tc-MAG3), or OIH.

To date, most studies have reported successful results with Tc-DTPA, though other investigators report equally good results with OIH (Table 4).<sup>15,17,22-28</sup> Tc-MAG3 may become the radionuclide of choice because it offers the advantageous labeling characteristics of technetium and optimal renal handling and excretion; it has given promising results in the work of Dondi et al<sup>28</sup> and in a subset of patients in the European Multicenter Cysto Renography trial.<sup>27</sup>

Scintigrams and time-activity curves should both be analyzed to assess renal perfusion, function, and size.<sup>21</sup> If the captopril renogram is abnormal, another renogram may be obtained without captopril for the sake of comparison. The diagnosis of renal artery stenosis is based on asymmetry of renal size and function and on specific captopril-induced changes in the renogram, including: (1) delayed time to maximal activity ( $\geq 11$  minutes); (2) significant asymmetry of the peak activity of each kidney; (3) marked cortical retention of the radionuclide; and (4) marked reduction in the calculated GFR of the ipsilateral kidney (Figure 1).

One must interpret the clinical and renographic data with some caution, as the protocols are complex and the diagnostic criteria are not well stand-

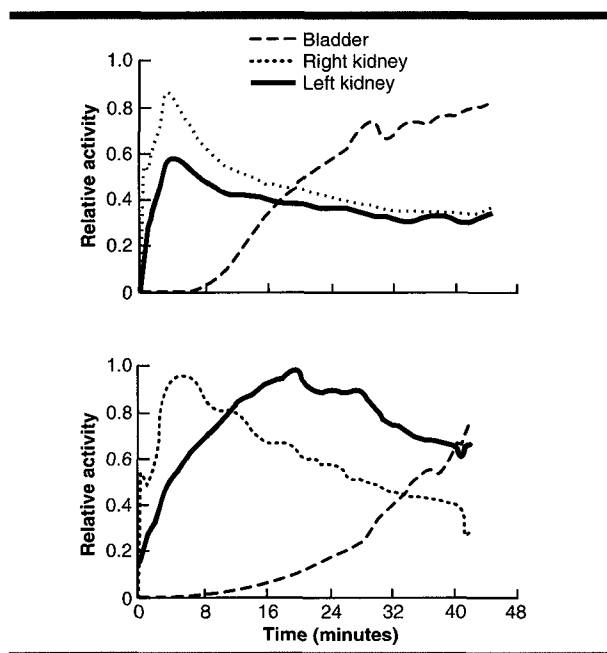


FIGURE 1. Renographic time-activity curves with technetium-99m-diethylenetriaminepenta-acetic acid at baseline (top), and after captopril stimulation (bottom). The delayed time to maximal activity and retention of the radionuclide in the left kidney indicate stenosis of the left renal artery.

ardized.<sup>18</sup> Table 4 summarizes the studies of captopril renography in hypertensive patients suspected of having renovascular hypertension. Overall, the accuracy of captopril renography appears quite acceptable, with a sensitivity of approximately 90% to 93% (range 83% to 94%) and a specificity of approximately 93% to 98% (range 85% to 100%).

The most useful diagnostic criteria appear to be reduced uptake of the radionuclide and prolonged time to maximal activity (ie, delayed excretion) after captopril is given. Although captopril-induced changes were originally postulated as the hallmark of hemodynamically significant renal artery stenosis, Mann et al<sup>26</sup> observed such changes in only 51% of their cases. These changes alone were not sensitive, but they were quite specific. Review of several additional studies reveals that the changes often predict cure or improvement of hypertension in response to a technically successful intervention. Nevertheless, most investigators believe that a single captopril-stimulated study is adequate for screening. The limitation of captopril renography is that it does not provide information about renal artery anatomy. Also, sensitivity and specificity may suffer in patients

**TABLE 4**  
SENSITIVITY, SPECIFICITY, AND PREDICTIVE VALUE OF CAPTOPRIL RENOGRAPHY

Investigator	No. of patients studied	No. of patients with renal artery stenosis	Radionuclide used	Sensitivity, %	Specificity, %	Predicted blood pressure response
Geyskes et al <sup>22</sup>	34	15	OIH*	80	100	Yes: 12/15
Sfakianakis et al <sup>23</sup>	31	16	OIH Tc-DTPA†	67 48	100	...
Erbslöh-Möller et al <sup>24</sup>	40	28	OIH	96	95	Yes: 10/11
Svetkey et al <sup>15</sup>	61	11	Tc-DTPA	74	44	...
Setaro et al <sup>25</sup>	90	44	OIH Tc-DTPA	71 91	41 94	Yes: 15/18
Mann et al <sup>26</sup>	55	35	Tc-DTPA OIH	94 83	95 85	No: 8/19
Fommei et al <sup>27</sup>	472	259	Tc-DTPA (380) Tc-MAG3‡ (74)	83 83	91 100	Yes: 40/43
Dondi et al <sup>28</sup>	102	54	Tc-MAG3	90	92	Yes
Elliott et al <sup>17</sup>	100	59	Tc-Pentetate	92	80	Yes: 51/53

\*Iodine-131-orthoiodohippurate

†Technetium-99m-diethylenetriaminepenta-acetic acid

‡Technetium-99m-mercaptoacetyltriglycine

with azotemia (serum creatinine concentration > 3.0 mg/dL) or bilateral renal artery stenosis.

DUPLEX ULTRASONOGRAPHY

Duplex ultrasonography combines direct visualization of the renal artery (B-mode imaging) with measurement of the velocity of blood flow (Doppler), thereby providing an anatomic assessment of the degree of stenosis, and a functional assessment as well.<sup>29</sup> The kidney size is also measured during the examination.

Unlike other noninvasive screening tests (PRA with or without captopril, captopril renography), duplex ultrasonography does not require patients to discontinue any antihypertensive medications before the test. In addition, the sensitivity and specificity of duplex ultrasonography do not diminish in the presence of bilateral renal artery stenosis or sig-

nificant renal insufficiency as they do in captopril renography. In fact, duplex ultrasonography is an ideal screening test for renal artery stenosis in patients who have significant azotemia.

The study should be performed while the patient is fasting, preferably in the morning to avoid excess bowel gas. It is important to correctly identify and visualize the renal arteries by B-mode imaging. High-definition ultrasonographic equipment and the use of color are helpful in this regard. B-mode imaging cannot directly visualize stenosis or plaque in an artery, even with the most advanced technology available. Adding to the difficulty, the renal arteries are located deep within the abdomen. Rather, the purpose of B-mode imaging is to determine if turbulence is present in the arterial segment and to indicate the correct area to place the Doppler probe so that the velocity of blood flow may be measured (Figure 2).

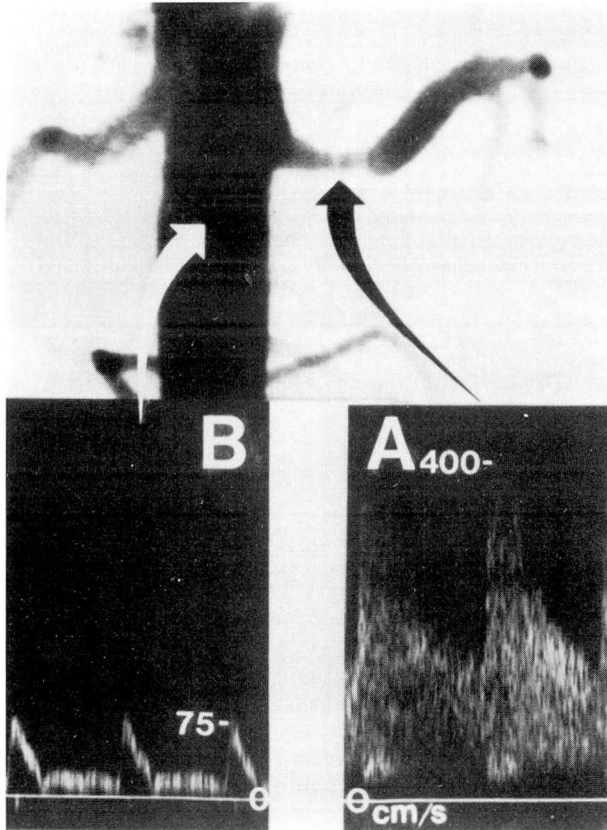
Once the renal arteries are identified, the Doppler signature is taken at a 60° angle. As an arterial segment narrows, the velocity of blood flow increases (Figure 3). Therefore, if the Doppler sample is taken in the correct area, one can accurately estimate the degree of renal artery stenosis from the Doppler measurement of blood flow (Table 5).

Duplex ultrasonography of the renal arteries is technically demanding and difficult to learn; therefore, the results are operator-dependent and may vary considerably among different vascular labora-

**TABLE 5**  
DUPLEX ULTRASONOGRAPHIC CRITERIA FOR RENAL ARTERY STENOSIS

Percent stenosis	Duplex criteria
0 to 59%	Renal-aortic ratio < 3.5
60% to 99%	Renal-aortic ratio ≥ 3.5
Total occlusion	No flow signal from renal artery Low-amplitude parenchymal signal with or without a small kidney





Hoffmann et al. *Kid. Internat.*  
1991;39:1234-1237

FIGURE 4. Angiogram (top) of the aorta (white arrow) and the left renal artery, which is stenotic (black arrow). Doppler scans (bottom) measure the corresponding peak systolic velocities. The peak systolic velocity in the left renal artery was 400 cm/second, and the peak systolic velocity in the aorta was 75 cm/second. Therefore, the renal-aortic ratio was 5.3. From Hoffman U, Edwards JM, Carter S, et al. Role of duplex scanning for the detection of atherosclerotic renal artery disease. *Kidney Int* 1991; 39:1232-1239.

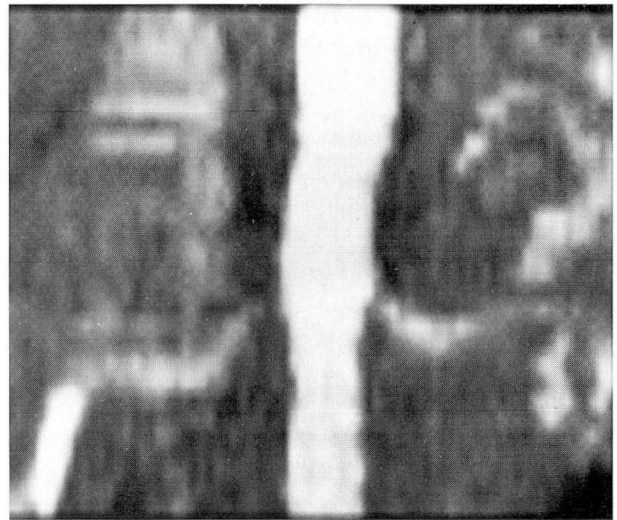
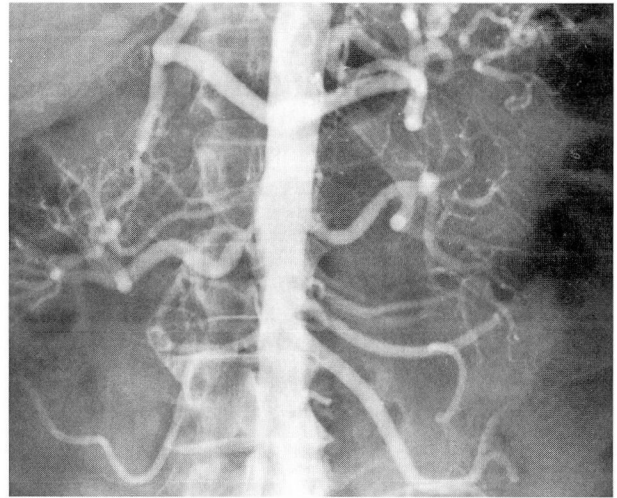


FIGURE 5. Conventional angiogram (top), demonstrating a marked right renal artery stenosis and a mild left renal artery stenosis. The magnetic resonance angiogram (bottom) correlates well with the conventional angiogram.

**TABLE 6**  
ACCURACY OF DUPLEX ULTRASONOGRAPHIC SCANNING OF THE RENAL ARTERIES\*

Group	Sensitivity, %	Specificity, %	Positive predictive value, %	Negative predictive value, %
All kidneys (n = 142)	88	99	98	91
Kidneys with single renal arteries (n = 122)	93	98	98	94
Kidneys with multiple renal arteries (n = 21 arteries)	67	100	100	79
All patients (n = 74 patients)	93	100	100	91

\*From Hansen et al, reference 32, with permission

screening test to use in patients with elevated serum creatinine levels.

---

#### MAGNETIC RESONANCE ANGIOGRAPHY

---

MRA was first described in the early 1980s, when investigators reported the ability to image flowing blood thanks to a "flow void" phenomenon.<sup>38</sup> In 1985, Wedeen et al<sup>39</sup> demonstrated the potential clinical efficacy of MRA. Initial clinical success was achieved in the central nervous system and carotid arteries, where motion artifact and field of view were limited. In recent years, continued advances in equipment and imaging techniques have led to widespread clinical use of MRA.

Kim et al<sup>40</sup> described the potential use of MRA for detecting renal artery stenosis. Subsequently, other accounts of the application of MRA to renal artery disease have been presented.<sup>41,42</sup>

#### Accuracy of magnetic resonance angiography

Selected recent series suggest that the accuracy of MRA in detecting renal artery stenosis equals that of other commonly available screening tests. Kim et al<sup>40</sup> found a sensitivity of 100% and a specificity of 92% in distinguishing renal arteries narrowed more than 50% from normal vessels or those with mild stenosis.<sup>40</sup> Debatin et al<sup>41</sup> found that by analyzing both axial and coronal images, they could achieve a sensitivity of 87% and a specificity of 97%. In a series of 37 patients, Kent et al<sup>42</sup> found that MRA detected stenoses of the renal artery of greater than 50% with a sensitivity of 100% and a specificity of 94%.

In our experience, MRA is 90% to 95% accurate in detecting a renal artery stenosis of greater than 75%. *Figure 5* depicts the correlation between a conventional angiogram and a magnetic resonance angiogram.

#### Advantages of MRA

Like other screening tests, MRA is noninvasive and avoids the potential complications associated with conventional angiography. It does not use ionizing radiation or radioactive or nephrotoxic contrast agents, and it is safe for azotemic patients. Unlike duplex ultrasonography, it is not hindered by excessive bowel gas or obesity. The examination can be performed in only 30 minutes, and no patient preparation is required. The quality of the images is not as operator-dependent as in duplex ultrasonog-

raphy. Both renal arterial and parenchymal anatomy are well demonstrated. It is not uncommon for MRA to show an unexpected pathologic lesion such as an adrenal mass or an aortic aneurysm.

In the future, new technology will allow for the determination of flow velocity and pressure gradients across stenoses.<sup>43</sup> Magnetic resonance contrast agents and spectroscopy will provide information about perfusion and physiology. Spiral computed tomographic scanning already provides excellent three-dimensional images of the renal and mesenteric circulations. However, large amounts of intravenous contrast media are required, thus limiting its utility in patients with azotemia.<sup>44</sup>

MRA may be useful in the evaluation of renal artery stenosis in transplant recipients and donors. Our experience in evaluating potential kidney donors suggests that MRA will eventually obviate the need for conventional angiography in these patients.

#### Disadvantages of MRA

The accuracy of MRA in detecting renal artery stenosis decreases along the length of the artery from the origin toward the renal hilus. However, faster imaging techniques are resolving this problem. Because of the strong magnetic field, patients with pacemakers cannot be studied. Some breath-holding is required, which may compromise the examination in tachypneic states. Metallic objects such as surgical clips can cause artifacts. Finally, a small number of patients are troubled by claustrophobia within the limited space of the core of the magnet.

---

#### SUMMARY

---

One can detect significant renal artery stenosis through a thorough medical history and examination coupled with an effective noninvasive screening test. Captopril-stimulated renography and duplex ultrasonography of the renal arteries have evolved and can be recommended as clinically useful screening tools. However, these tests must be validated within each institution because their performance and interpretation may be partially operator-dependent. In the future, MRA of the renal arteries may emerge as an effective clinical test. Accurate detection of hemodynamically significant renal artery stenosis, followed by judicious intervention, may result in improved blood pressure control and preservation of renal function.



## REFERENCES

- Mann SJ, Pickering TG. Detection of renovascular hypertension. *Ann Intern Med* 1992; 117:845-853.
- Wilcox CS. Use of angiotensin-converting-enzyme inhibitors for diagnosing renovascular hypertension. *Kidney Int* 1993; 44:1379-1390.
- Davidson RA, Wilcox CS. Newer tests for the diagnosis of renovascular disease. *JAMA* 1992; 268:3353-3358.
- Anderson WP, Dentol KM, Woods RL, et al. Angiotensin II and the maintenance of GFR and renal blood flow during renal artery narrowing. *Kidney Int* 1990; 38(suppl 30):S109-S113.
- Ploth DW. Angiotensin-dependent renal mechanism in two-kidney, one-clip renal vascular hypertension. *Am J Physiol* 1983; 245:F131-F141.
- Nally JV. Renal physiology of renal artery stenosis. *Am J Hypertens* 1991; 4:669S-674S.
- Mueller RB, Sealey JE, Case DB, et al. The captopril test for identifying renovascular disease in hypertensive patients. *Am J Med* 1986; 80:633-644.
- Nally JV Jr, Black HR. State-of-the-art review: captopril renography—pathophysiological considerations and clinical observations. *Semin Nucl Med* 1992; 22:85-97.
- Nally JV, Clarke HS Jr, Grecos GP, et al. Effect of captopril on <sup>99m</sup>Tc-diethylene-triaminepentaacetic acid renograms in two-kidney, one-clip hypertension. *Hypertension* 1986; 8:685-693.
- Derkx FHM, Tan-Tjong HL, Wenting GJ, et al. Captopril test for the diagnosis of renal artery stenosis. In Glorioso N, Laragh JH, Rapelli A, editors. *Renovascular Hypertension*. New York: Raven Press, 1987:295-305.
- Frederickson ED, Wilcox CS, Bucci CM, et al. A prospective evaluation of a simplified captopril test for the detection of renovascular hypertension. *Arch Intern Med* 1990; 150:569-572.
- Gosse P, Dupas JY, Reynaud P, et al. Captopril test in the detection of renovascular hypertension in a population with low prevalence of the disease. *Am J Hypertens* 1989; 2:191-193.
- Hansen PB, Garsdal P, Fruergaard P. The captopril test for identification of renovascular hypertension: value and immediate adverse effects. *J Intern Med* 1990; 228:159-163.
- Postma CT, van der Steen PHM, Hoegnagels HL, et al. The captopril test in the detection of renovascular disease in hypertensive patients. *Arch Intern Med* 1990; 150:625-628.
- Svetkey LP, Mimmelstein SI, Dunnick NR. Prospective analysis strategies for diagnosing renovascular hypertension. *Hypertension* 1989; 14:247-257.
- Thibonnier M, Sassano P, Joseph A, Plouin PF, Corvol P, Menard J. Diagnostic value of a single dose of captopril in rein- and aldosterone-dependent, surgically curable hypertension. *Cardiovasc Rev Rep* 1982; 3:1659-1667.
- Elliott WJ, Martin WB, Murphy MB. Comparison of two non-invasive screening tests for renovascular hypertension. *Arch Intern Med* 1993; 153:755-764.
- Nally JV. Provocative captopril testing in the diagnosis of renovascular hypertension. *Urol Clin North Am* 1994; 21:227-234.
- Black HR, Bourgoigne JJ, Pickering T, et al. Report of the working party group for patient selection and preparation. *Am J Hypertens* 1991; 4:745S-746S.
- Blaufox MD, Dubovsky EV, Hilson AJW, et al. Report on working party group on radionuclide of choice. Captopril renogram consensus conference. *Am J Hypertens* 1991; 4:747S-748S.
- Nally JV, Chen C, Fine E, et al. Diagnostic criteria of renovascular hypertension with captopril renography—a consensus statement. *Am J Hypertens* 1991; 4:749S-753S.
- Geyskes GG, Oei HY, Puylaert CBAJ, et al. Renography with captopril. Changes in a patient with hypertension and unilateral renal artery stenosis. *Arch Intern Med* 1986; 146:1705-1708.
- Sfakianakis GN, Bourgoigne JJ, Daffe D, et al. Single dose captopril scintigraphy in the diagnosis of renovascular hypertension. *J Nucl Med* 1987; 28:1383-1392.
- Erbslöh-Möller B, Dumas A, Roth D, et al. Furosemide <sup>131</sup>I-hippuran renography after angiotensin-converting enzyme inhibition for the diagnosis of renovascular hypertension. *Am J Med* 1991; 90:23-40.
- Setaro JF, Saddler MC, Chen CC, et al. Simplified captopril renography in diagnosis and treatment of renal artery stenosis. *Hypertension* 1991; 18:289-298.
- Mann SJ, Pickering RG, Sos TA, et al. Captopril renography in the diagnosis of renal artery stenosis: accuracy and limitations. *Am J Med* 1991; 90:30-40.
- Fommei E, Ghione S, Hilson AJW, et al. Captopril radionuclide test in renovascular hypertension. European Multicentre Study. In O'Reilly PH, Taylor A, Nally JV Jr, editors. *Radionuclides in Nephro-Urology*. Philadelphia: Field & Wood, 1994:33-39.
- Dondi M. Captopril renal scintigraphy with <sup>99m</sup>Tc-Mercaptoacetyl triglycine (<sup>99m</sup>Tc-MAG<sub>3</sub>) for detecting renal artery stenosis. *Am J Hypertens* 1991; 4:737S-740S.
- Burns PN. The physical principles of Doppler and spectral analysis. *J Clin Ultra* 1987; 15:567-590.
- Taylor DC, Kettler MD, Moneta GL, et al. Duplex ultrasound scanning in the diagnosis of renal artery stenosis: a prospective evaluation. *J Vasc Surg* 1988; 7:363-369.
- Kohler TR, Zierler E, Martin RL, et al. Non-invasive diagnosis of renal artery stenosis by ultrasonic duplex scanning. *J Vasc Surg* 1986; 4:450-456.
- Hansen PB, Tribble RW, Reavis SW, et al. Renal duplex sonography; evaluation of clinical utility. *J Vasc Surg* 1990; 12:227-236.
- Eidt JF, Fry RE, Clagett P, et al. Post-operative follow up of renal artery reconstruction with duplex ultrasound. *J Vasc Surg* 1988; 8:667-673.
- Hudspeth DA, Hansen KJ, Reavis SW, et al. Renal duplex sonography after treatment of renovascular disease. *J Vasc Surg* 1993; 18:381-390.
- Taylor DC, Moneta GL, Strandness D Jr. Follow up of renal artery stenosis by duplex ultrasound. *J Vasc Surg* 1989; 9:410-415.
- Maia CR, Bittar AE, Goldani JC, et al. Doppler ultrasonography for the detection of renal artery stenosis in transplanted kidneys. *Hypertension* 1992; 19(Suppl II):II-207-II-209.
- Harward TRS, Smith S, Seeger JM. Detection of celiac axis and superior mesenteric artery occlusive disease with the use of abdominal duplex scanning. *J Vasc Surg* 1993; 17:738-745.
- Crooks LE, Mills CM, Davis PL, et al. Visualization of cerebral and vascular abnormalities by MR imaging; the effects of imaging parameters on contrast. *Radiology* 1982; 144:843-852.
- Wedeen V, Meul R, Edelman R, et al. Projective imaging of pulsatile flow with magnetic resonance. *Science* 1985; 230:946-948.
- Kim D, Edelman PR, Kent KC, Poobes DH, Skillman JJ. Abdominal aorta and renal artery stenosis: evaluation with MR angiography. *Radiology* 1990; 174:727-731.
- Debatin JF, Spritzer CE, Grist TM, et al. Imaging of the renal arteries: value of MR angiography. *Am J Renography* 1991; 157:981-990.
- Kent CK, Edelman RR, Kin D, et al. Magnetic resonance imaging; a reliable test for the evaluation of proximal atherosclerotic renal arterial stenosis. *J Vasc Surg* 1991; 13:311-318.
- Sondergaard L, Stahlberg F, Thansen C, et al. Accuracy and precision of MR velocity mapping in measurement of stenotic cross-sectional area, flow rate and pressure gradient. *Journal of Magnetic Resonance Imaging* 1993; 3:433-437.
- Ruben GD, Walker PJ, Dake MD, et al. 3-dimensional spiral computed tomographic angiography: an alternative imaging modality for the abdominal aorta and its branches. *J Vasc Surg* 1993; 18:656-665.