



**CAROLYN GARDELLA, MD, MPH\***

Assistant professor, University of Washington Department of Obstetrics and Gynecology, Division of Women's Health, Seattle

**ZANE A. BROWN, MD\***

Professor, University of Washington Department of Obstetrics and Gynecology, Division of Perinatology, Seattle

# Managing varicella zoster infection in pregnancy

## ABSTRACT

Varicella zoster virus (VZV) infection can be serious for pregnant women and their babies, although it is rare. The implications of primary VZV infection vary with the gestational age at infection. For the mother, the risk of severe illness is greatest after mid-pregnancy, when she is relatively immunocompromised. For the fetus, the risk of congenital infection is greatest when maternal infection occurs in the first or second trimester. Maternal infection is preventable by preconception vaccination.

## KEY POINTS

Varicella infection during pregnancy can cause congenital anomalies and severe maternal illness.

To prevent congenital varicella infection, women should be asked if they have ever had chickenpox, and those who have not had chickenpox and who do not have VZV antibodies should be immunized before they become pregnant.

Pregnant women exposed to varicella and with no VZV antibodies should be given varicella zoster immunoglobulin and should consider prophylactic antiviral therapy.

Pregnant women who acquire varicella (particularly after mid-pregnancy) are at increased risk of pulmonary complications and may need hospitalization, intravenous acyclovir, and consultation with a perinatologist.

\*The authors both are on the speakers' bureau for GlaxoSmithKline. Their work is supported in part by grant A1-30731 from the National Institute of Allergy and Infectious Diseases.

**A**LTHOUGH VARICELLA ZOSTER VIRUS (VZV) infection, or “chickenpox,” is relatively rare in adults, it can have worse consequences in adults than in children—and especially serious consequences for pregnant women and their babies.

Since the disease is preventable with vaccination, it behooves physicians to try to determine if their female patients are susceptible to VZV infection and to vaccinate them before they become pregnant. And since most women do not see an obstetrician until after they become pregnant, this job falls mostly to primary care physicians.

This article will review the management of varicella infections during pregnancy. It will also include recommendations for preconception counseling related to these infections.

## COMMON IN CHILDREN, RARE IN PREGNANCY

VZV is transmitted from person to person by direct contact, via respiratory droplets or secretions, or via aerosolization of vesicular fluid from skin lesions. The virus enters the host through the upper respiratory tract.

A newly infected person is contagious from 1 to 2 days before the onset of rash until all the lesions are crusted, usually 4 to 5 days after the onset of rash. The average incubation period for varicella is 14 to 16 days (range 10–21 days).

After the primary infection resolves, the virus enters the latent phase and remains dormant in the thoracic sensory ganglia. Reactivation may occur along the sensory dermatome to cause herpes zoster, or “shingles.”

Most people are infected with VZV before they reach adolescence: 90% of adults in the

United States demonstrate immunity to VZV.<sup>1-4</sup> Fortunately, varicella infection occurs only rarely in pregnancy. Because varicella does not need to be reported, accurate estimates of its current incidence in pregnancy are not available.

### **Varicella is worse in adults than in children**

Although VZV infection during pregnancy is uncommon, it is an important cause of maternal morbidity and can cause congenital varicella syndrome or perinatal infection in the newborn.

Primary VZV infection is worse in adults, especially pregnant women, than in children. Only about 2% of all cases occur in adults, but these cases account for 25% of all VZV-related deaths. VZV pneumonitis is 25 times more common in adults and occurs in up to 20% of VZV-infected pregnant women. Smokers and women with more than 100 chickenpox lesions are at higher risk for this complication.<sup>5</sup> In pregnant women with varicella pneumonia, even with treatment the death rate is approximately 14%, with the highest rates among women infected in the third trimester of pregnancy.<sup>6</sup>

### **Maternal VZV infection is bad for the baby**

Intrauterine VZV infection may manifest as congenital varicella syndrome (see below), clinical varicella during the first 28 days of life, or clinical zoster during infancy or early childhood.<sup>6-10</sup> If the onset of varicella in the mother is from 5 days before delivery to 2 days after delivery, an estimated 17% to 30% of the newborns contract severe varicella infection because of the lack of maternal antibody to protect the neonate and the relative immaturity of the neonatal immune system.

Before varicella immunoglobulin was available, the risk of death among neonates born to mothers with the onset of rash up to 4 days before delivery was 31%.<sup>11</sup> This high rate fell to 7% or less after use of varicella immunoglobulin became routine.<sup>12</sup>

### **■ VZV INFECTION IN PREGNANCY IS ALMOST ALWAYS SYMPTOMATIC**

Unlike genital herpes, varicella infection is almost always symptomatic, and laboratory confirmation is rarely needed.

**Prodromal symptoms** of headache, fever, and malaise develop after a 10- to 21-day incubation period.

**The classic rash** appears 1 to 2 days later, beginning as small pruritic macules on the face, trunk, or both and progressing to papules and vesicles. Several crops of these lesions appear every 2 to 3 days for 6 to 10 days.

**Varicella pneumonia** complicates up to 20% of cases of VZV infections in pregnancy. Symptoms tend to appear about 4 days after the onset of the rash and may include cough, shortness of breath, chest pain, and hemoptysis. Auscultatory findings may be minimal; however, chest radiographs typically show bilateral, diffuse peribronchial nodular infiltrates.

Generally, varicella pneumonia is self-limited and resolves within 7 days. However, because some cases can be quite severe, we hospitalize pregnant women with varicella pneumonia to closely monitor their respiratory status and to give them intravenous acyclovir therapy. Even with this therapy, up to 40% of these patients may need mechanical ventilation.<sup>13</sup>

**Less common complications** of varicella infection in pregnancy include encephalitis, pericarditis, myocarditis, hepatitis, thrombocytopenic purpura, glomerulonephritis, and adrenal insufficiency.

### **■ DIAGNOSING VARICELLA INFECTION**

The diagnosis of varicella generally is based on its classic clinical manifestations, and laboratory testing is unnecessary. In cases in which clinical manifestations are not classic but infection is suspected, polymerase chain reaction (PCR) testing for VZV DNA can be performed on specimens obtained from the bases of unroofed vesicles.

The diagnosis of varicella pneumonia relies on the characteristic radiographic findings of bilateral peribronchial nodular infiltrates in a woman with chickenpox. All pregnant women with primary varicella and any respiratory symptom, however mild, should undergo chest radiography with abdominal shielding to confirm varicella pneumonia.

Serologic tests are of limited value during acute varicella infection but are very important in pregnant women who have no history of chickenpox but who are exposed to varicella.

**In pregnant women with varicella pneumonia, the mortality rate is about 14%, even with treatment**

TABLE 1

**Antiviral treatment of varicella zoster virus in pregnancy**

INDICATION	ACYCLOVIR	VALACYCLOVIR
Uncomplicated chickenpox	800 mg by mouth five times per day	1 g by mouth three times a day
Varicella pneumonia	10–15 mg/kg intravenously every 8 hours	

### ■ ALL PREGNANT WOMEN WITH VZV SHOULD RECEIVE TREATMENT

All pregnant women with varicella zoster infection during pregnancy should receive oral acyclovir 800 mg five times per day or valacyclovir 1 g three times a day (TABLE 1).

Clinicians caring for these women should have a low threshold for hospitalizing them and should carefully educate those cared for as outpatients to seek medical attention at the first sign of pulmonary involvement.

Intravenous acyclovir should be given at the first sign of varicella pneumonitis at a dose of 10 to 15 mg/kg every 8 hours. Intravenous acyclovir is also indicated for neurologic symptoms, hemorrhagic rash, continued fever, or appearance of new lesions after 6 days of treatment with oral antiviral therapy.

Women with varicella infection in pregnancy should be managed in cooperation with a qualified perinatologist. Expedited delivery is not indicated for maternal indications, unless the gravid uterus is impairing ventilation, as in the case of severe maternal varicella pneumonia.

### ■ CONGENITAL VARICELLA SYNDROME

Maternal varicella infection in pregnancy can cause congenital varicella syndrome, characterized by cicatricial skin lesions, limb hypoplasia or paresis, microcephaly, and ophthalmic lesions.<sup>7,8</sup> The risk depends on when the mother was infected: about 0.4% if in the first 12 weeks of pregnancy, increasing to 2% if between 13 and 20 weeks.<sup>8</sup>

Although varicella immunoglobulin may prevent or modify the course of maternal chickenpox in pregnancy, it may not prevent congenital varicella syndrome. Therefore, ultrasonography should be performed fre-

quently to look for anatomic abnormalities associated with congenital varicella syndrome if the mother experienced chickenpox in pregnancy or received varicella immunoglobulin because she was susceptible to it and received significant exposure.

At present, there are no reliable prenatal markers to predict fetal disease or disease severity. PCR testing has been used to detect VZV DNA in amniotic fluid and was reported to have excellent negative predictive value but a poor positive predictive value.<sup>14</sup> Serial ultrasound examinations of the fetus may be useful. Consultation with a perinatologist is recommended.

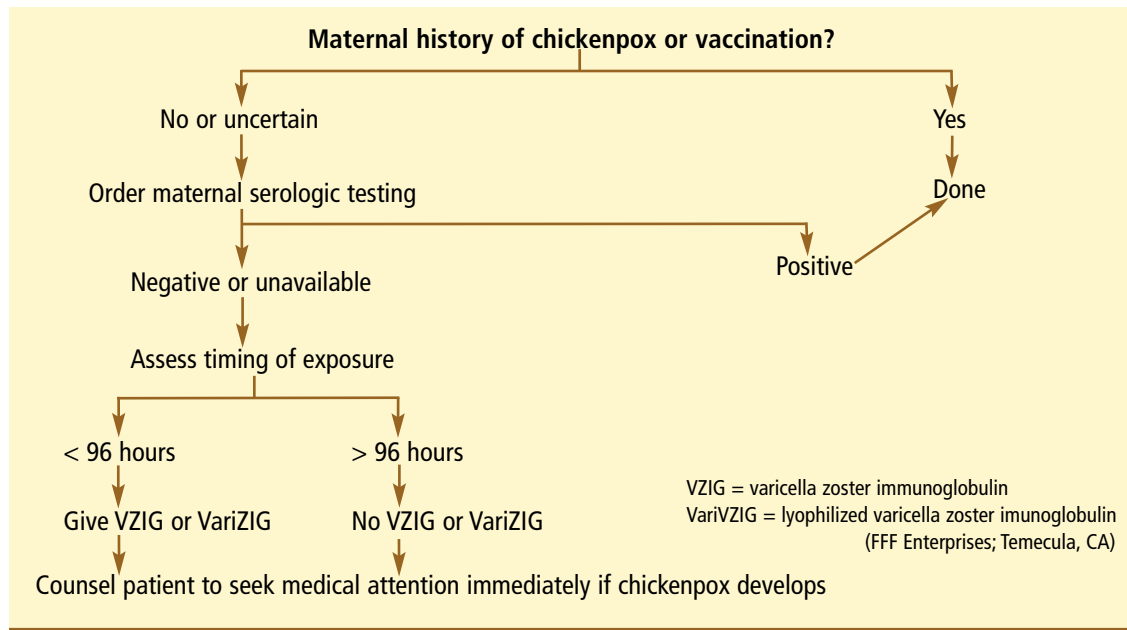
### ■ VACCINATE SUSCEPTIBLE WOMEN BEFORE PREGNANCY

The main method of preventing varicella infection in pregnancy and congenital varicella syndrome is to counsel women before they get pregnant and to immunize them if they are susceptible. Serologic testing is indicated only for women without a history of chickenpox or vaccination.

A reliable history of varicella is a valid marker of immunity because the rash is distinctive and subclinical cases are rare. In adults, 97% to 99% of people who report a history of chickenpox have serologic evidence of immunity. Notably, most adults (71%–93%) who have negative or uncertain histories are also seropositive.<sup>1,15</sup> Therefore, serologic testing before vaccination in women without a history of chickenpox is likely to be cost-effective and is recommended.

Susceptible nonpregnant women should be given two 0.5-mL doses of vaccine subcutaneously, 4 to 8 weeks apart. If more than 8 weeks elapse after the first dose, the second dose can still be given without restarting the schedule.<sup>2</sup>

**Most adults who have negative or uncertain histories of chickenpox are seropositive for VZV**



**FIGURE 1.** Management of exposure to chickenpox during pregnancy

The varicella vaccine is a live-attenuated viral vaccine. As such, it carries the theoretical risk of causing congenital infection and therefore is not recommended in pregnancy. Although the package insert recommends delaying pregnancy until 3 months after vaccination, the US Centers for Disease Control and Prevention (CDC) and the American Academy of Pediatrics condone a 1-month delay.

Inadvertent vaccination of pregnant women occurs occasionally and is not cause for alarm. Since the risk of congenital varicella syndrome after wild-type infection is 0.4% to 2%, the risk of congenital anomalies following vaccination with live-attenuated varicella vaccine is likely to be low or nil.<sup>16</sup> Women who are inadvertently vaccinated in pregnancy or within 1 month of conception should be encouraged to enroll in the VARIVAX pregnancy registry established by Merck and Co. in collaboration with the CDC by calling 800-986-8999.

#### ■ IF A PREGNANT WOMAN IS EXPOSED TO VARICELLA

*Direct-contact exposure* is defined as more than 1 hour of direct contact with an infectious person while indoors. *Significant exposure* for hospitalized patients is defined as sharing the same

hospital room with an infectious patient or prolonged, direct, face-to-face contact with an infectious person such as a health care worker. Brief contacts with an infectious person are less likely to result in transmission of VZV.<sup>16</sup>

#### Give varicella zoster immunoglobulin, if available

Varicella zoster immunoglobulin (VZIG), given at the time of exposure, prevents infection or reduces the severity of infection.<sup>17</sup> All pregnant women who have significant exposure to VZV, who have no history of chickenpox, and who are VZV-seronegative (or for whom serologic testing is not readily available) should be offered VZIG (FIGURE 1).<sup>18</sup>

VZIG should be given within 72 hours of exposure for maximal effect, although it may provide some benefit even if given up to 96 hours after exposure. VZIG is ineffective, and should not be given, once clinical illness is established.<sup>19</sup>

The recommended dose of VZIG is 125 U/10 kg of body weight up to a maximum of 625 U given intramuscularly.<sup>19</sup>

But you may not be able to get VZIG anymore. In October 2004, the only licensed US manufacturer of VZIG stopped producing it, and the supply of the licensed VZIG product is nearly depleted.

**The varicella vaccine is not recommended in pregnancy, but the risk is probably low**

### An investigational VZIG product is available

In February 2006, an investigational, unlicensed VZIG product, VariZIG, became available under an investigational new drug application submitted to the US Food and Drug Administration. Because the product is investigational, patients must give informed consent before receiving the product.

Like VZIG, VariZIG is a purified human immune globulin preparation made from plasma containing high levels of antivariella antibodies; however, VariZIG is lyophilized. When reconstituted, VariZIG is a 5% IgG solution that can be given intramuscularly at a recommended dose of 125 U/10 kg of body weight up to a maximum of 625 U.

Currently, FFF Enterprises (Temecula, CA) is the sole distributor of VariZIG in the United States and must be contacted to place an order (800-843-7477, or [www.fffenterprises.com](http://www.fffenterprises.com)). Usually, orders are delivered within 24 hours.

The CDC recommends that, when immune globulin is indicated, health care providers make every effort to obtain and administer VariZIG. If they cannot give VariZIG within 96 hours of exposure to VZV among pregnant women, clinicians may choose to give “immune globulin intravenous” (IGIV) as an alternative or to monitor the woman closely for signs and symptoms of varicella and start acyclovir treatment if illness occurs. The recommended dose of IGIV is 400 mg/kg given once within 96 hours of exposure. The disadvantage of IGIV is that the titer of antivariella antibodies varies from lot to lot.<sup>19</sup>

Notably, VariZIG might prolong the incubation period by more than 1 week. Therefore, any woman who receives VariZIG should be observed closely for signs or symptoms of varicella for 28 days after exposure. Antiviral therapy should be started immediately if signs or symptoms of varicella infection occur.

### Acyclovir is controversial for varicella prophylaxis

Although varicella zoster immunoglobulin is the cornerstone of prophylaxis, some authorities recommend antiviral chemotherapy either alone or in conjunction with immune globulin therapy.

Acyclovir may prevent infection among

persons exposed to chickenpox. When given to children within 7 to 9 days after family exposure, it was 84% protective against clinical disease.<sup>20</sup>

An Australian pediatric group recommends considering oral acyclovir prophylaxis for susceptible pregnant women exposed to chickenpox who have not received VZIG, or who have risk factors for complications of infection such as chronic lung disease, cigarette smoking, systemic corticosteroid treatment, or impaired immunity, or who are in the second half of pregnancy.<sup>18</sup> However, the CDC notes that additional data are needed concerning the prophylactic use of acyclovir in healthy and immunocompromised persons before such a strategy is considered.<sup>2</sup> In our obstetric practice, we do not routinely prescribe acyclovir in this situation.

### ■ ANTIVIRAL DRUGS FOR VZV IN PREGNANCY

**Acyclovir** is a nucleoside analogue that is highly specific for cells infected with herpes simplex virus and VZV. Once inside the infected cell, acyclovir is selectively activated by the viral thymidine kinase and specifically inhibits viral replication.

Acyclovir crosses the placenta, is concentrated and excreted by the fetal kidney, and is found in the amniotic fluid and fetal tissue. Although it is concentrated in amniotic fluid, it does not appear to accumulate in the fetus.<sup>21</sup>

Because oral acyclovir has low bioavailability, it must be given in frequent doses to achieve therapeutic levels. The limited data available suggest that the physiologic changes that occur in late pregnancy do not significantly alter maternal acyclovir pharmacokinetics, which were similar to those reported for nonpregnant patients.<sup>21,22</sup>

**Valacyclovir**, a prodrug of acyclovir, is converted to acyclovir on first pass through the portal circulation, where its valine moiety is stripped off and metabolized as an amino acid.

Valacyclovir has substantially better bioavailability than acyclovir, and its half-life is longer. Therefore, it does not have to be given as often during the day, which may

**VariZIG is investigational, so patients must give their informed consent before receiving it**

improve compliance.<sup>22,23</sup> However, it is more expensive than acyclovir, and experience in pregnancy is limited because of its relatively recent introduction. Its mechanism of action is not different than that of acyclovir, but the consequences of higher levels of acyclovir in pregnancy are unknown.

Acyclovir and valacyclovir are comparably effective for episodic or suppressive therapy and for the suppression of viral shedding.

**Famciclovir** is a prodrug that undergoes rapid biotransformation to penciclovir, the active antiviral compound. Like valacyclovir, it has a greater bioavailability than acyclovir and can be dosed less frequently than acyclovir. No studies have directly addressed the use of famciclovir in pregnancy and, therefore, at this time there is no recommended dose of famciclovir in pregnancy.

### Antiviral drugs seem safe in pregnancy

Acyclovir, valacyclovir, and famciclovir are in pregnancy category B.

A registry of neonates exposed to acyclovir in utero found no significant teratogenic effects.<sup>24</sup> These data were sufficient to

exclude a sevenfold increase in the risk of birth defects but could not address the risk of rare defects or those detected after the postnatal period.<sup>24</sup> Based on acyclovir toxicity data in neonates undergoing treatment for neonatal herpes, potential neonatal complications of in utero exposure include renal insufficiency and neutropenia.<sup>25</sup>

Small studies of valacyclovir used in late pregnancy found no clinical or laboratory evidence of toxicity in participants or their infants over a 1-month<sup>26</sup> or 6-month follow-up period.<sup>27</sup>

Thus, limited data suggest the safety of antiviral medication in pregnancy. As with any medication used in pregnancy, consideration of the risk vs benefit in each clinical situation and open discussion with the patient should guide prescription.

We believe that the maternal benefit from treating symptomatic herpes simplex virus or VZV in pregnancy outweighs potential fetal risk, especially in the case of symptomatic primary infection occurring in the latter half of pregnancy, or frequent or severe recurrent disease after the first trimester. ■

### REFERENCES

1. Kelley PW, Petruccioli BP, Stehr-Green P, Erickson RL, Mason CJ. The susceptibility of young adult Americans to vaccine-preventable infections. A national serosurvey of US Army recruits. *JAMA* 1991; 266:2724–2729.
2. US Centers for Disease Control and Prevention. Prevention of varicella: recommendations of the Advisory Committee on Immunization Practices (ACIP). *MMWR Recomm Rep* 1996; 45(RR-11):1–36.
3. US Centers for Disease Control and Prevention. Prevention of varicella. Update recommendations of the Advisory Committee on Immunization Practices (ACIP). *MMWR Recomm Rep* 1999; 48(RR-6):1–5.
4. Varicella-zoster infection in pregnancy. *N Engl J Med* 1986; 315:1415–1417.
5. Harger JH, Ernest JM, Thurnau GR, et al. Risk factors and outcome of varicella-zoster virus pneumonia in pregnant women. *J Infect Dis* 2002; 185:422–427.
6. Smego RA Jr, Asperilla MO. Use of acyclovir for varicella pneumonia during pregnancy. *Obstet Gynecol* 1991; 78:1112–1116.
7. Pastuszak AL, Levy M, Schick B, et al. Outcome after maternal varicella infection in the first 20 weeks of pregnancy. *N Engl J Med* 1994; 330:901–905.
8. Enders G, Miller E, Craddock-Watson J, Bolley I, Ridehalgh M. Consequences of varicella and herpes zoster in pregnancy: prospective study of 1739 cases. *Lancet* 1994; 343:1548–1551.
9. Brunell PA. Varicella in pregnancy, the fetus, and the newborn: problems in management. *J Infect Dis* 1992; 166(suppl 1):S42–S47.
10. Balducci J, Rodis JF, Rosengren S, Vintzileos AM, Spivey G, Vosseller C. Pregnancy outcome following first-trimester varicella infection. *Obstet Gynecol* 1992; 79:5–6.
11. Meyers JD. Congenital varicella in term infants: risk reconsidered. *J Infect Dis* 1974; 129:215–217.
12. Miller E, Craddock-Watson JE, Ridehalgh MK. Outcome in newborn babies given anti-varicella-zoster immunoglobulin after perinatal maternal infection with varicella-zoster virus. *Lancet* 1989; 2:371–373.
13. Cox SM, Cunningham FG, Luby J. Management of varicella pneumonia complicating pregnancy. *Am J Perinatol* 1990; 7:300–301.
14. Mouly F, Mirlesse V, Meritet JF, et al. Prenatal diagnosis of fetal varicella-zoster virus infection with polymerase chain reaction of amniotic fluid in 107 cases. *Am J Obstet Gynecol* 1997; 177:894–898.
15. Ferson MJ, Bell SM, Robertson PW. Determination and importance of varicella immune status of nursing staff in a children's hospital. *J Hosp Infect* 1990; 15:347–351.
16. Varicella vaccine—FAQs related to pregnancy. <http://www.cdc.gov/nip/vaccine/varicella/faqs-clinic-vac-preg.htm>. (Accessed January 31, 2007).
17. Brunell PA, Ross A, Miller LH, Kuo B. Prevention of varicella by zoster immune globulin. *N Engl J Med* 1969; 280:1191–1194.
18. Heuchan AM, Isaacs D. The management of varicella-zoster virus exposure and infection in pregnancy and the newborn period. Australasian Subgroup in Paediatric Infectious Diseases of the Australasian Society for Infectious Diseases. *Med J Aust* 2001; 174:288–292.
19. US Centers for Disease Control and Prevention. A new product (VariZIG) for postexposure prophylaxis of varicella available under an investigational new drug application expanded access protocol. *MMWR Morb Mortal Wkly Rep* 2006; 55:209–210.

**We believe the maternal benefit from treating symptomatic HSV or VZV in pregnancy outweighs the fetal risk**

20. **Asano Y, Yoshikawa T, Suga S, et al.** Postexposure prophylaxis of varicella in family contact by oral acyclovir. *Pediatrics* 1993; 92:219–222.
  21. **Frenkel LM, Brown ZA, Bryson YJ, et al.** Pharmacokinetics of acyclovir in the term human pregnancy and neonate. *Am J Obstet Gynecol* 1991; 164:569–576.
  22. **Kimberlin DF, Weller S, Whitley RJ, et al.** Pharmacokinetics of oral valacyclovir and acyclovir in late pregnancy. *Am J Obstet Gynecol* 1998; 179:846–851.
  23. **Beutner KR.** Valacyclovir: a review of its antiviral activity, pharmacokinetic properties, and clinical efficacy. *Antiviral Res* 1995; 28:281–290.
  24. **Stone KM, Reiff-Eldridge R, White AD, et al.** Pregnancy outcomes following systemic prenatal acyclovir exposure: conclusions from the international acyclovir pregnancy registry, 1984–1999. *Birth Defects Res A Clin Mol Teratol* 2004; 70:201–207.
  25. **Kimberlin D, Lin C-Y, Jacobs R, et al.** Natural history of neonatal herpes simplex virus infections in the acyclovir era. *Pediatrics* 2001; 108:223–229.
  26. **Sheffield JS HJ, Laibl V, Hollier LM, Sanchez P, Wendel GD.** Valacyclovir suppression to prevent recurrent herpes at delivery: a randomized controlled trial [abstract]. *Obstet Gynecol* 2005; 104:55.
  27. **Tyring SK, Baker D, Snowden W.** Valacyclovir for herpes simplex virus infections: long-term safety and sustained efficacy after 20 years' experience with acyclovir. *J Infect Dis* 2002; 186(suppl 1):S40–S46.
- 
- ADDRESS:** Carolyn Gardella, MD, MPH, Department of Obstetrics and Gynecology, University of Washington Medical Center, Box 356460, Seattle, WA 98195-6460; e-mail [cgardel@u.washington.edu](mailto:cgardel@u.washington.edu).