

## THE CLINICAL PICTURE

**IVÁN ÁLVAREZ-TWOSE, MD**

Instituto de Estudios de Mastocitosis de Castilla La Mancha, Hospital Virgen del Valle, Toledo, Spain

**SERGIO VAÑÓ-GALVÁN, MD, PhD**

Department of Dermatology, Ramon y Cajal Hospital, Madrid, Spain

**LAURA SANCHEZ-MUÑOZ, MD, PhD**

Instituto de Estudios de Mastocitosis de Castilla La Mancha, Hospital Virgen del Valle, Toledo, Spain

**SOLEDAD FERNANDEZ-ZAPARDIEL, MD**

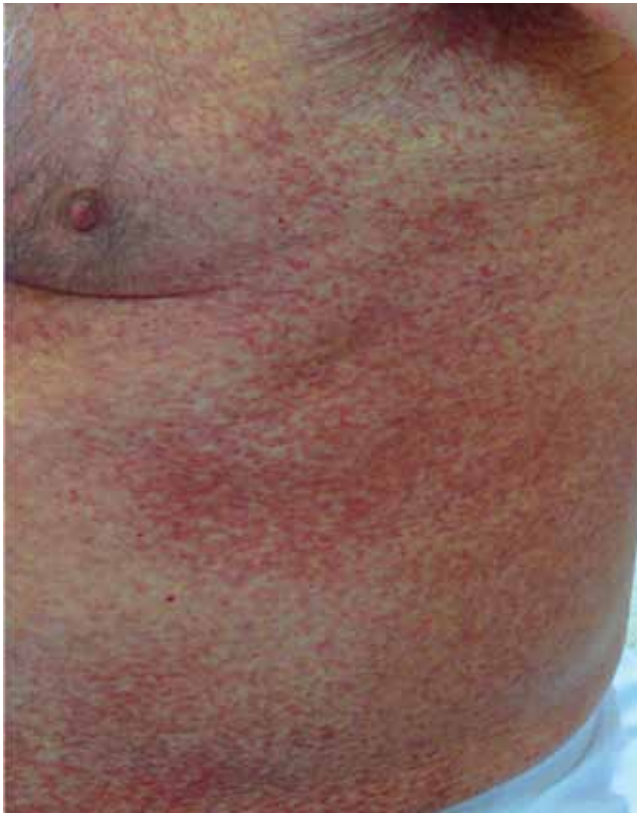Department of Radiology, Hospital Virgen de la Salud, Toledo, Spain

**LUIS ESCRIBANO, MD, PhD**

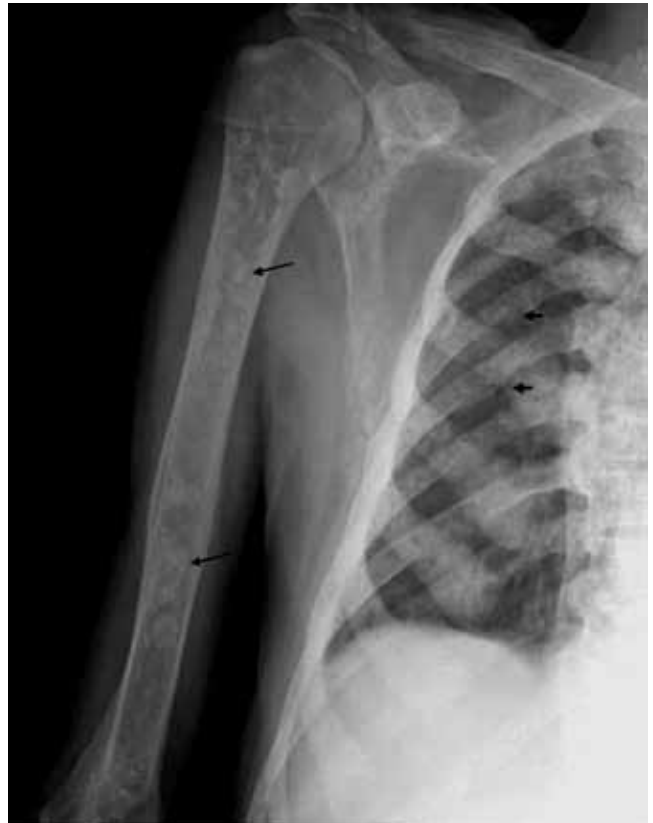Instituto de Estudios de Mastocitosis de Castilla La Mancha, Hospital Virgen del Valle, Toledo, Spain

# The Clinical Picture

## Anemia, leukocytosis, abdominal pain, flushing, and bone and skin lesions



**FIGURE 1.** Confluent erythematous maculopapular lesions involving the trunk (maculopapular cutaneous mastocytosis).

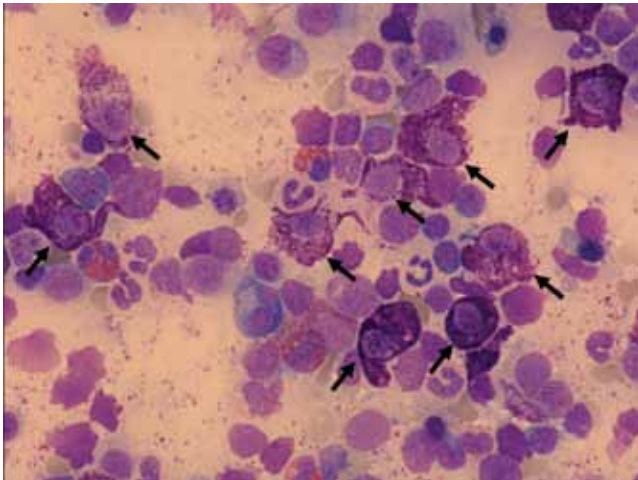


**FIGURE 2.** Radiologic evaluation showed diffuse osteosclerosis together with lytic and blastic areas (arrows).

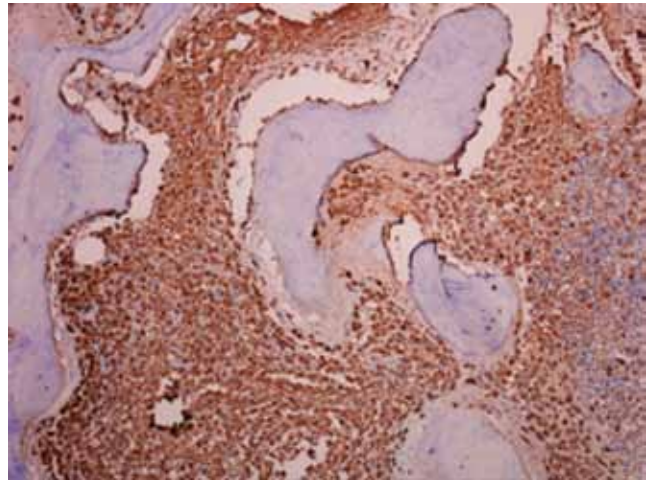
**A** 72-YEAR-OLD MAN presented with abdominal cramping, diarrhea, intermittent flushing, asthenia, and a weight loss of 10 kg (22 lb) in the past 6 months. Physical

examination revealed hepatosplenomegaly and an erythematous, maculopapular, confluent rash on the trunk (**FIGURE 1**) that displayed the Darier sign (redness, swelling, and itching in response to stroking in the involved area).

doi:10.3949/ccjm.79a.10137



**FIGURE 3.** Bone marrow smear demonstrating increased numbers of abnormal mast cells (May-Grünwald-Giemsa stain, x 600).



**FIGURE 4.** Bone marrow study demonstrating a massive infiltrate of abnormal mast cells (tryptase stain, x 200).

**Laboratory analyses**

- Hemoglobin 9.8 g/dL (normal 13–17 g/dL)
- White blood cell count  $22.9 \times 10^9/L$  (3.8–10)
- Vitamin B<sub>12</sub> 1,730 pg/mL (220–900)
- Serum tryptase 516 µg/L (5.5–13.5)
- Beta-2 microglobulin 4.14 mg/L (1.39–2.11).

**Radiologic evaluation**

Radiologic evaluation showed diffuse osteosclerosis with lytic and blastic areas (FIGURE 2).

**Q:** Which is the most likely diagnosis?

- Carcinoid syndrome
- Histiocytosis
- Acute myeloblastic leukemia
- Systemic mastocytosis
- Chronic myeloblastic leukemia

**A:** The correct answer is systemic mastocytosis. The diagnosis was made according to the World Health Organization (WHO) diagnostic criteria for mastocytosis on the basis of the following findings in the bone marrow:

- Morphologically abnormal mast cells characterized by large size, spindle shape and poorly granulated cytoplasm (FIGURE 3) together with criteria for refractory cytopenia and multilineage dysplasia
- Diffuse infiltration by tryptase-positive mast cells as assessed by immunohistochemical study (FIGURE 4)

- One percent of mast cells that are immunophenotypically aberrant (CD25<sup>bright+</sup>), all of them showing an immature profile,<sup>1</sup> associated with features of multilineage dysplasia<sup>2</sup> as assessed by flow cytometry
- The activating D816V *KIT* mutation, detected by peptide nucleic acid-mediated polymerase chain reaction clamping technique.<sup>3</sup>

■ **MASTOCYTOSIS HAS SEVEN VARIANTS**

Mastocytosis is a rare heterogeneous group of disorders characterized by proliferation and accumulation of abnormal mast cells in diverse organs and tissues, such as the skin, bone marrow, gastrointestinal tract, liver, spleen, or lymph nodes.<sup>4–6</sup> The release of mast cell mediators causes a wide variety of symptoms, ranging from pruritus, flushing, abdominal cramping, and diarrhea to severe anaphylaxis with vascular collapse.<sup>7,8</sup>

The WHO defines seven variants<sup>6</sup>:

- Cutaneous mastocytosis
- Indolent systemic mastocytosis
- Systemic mastocytosis with an associated (clonal) hematologic non-mast-cell disease (SM-AHNMD)
- Aggressive systemic mastocytosis
- Mast cell leukemia
- Mast cell sarcoma
- Extracutaneous mastocytoma.<sup>6</sup>

**The release of mast cell mediators causes a wide variety of symptoms**

***KIT* mutation as a diagnostic criterion and prognostic factor**

In most cases of systemic involvement, the clonal nature of the disease can be established by finding activating mutations of *KIT*, usually D816V, in lesions in the skin, bone marrow cells, or both.<sup>9</sup> Apart from its value as a diagnostic criterion for systemic mastocytosis, *KIT* mutation has been reported to be strongly associated with progression of indolent systemic mastocytosis, including the development of myeloid malignancies, when the mutation is detected not only in mast cells but in all hematopoietic lineages.<sup>10</sup>

In cases of SM-AHNMD, a possible pathophysiologic relationship between the disorder in the mast cells and the disorder in other cells could be explained by a *KIT* mutation in early hematopoietic progenitor cells, which further evolve into phenotypically different subclones.

A rational management plan for mastocytosis must include carefully counselling the patient and care providers, avoiding factors that trigger acute release of mast cell mediators, and giving antimediator therapy such as oral cromolyn sodium (Gastrocrom), antihistamines, and leukotriene antagonists to relieve the symptoms caused by mast-cell-mediator

release.<sup>11</sup> In cases of SM-AHNMD, the clinical course and long-term prognosis are usually dominated by the concomitant hematologic malignancy, which should be treated as a separate entity.

**■ CASE CONTINUED**

Our patient's bone marrow was analyzed for the *KIT* mutation in highly purified bone marrow cell subpopulations sorted by fluorescence-activated cell sorting. The mutation was detected in his mast cells, CD34+ cells, eosinophils, monocytes, neutrophils, lymphocytes, and nucleated erythroid precursors. According to the WHO recommendations, he had SM-AHNMD, the associated hematologic disease being a myelodysplastic syndrome.

In view of his advanced age and concomitant myelodysplastic syndrome presenting with leukocytosis, we gave him hydroxyurea (Droxia; available in Spain as Hydrea) rather than other cytoreductive drugs as the first-line therapy. Additionally, we gave him corticosteroids in low doses, sodium cromolyn, and antihistamines to treat mastocytosis-related gastrointestinal symptoms. The patient was alive with stable disease 14 months after starting therapy. ■

**The patient was alive with stable disease 14 months after starting therapy**

**■ REFERENCES**

1. Teodosio C, García-Montero AC, Jara-Acevedo M, et al. Mast cells from different molecular and prognostic subtypes of systemic mastocytosis display distinct immunophenotypes. *J Allergy Clin Immunol* 2010; 125:719–726.
2. van de Loosdrecht AA, Alhan C, Béné MC, et al. Standardization of flow cytometry in myelodysplastic syndromes: report from the first European LeukemiaNet working conference on flow cytometry in myelodysplastic syndromes. *Haematologica* 2009; 94:1124–1134.
3. Sotlar K, Escribano L, Landt O, et al. One-step detection of c-kit point mutations using peptide nucleic acid-mediated polymerase chain reaction clamping and hybridization probes. *Am J Pathol* 2003; 162:737–746.
4. Valent P, Horny HP, Escribano L, et al. Diagnostic criteria and classification of mastocytosis: a consensus proposal. *Leuk Res* 2001; 25:603–625.
5. Valent P, Akin C, Escribano L, et al. Standards and standardization in mastocytosis: consensus statements on diagnostics, treatment recommendations and response criteria. *Eur J Clin Invest* 2007; 37:435–453.
6. Horny HP, Metcalfe DD, Bennet JM, et al. Mastocytosis. In: Swerdlow SH, Campo E, Harris NL, et al, editors. *WHO Classification of Tumours of Haematopoietic and Lymphoid Tissues*. Lyon, France: International Agency for Research on Cancer; 2008:54–63.
7. Castells M. Mast cell mediators in allergic inflammation and mastocytosis. *Immunol Allergy Clin North Am* 2006; 26:465–485.
8. González de Olano D, de la Hoz Caballer B, Núñez López R, et al. Prevalence of allergy and anaphylactic symptoms in 210 adult and pediatric patients with mastocytosis in Spain: a study of the Spanish network on mastocytosis (REMA). *Clin Exp Allergy* 2007; 37:1547–1555.
9. Garcia-Montero AC, Jara-Acevedo M, Teodosio C, et al. *KIT* mutation in mast cells and other bone marrow hematopoietic cell lineages in systemic mast cell disorders: a prospective study of the Spanish Network on Mastocytosis (REMA) in a series of 113 patients. *Blood* 2006; 108:2366–2372.
10. Escribano L, Alvarez-Twose I, Sánchez-Muñoz L, et al. Prognosis in adult indolent systemic mastocytosis: a long-term study of the Spanish Network on Mastocytosis in a series of 145 patients. *J Allergy Clin Immunol* 2009; 124:514–521.
11. Escribano L, Akin C, Castells M, Schwartz LB. Current options in the treatment of mast cell mediator-related symptoms in mastocytosis. *Inflamm Allergy Drug Targets* 2006; 5:61–77.

ADDRESS: Sergio Vañó-Galván, MD, PhD, Carretera Colmenar Viejo km 9.100, 28034 Madrid, Spain; e-mail sergiovano@yahoo.es.