

HEREDITARY DEAFNESS DUE TO BILATERAL ACOUSTIC TUMORS

*A Clinical Study and Field Survey of a Family of Five Generations
With a History of Bilateral Deafness in Thirty-eight
Members*

W. JAMES GARDNER, M.D., Cleveland,

and

CHARLES H. FRAZIER, M.D., ScD., Philadelphia

That hereditary deafness may be the result of bilateral acoustic tumors has not hitherto been recorded. The investigation described in this report was suggested by a statement in the history of such a case which intimated deafness in a number of the family connections for five generations. The survey of this family disclosed a history of bilateral deafness in thirty-eight members, with subsequent blindness in fifteen instances. Of the deaf and blind persons, four were examined prior to death and were found to have choking of the optic discs with secondary atrophy. The seven affected members living were personally examined and presented the clinical findings of bilateral acoustic tumors. The presence of these lesions was proved by necropsy in two cases. Following is the case record of the patient whose history stimulated the investigation:

VA 6, a man, aged 28 (see Fig. 7), was admitted to the neurosurgical service of the University Hospital on October 9, 1928. He was referred to the clinic by Dr. T. K. Wood, of Muncy, Pa., who apparently was the first physician to recognize the unique hereditary tendency of the disease in this family. The chief complaint was deafness and blindness.

The history of this patient's illness was essentially a repetition of a common complaint that had affected many members of his family for five generations. The patient stated that partial deafness had begun at the age of 17. Whether or not the onset and progress of the condition in both ears was concurrent is not known. The

Published in detail in the *Archives of Neurology and Psychiatry*, 23: 266-300, February, 1930.

Reprinted by permission of ANNALS OF OTOTOLOGY, RHINOLOGY AND LARYNGOLOGY, 1930, Vol. 39, page 974.

deafness, however, increased steadily and became complete six weeks prior to admission, coincident with a beginning failure of vision. This failure of vision progressed rapidly, and total blindness was present for two weeks before admission. After the development of complete deafness there had been considerable vomiting. Vertigo and a staggering gait had been present for four months. Whether or not tinnitus was a symptom could not be determined.

On physical examination the patient was found to be a well developed man who showed some evidence of loss of weight. He was totally blind and deaf, but able to talk. He was very drowsy, but when awakened was fairly alert. He was well oriented and cooperative. In order to communicate with him it was necessary to spell out the words on his right palm, using his left index finger to draw the letters.*

On neurologic examination, it was found that the patient's gait was slow and unsteady. He staggered to the right and left, and after walking a short distance he usually fell backward. In the Romberg test, also, he fell backward. Dysmetria was apparent in the finger-to-nose test on both sides, but the heel-to-knee test was well performed. In testing for dysdiadokokinesia, the movements were slow but well co-ordinated. There was no spontaneous nystagmus. The pupils were 4 mm. in diameter and fixed to light. Ocular rotation was limited in all directions, but particularly external rotation of the left eye. There was bilateral loss of the sense of smell and total blindness in both eyes. Examination of the fundi revealed a choking of nine diopters in the left eye and eight diopters in the right, with numerous hemorrhages. The corneal reflexes were slightly sluggish. No evidence of involvement of the seventh nerve was found. Both ears were totally deaf. The ninth, tenth, eleventh and twelfth nerves appeared to function normally. The speech was slow but the words were clearly spoken. All the tendon reflexes were equally diminished, but there were no pathologic reflexes. An audiogram disclosed a hearing loss of 100 per cent in each ear. The blood and spinal fluid Wassermann reactions were negative. Roentgenograms of the skull revealed no abnormalities except a suggestion of erosion of the inner portion of each petrous ridge. Barany examination by Dr. Lewis Fisher proved the eighth nerves to be entirely nonfunctioning in both the cochlear and vestibular portions.

*It is of interest that all the members of this family who became deaf and blind used this method of receiving communications from the outside world, provided their education was sufficient to enable them to read and write prior to the onset of blindness. This method of communication has been given the name of "graphesthesia" by Spiller in his lectures to the students at the University of Pennsylvania.

A diagnosis of bilateral acoustic tumors was made, and suboccipital craniectomy was performed on October 30, 1928, by Dr. Frazier. A large right acoustic tumor was found and partially removed by the intracapsular method. No tumor was seen in the left recess, but a careful search was not made. The post-operative course was stormy, and the patient died three days after the operation from a hemorrhage into the ventricles of undetermined origin.

Necropsy disclosed bilateral acoustic tumors, the larger one being on the right side (see Fig. 1). There were no other tumors on the brain or meninges.

Histologic examination of the tumor tissue by the hematoxylin-eosin stain disclosed interlacing streams of connective tissue fibers with interspersed areas of a looser reticular nature (tissue types *B* and *A* of Antoni). In some of the fibrous streams there was a faint suggestion of nuclear palisading (see Figs. 2 and 3). On staining by the Gross-Bielschowsky method it was evident that nerve fibers actually had penetrated the tumor tissue and not the capsule alone (see Figs. 4 and 5). The lesions, therefore, were not of the nature of the ordinary isolated acoustic tumor, or perineural fibroblastoma, in which the nerve fibers are present only in the capsule, but they are of the nature of the true neurofibroma of von Recklinghausen's disease,² in which the nerve fibers are found within the tumor tissue proper. The histologic diagnosis was "bilateral acoustic neurofibromas."

In this family the condition has been transmitted as a true mendelian dominant character, as may be seen readily by the charts presented in Figs. 6, 7 and 8. The information regarding the first two generations is rather scanty, and was furnished by the only living member of the third generation (VIII, Fig. 7). It is therefore, open to question. The information regarding the last three generations, however, was either verified from several sources or by personal examination. To date it has been possible to trace the issue of only one of the twelve members of the second generation.

A most interesting observation in this family is that four children born of affected parents were found to have absent vestibular responses in the Barany tests with little or no impairment of hearing. This was interpreted as meaning that these subjects had the condition in an early or latent stage of development. It would seem therefore, to yield clinical corroboration to Henschen's³ post-mortem observation that acoustic tumors originate on the vestibular portion of the eighth nerve.

HEREDITARY DEAFNESS DUE TO TUMORS

SUMMARY OF THE OBSERVATIONS IN SIXTEEN OF THE AFFECTED PERSONS

Case	Age, Years		Duration Tinnitus		Duration Partial Deafness		Duration Complete Deafness		Duration Blindness		Hearing Tuning Fork Tests, Inches				Vestibular Reaction, Absent (0), Impaired (1)				Method Turning (1) Deafening (D) Both (B)		Corneal Reflex Absent (0) Impaired (1) Normal (2)			
	Right	Left	Right	Left	Right	Left	Right	Left	Right	Left	Right	Left	Right	Left	Right	Left	Right	Left	Right	Left	Right	Left		
IVF	?	12	?	?	?	?	?	?	?	?	?	?	?	?	?	?	?	?	?	?	B	B	1	1
IVG	61	20	?	?	?	?	?	?	?	?	?	?	?	?	?	?	?	?	?	?	B	B	2	1
IVG2	34	7 1/2	?	?	?	?	?	?	?	?	?	?	?	?	?	?	?	?	?	?	D	D	0	0
VA3	30	15	?	?	?	?	?	?	?	?	?	?	?	?	?	?	?	?	?	?	B	B	1	1
VA5	28	?	?	?	?	?	?	?	?	?	?	?	?	?	?	?	?	?	?	?	D	D	1	1
VA7	26	?	?	?	?	?	?	?	?	?	?	?	?	?	?	?	?	?	?	?	B	B	1	2
VI	56	?	?	?	?	?	?	?	?	?	?	?	?	?	?	?	?	?	?	?	B	B	1	1
VI2	37	21	?	?	?	?	?	?	?	?	?	?	?	?	?	?	?	?	?	?	B	B	1	1
IVG7	22	0	?	?	?	?	?	?	?	?	?	?	?	?	?	?	?	?	?	?	B	B	2	1
VA9	21	3(?)	?	?	?	?	?	?	?	?	?	?	?	?	?	?	?	?	?	?	B	B	2	2
VD	56	0	?	?	?	?	?	?	?	?	?	?	?	?	?	?	?	?	?	?	B	B	1	1
VIIID	55	?	?	?	?	?	?	?	?	?	?	?	?	?	?	?	?	?	?	?	D	D	0	0
IVL	10	1	?	?	?	?	?	?	?	?	?	?	?	?	?	?	?	?	?	?	B	B	2	2
IVF	44	0	?	?	?	?	?	?	?	?	?	?	?	?	?	?	?	?	?	?	D	D	1	1
VAI	38	?	?	?	?	?	?	?	?	?	?	?	?	?	?	?	?	?	?	?	D	D	2	1

† Weeks; ‡ Months; * Impacted cerumen.

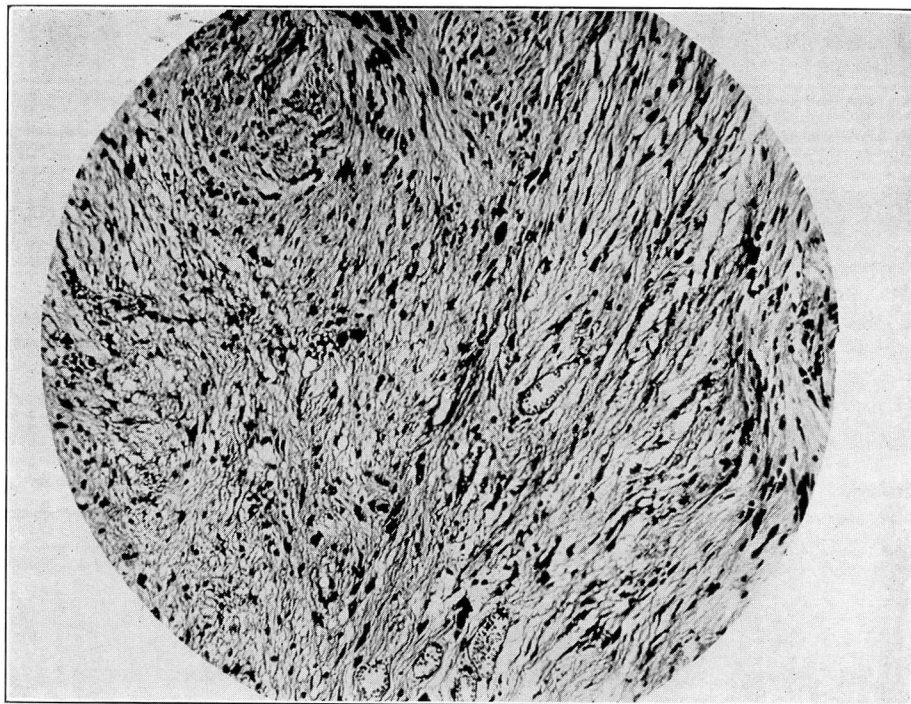


Fig. 2. Patient VA6. Fibrous streams with interspersed areas of looser reticular nature. A suggestion of palisading is evident to the right of the center. Hematoxylin and eosin stain; X160.

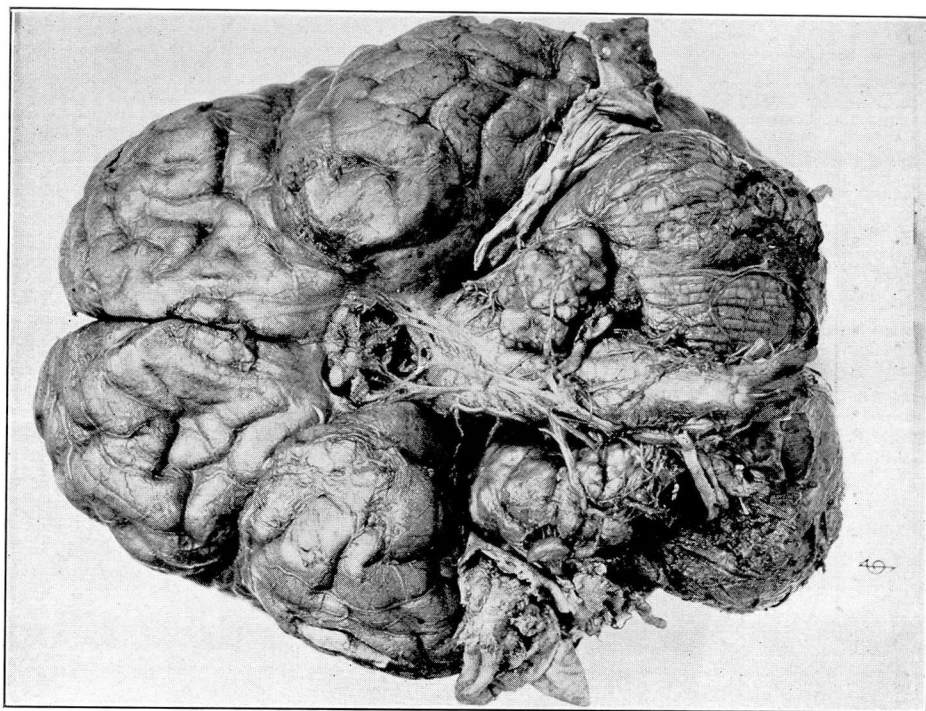


Fig. 1. Patient VA6. The larger tumor on the right is attached to the dura.

HEREDITARY DEAFNESS DUE TO TUMORS

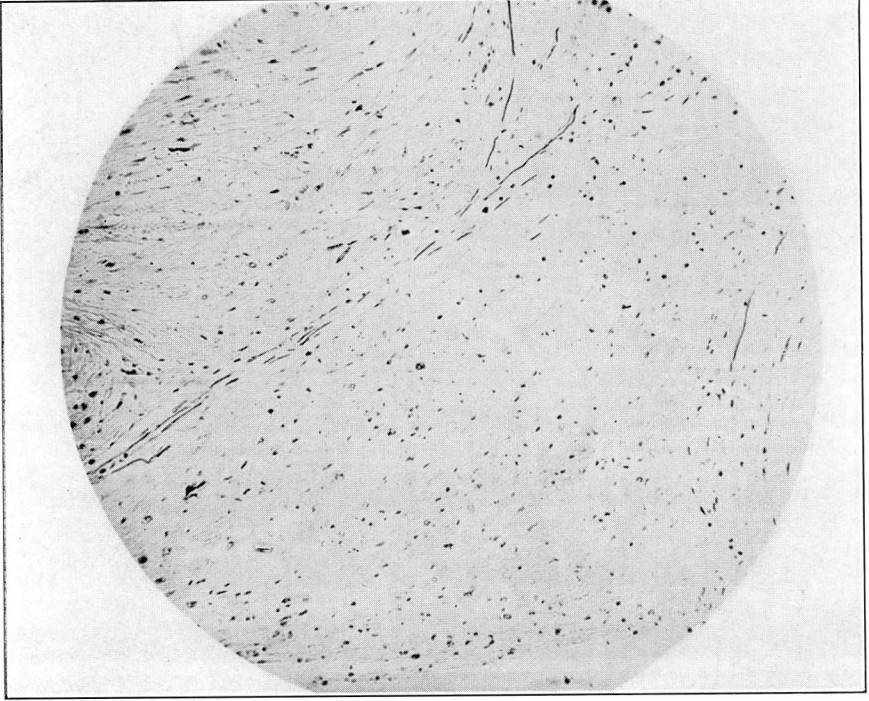


Fig. 4. Patient VA6. Nerve fibres are seen invading the tumor tissue. Gross-Bielschowsky stain; X160.

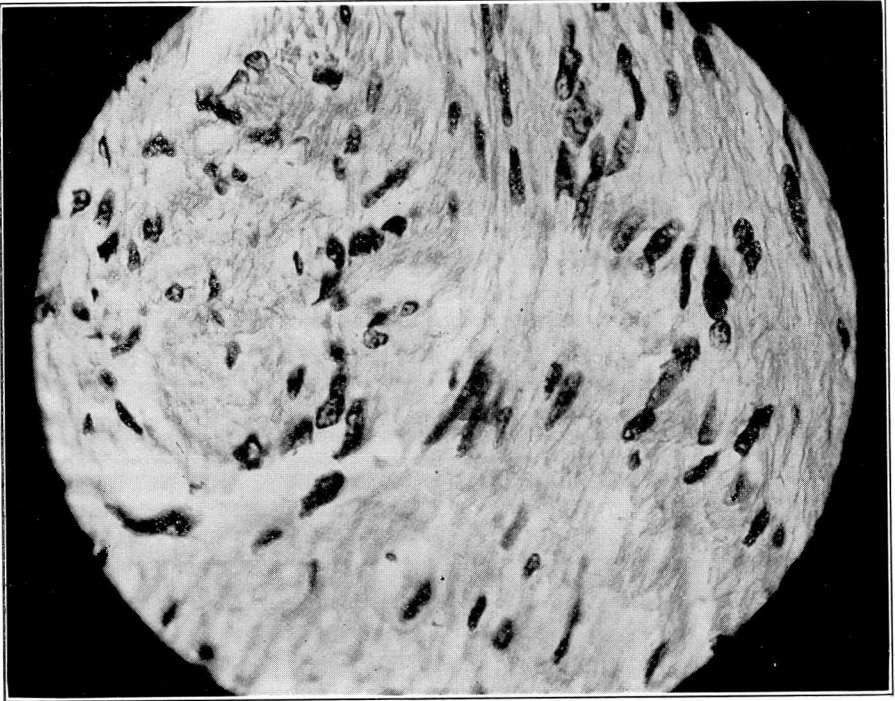


Fig. 3. The same field shown in Fig. 2, but under a higher power; X627.

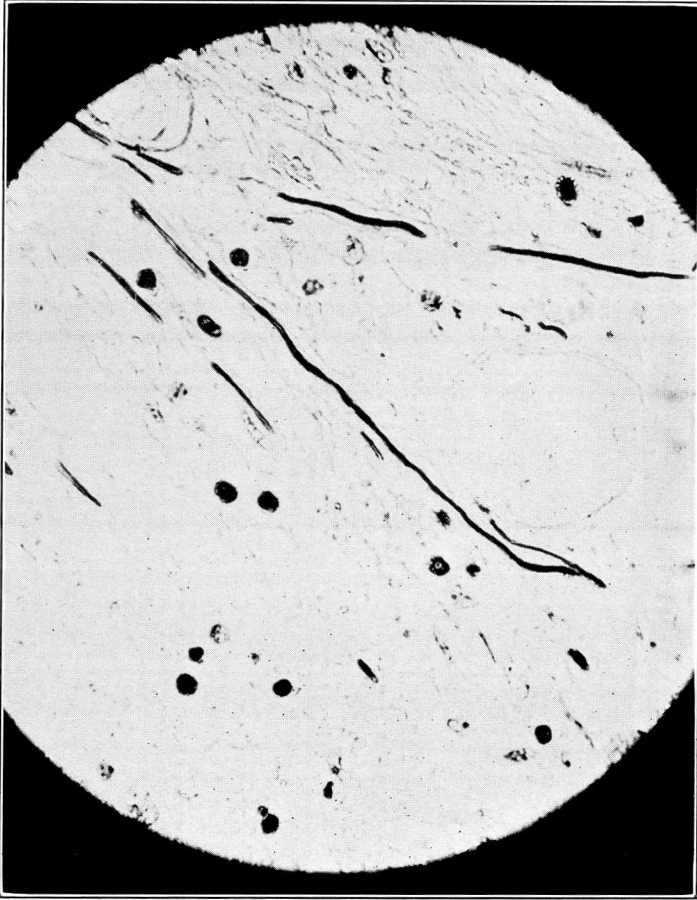


Fig. 5. The same field shown in Fig. 4, but under a higher power; X627.

HEREDITARY DEAFNESS DUE TO TUMORS

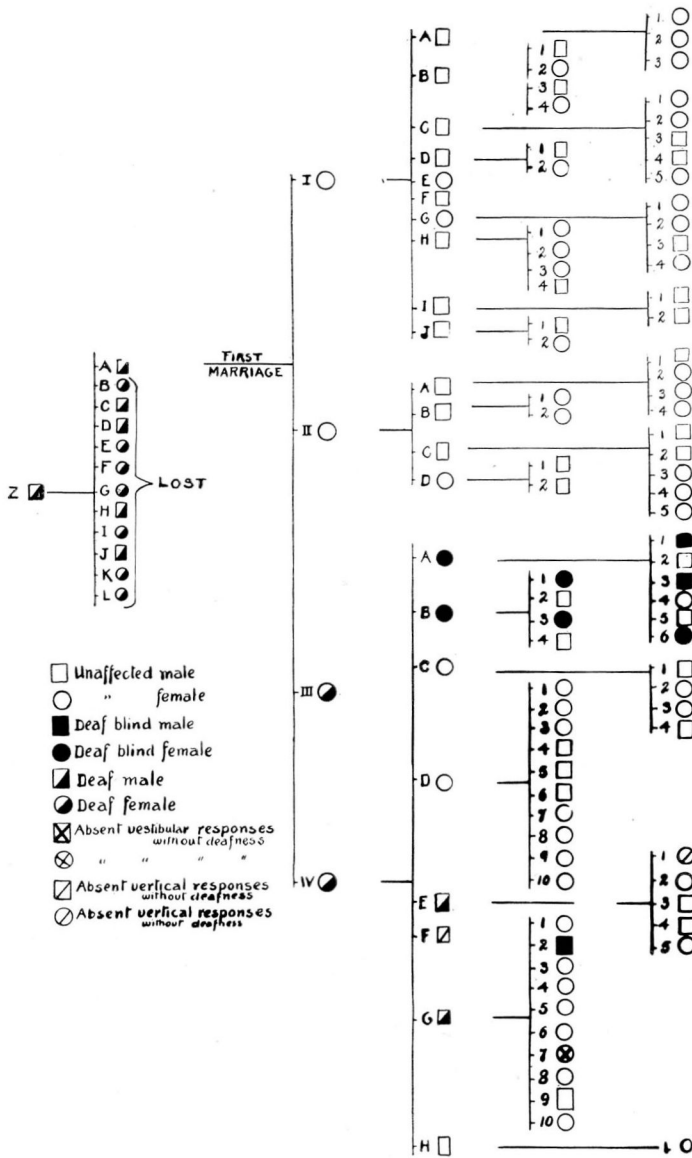


Fig. 6. The first generation is represented by Z, the second by A to L, the third by Roman numerals, the fourth by capital letters, and the fifth by figures. The fifth generation consists of a double column. For the sake of simplicity, the issue of the two marriages of Z A are separated.

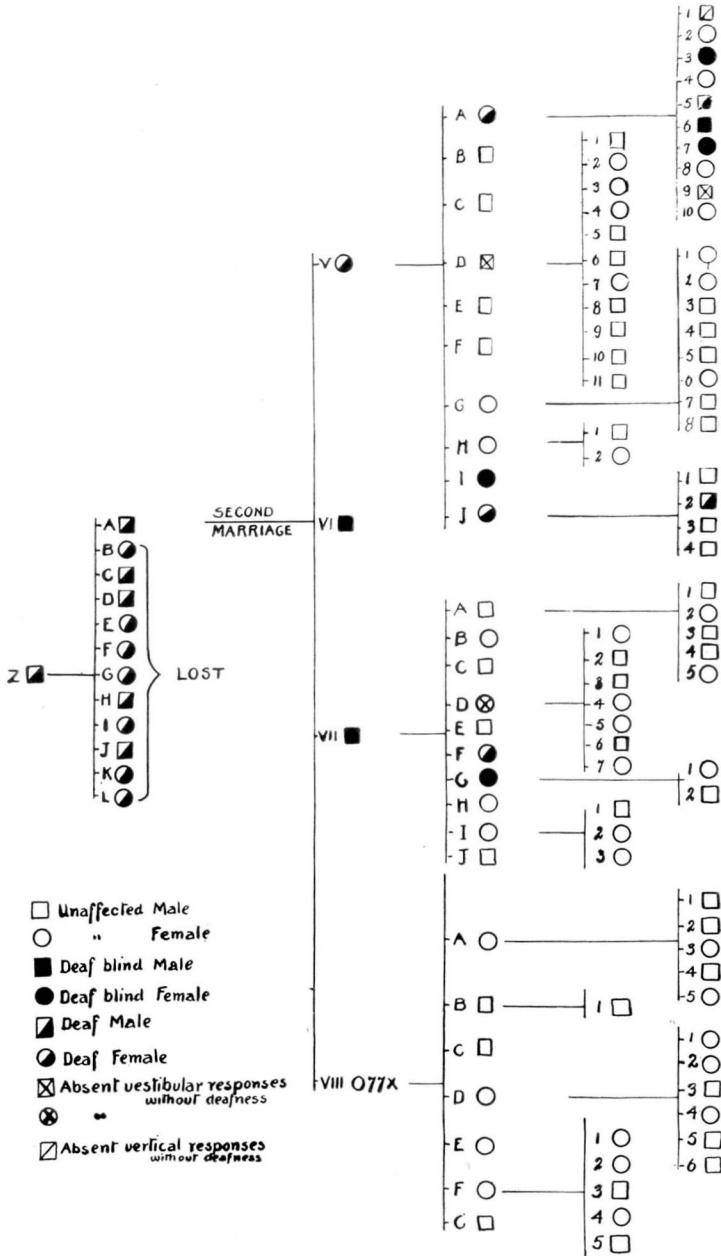


Fig. 7. In this chart, the first two generations seen in Fig. 6 are duplicated.

HEREDITARY DEAFNESS DUE TO TUMORS

This Chart represents the Children of deaf Parents who attained the age of 20 years

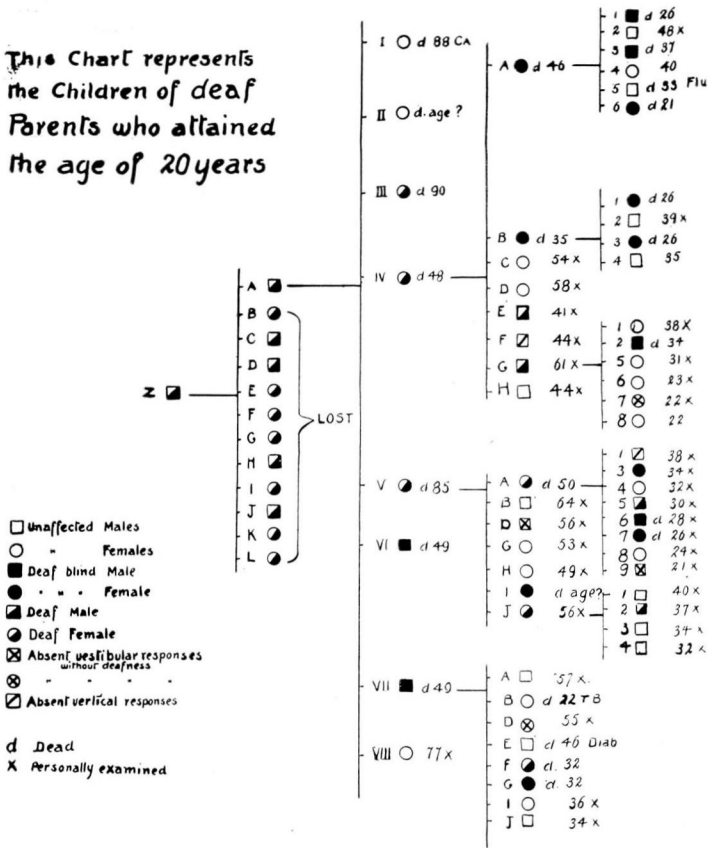


Fig. 8. This chart shows the children of deaf parents who attained the age of twenty years. Only the children of affected parents were affected. The average age at onset of deafness was twenty years.

REFERENCES

- 1 Antoni, N. R. E.: Ueber Ruckenmarkstumoren und Neurofibrome. Munchen, J. F. Bergmann, 1920.
- 2 Von Recklinghausen: Über die multiplen Fibrome der Haut und ihre Beziehung zu den multiplen Neuomen. Berlin, A. Hirschwald, 1882.
- 3 Henschen, F: Zur Histologie und Pathogenese der Kleinhirnbrückenwinkel-tumoren. Arch. f. Psychiat., 56:21, 1915.