

SOLITARY CYSTS OF THE KIDNEY

CHARLES CLAIR HIGGINS, M.D.

Reprinted by permission from ANNALS OF SURGERY, 93:868-879, April, 1931.

Because of the apparent rarity of solitary cysts of the kidney it seems worthwhile to report ten cases from the records of the Cleveland Clinic. I use the term "apparent rarity" because it would appear that solitary cysts of the kidney are of more frequent occurrence than we are led to believe from a review of the literature. As Branch¹ states, solitary cysts of the kidney are rarely observed by the clinician but are frequently observed by the pathologist.

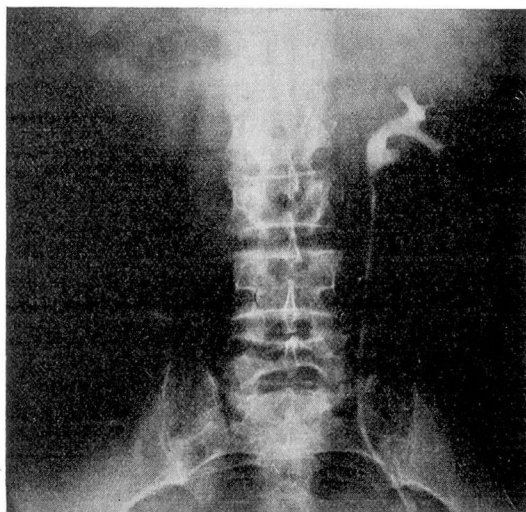


Fig. 1 — Pyelogram showing deformity of calices of kidney due to solitary cyst.

He states further that unless the cysts reach a sufficient size to produce pressure symptoms, they are rarely diagnosed and are found only at autopsy. Branch states that they are present in from 3 to 5 per cent of all autopsies. In five kidneys from thirty-six cadavers, Kampmeier² found cysts which varied from 2.5 to 5 centimetres in diameter. From 2,610 autopsies at the Middlesex Hospital, in London, Morris³ reported five cases of solitary cysts. We have found in the literature reports of 158 cases. The addition of our ten cases brings the total number to 168.

Case I.—The patient was a woman forty years of age who entered the clinic complaining that during the preceding ten years she had suffered from pain in the right side and difficulty in urina-

tion, the latter symptom having followed childbirth. The patient also had a feeling of fulness in the abdomen and an occasional aching pain in the right side. For the preceding few years there had been marked urgency and nocturia. There was no history of hæmaturia.

The physical findings were normal except for a palpable smooth mass in the region of the right kidney. The roentgenogram showed a large round shadow connected to the lower pole of the right kidney.

The first pyelogram was normal, but a later one showed a spherical enlargement below the lower pole of the kidney (fig. I). Blood-pressure was 120/75, red blood count 4,400,000, white blood count 8,750, hæmoglobin 80 per cent, urine normal, Wassermann negative. The pre-operative diagnosis was cyst of the right kidney. At operation a cyst was found at the lower pole of the right kidney. This was removed together with a wedge of renal parenchyma. Convalescence was uneventful.

Case II.—A man, sixty-two years of age, entered the clinic complaining of jaundice which had been increasing in intensity during the preceding few weeks, but was not associated with pain. There was marked pruritus and the stools were clay-colored. For years he had been aware of a mass in the right side of the abdomen which had been diagnosed "ptosed liver." It had not caused pain but only a feeling of fulness.

Physical examination revealed a man in very poor physical condition who was quite jaundiced and acutely ill. In the right kidney region was a large round mass the size of a grapefruit, which was not nodular and was soft in consistency. Pyelography was not thought advisable. The blood-pressure was 140/90. Laboratory findings were as follows: hæmoglobin 80 per cent, red blood count 4,030,000, white blood count 6,950; blood urea 84; blood cholesterol 182; serum bilirubin 3.8 direct; urine—albumin two plus, 2 to 5 pus cells per high-power field, few granular casts; Wassermann negative.

A diagnosis of carcinoma of the head of the pancreas was made and an exploratory operation performed. In addition to carcinoma of the pancreas a large solitary cyst the size of a grapefruit was found at the lower pole of the right kidney. This was aspirated. The patient died a few days later of uræmia.

Case III.—A man, aged seventy-four, entered the clinic complaining of nocturia, frequency, difficulty in voiding, and blood in the urine. Recently he had noted terminal hæmaturia. He was poorly nourished; blood-pressure was 130/80. The only important finding on general and cystoscopic examination was marked enlarge-

ment of the prostate. *Laboratory findings* — Hæmoglobin 85 per cent, red blood count 4,350,000, white blood count 5,800; phenol-sulphonphthalein 40 per cent in two hours; blood urea 57; urine — albumin two plus, red blood cells 20 to 30, and white blood cells 2 to 5 per high-power field; Wassermann negative.

A suprapubic prostatectomy was performed, and the patient died four days later of pneumonia. Post-mortem examination revealed a cyst of the power pole of the right kidney which was filled with light amber-colored serous fluid. Pneumonia was the primary cause of death.

Case IV.— A man, seventy-nine years of age, entered the clinic complaining of difficulty in voiding. Five years ago he had first experienced increasing nocturia and difficulty in starting the stream which had diminished in size; terminal dribbling was quite pronounced. A poorly nourished man showing evidence of considerable loss in weight. Blood-pressure was 120/80. Heart moderately enlarged and a loud systolic blow was heard at the apex. Rectal examination revealed considerable enlargement of the prostate and cystoscopic examination showed marked intravesical projection of the prostate.

A perineal prostatectomy was performed. The patient died five days later of uræmia and pneumonia.

At post-mortem examination a large solitary cyst 18 centimetres in diameter and filled with serous fluid was found on the anterior surface of the upper pole of the right kidney.

Case V.— A man, twenty-four years of age, entered the clinic complaining of pain in the left kidney region which had continued intermittently for the preceding year. These attacks came on suddenly, lasting from ten to fifteen minutes and then subsiding. There was no hæmaturia or passing of gravel. Nothing of significance was found in the physical examination; no tumor mass was palpable. The cystoscopic examination led to the diagnosis of calculous pyonephrosis. *Laboratory findings* — Wassermann negative; blood normal; function test not recorded; urine — numerous pus cells, no red blood cells. A left nephrectomy was performed and in addition to the calculous pyonephrosis a cyst the size of a lemon was found at the lower pole of the kidney. Convalescence was uneventful.

Case VI.— A man, forty-six years of age, entered the clinic complaining of severe attacks of pain over the right kidney from which he had suffered for several years. The pain radiated downward toward the scrotum. There was no history of hæmaturia or passing of gravel. Physical findings were normal except for tenderness on deep pressure over the right kidney. *Laboratory findings* — Wasser-

mann negative, phenolsulphonphthalein 50 per cent in two hours. Urine — trace of albumin, white blood cells 2-4 per high-power field. A cystoscopic examination was done and a diagnosis of calculous pyonephrosis was made from the pyelogram.

A right nephrectomy was performed at which time a large solitary cyst containing clear, serous fluid, was found at the lower pole of the kidney in addition to the calculous pyonephrosis. This cyst was ruptured accidentally while removing the kidney.

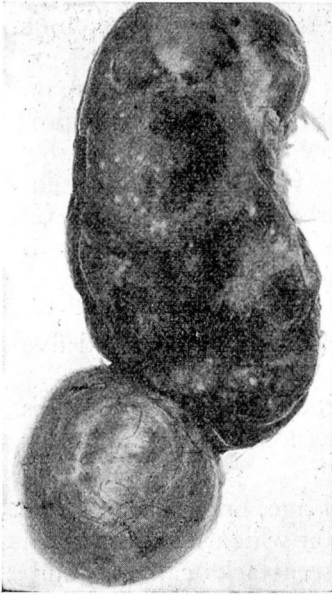

Fig. 2 — Photograph showing a large cyst of the right kidney associated with tuberculosis.

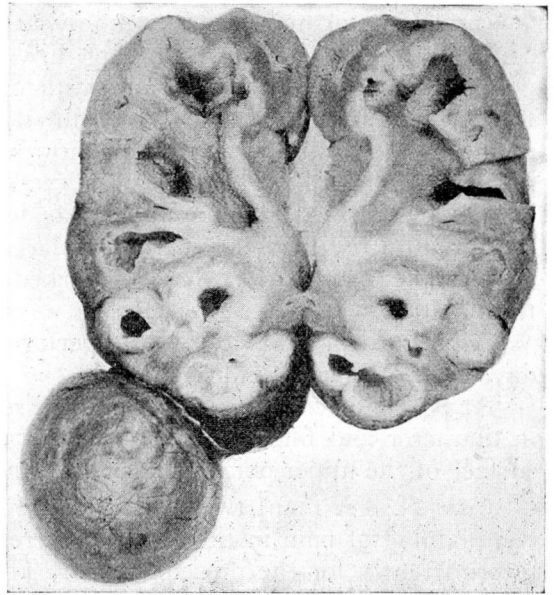


Fig. 3 — Photograph of cut specimen of kidney with cyst attached.

Case VII.— A woman, forty-five years of age, entered the clinic complaining that for six months she had experienced urinary urgency, frequency every fifteen minutes and nocturia ten to twelve times. One month before entering the clinic she had passed a small amount of blood. There was no history of loss in weight. Two weeks previously she had had an attack of pain in the right side accompanied by chills and fever. She was a fairly well-nourished woman showing no evidence of weight loss. The blood-pressure was 130/90. Suprapubic tenderness was present. Vaginal examination revealed a hard, pencil-like, tender lower right ureter. A cysto-

SOLITARY CYSTS OF THE KIDNEY

scopic examination was made and tubercle bacilli were found in the specimen from the right kidney. From the pyelogram a preoperative diagnosis of tuberculosis of the right kidney was made. *Laboratory findings were as follows* — Wassermann negative; hæmoglobin 70 per cent, red blood count 4,420,000, white blood count 7,800; urine — pus two plus, red blood cells 5-10 per high-power field, phenolsulphonphthalein 18 per cent in fifteen minutes.

Nephrectomy was performed. The kidney was found to be tuberculous and a solitary cyst larger than an egg and containing yellowish, clear, serous fluid was found in the lower pole. Convalescence was uneventful. (figs. 2 and 3.)

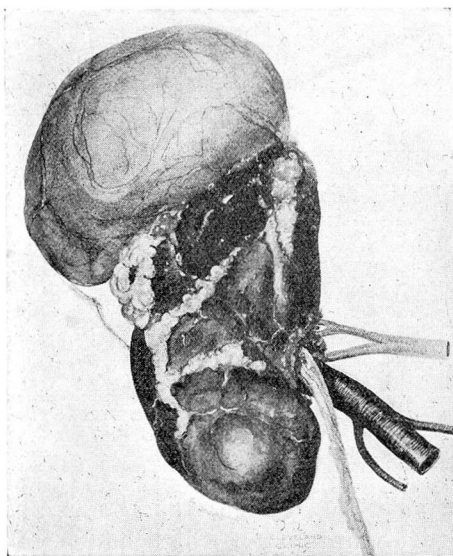
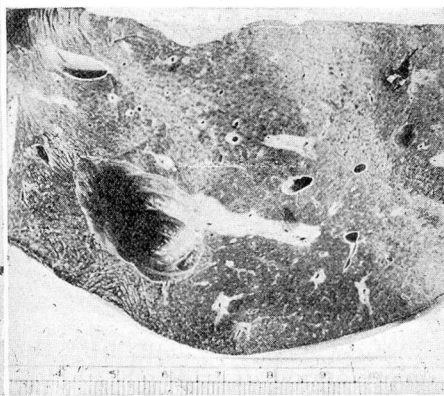


Fig. 4 (left) — Photograph of cyst attached to upper pole of left kidney found post-mortem in a patient who died of lymphatic leukaemia.

Fig. 5 (below) — Photograph of section of liver in which a cyst was found coincidentally with kidney cyst. (See fig. 4.)



Case VIII.— A man, sixty-four years of age, entered the clinic complaining of weakness and loss of weight. His general condition had been very poor for the preceding month and he had lost 20 pounds in weight.

He was very poorly nourished with a generalized glandular adenopathy. Blood-pressure was 124/80. The liver and spleen were both palpable.

Laboratory findings were as follows.— Hæmoglobin 70 per cent, red blood count 3,900,000, white blood count 70,000, smear of blood showed 71 per cent large lymphocytes; urine — albumin one plus, white blood cells two plus; Wassermann negative. A diagnosis of lymphatic leukæmia was made and x-ray therapy was instituted.

The patient died two months later. At post-mortem a large solitary cyst filled with clear, serous fluid was found at the upper pole of the left kidney (fig. 4).

It is interesting to note that a single cyst 3 centimetres in diameter containing clear, serous fluid was also found in the left lobe of the liver (fig. 5). No other cysts were found.

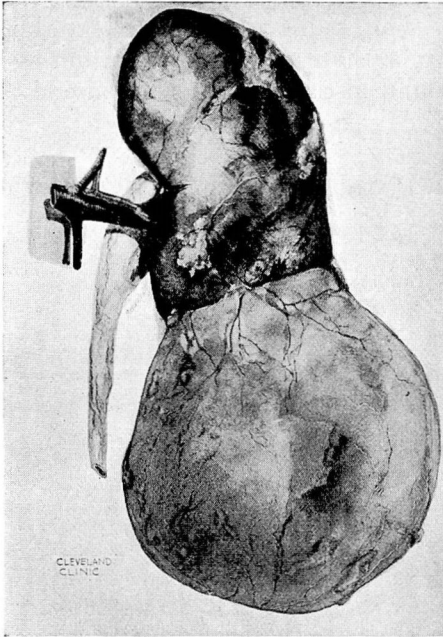

Fig. 6 (left) — Photograph of serous cyst of left kidney.

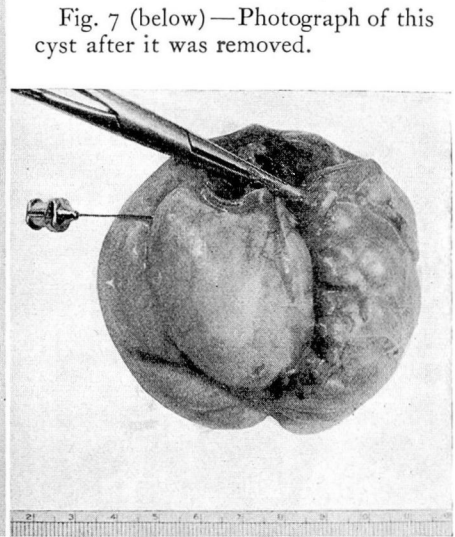


Fig. 7 (below) — Photograph of this cyst after it was removed.

Case IX.— A man, fifty-three years of age, entered the clinic complaining of stomach trouble, the symptoms of which had been present during the preceding two years. During this time he had had more or less constant pain in the left lower quadrant which he described as pulling-down pain. About one year ago he had had an attack of cramp-like pains in the left lower quadrant causing him to double up in agony, and six months previously he had had an acute attack of pain in the lower abdomen accompanied by vomiting.

He was well-nourished. Blood-pressure was 134/80. On physical examination the only finding of significance was a mass to the left of the umbilicus. This mass was round, movable, and not tender. A pyelogram showed a large mass connected with the lower pole of the left kidney. *Laboratory findings* — Red blood count 4,780,000, white blood count 7,800, hæmoglobin 85 per cent; urine normal except for a few pus cells; blood urea 48; phenolsulphonphthalein test showed normal excretion.

SOLITARY CYSTS OF THE KIDNEY

A pre-operative diagnosis of solitary cyst of the lower pole of the left kidney was made. At operation a cyst the size of a small grapefruit was found attached to the lower pole of the left kidney (figs. 6 and 7). This was excised without removing any of the kidney parenchyma. Convalescence was uneventful.

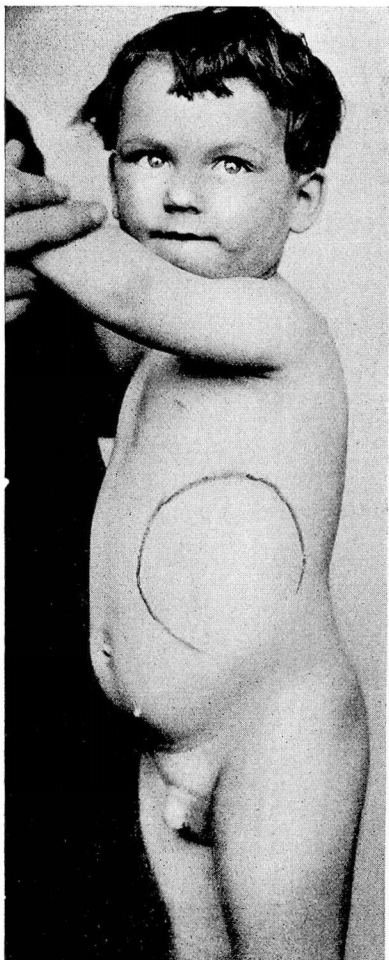


Fig. 8 — Photograph of a boy three years old in whose case a diagnosis of malignant tumor of the kidney was made. Operation disclosed a cyst 13 by 10 by 9 centimetres.

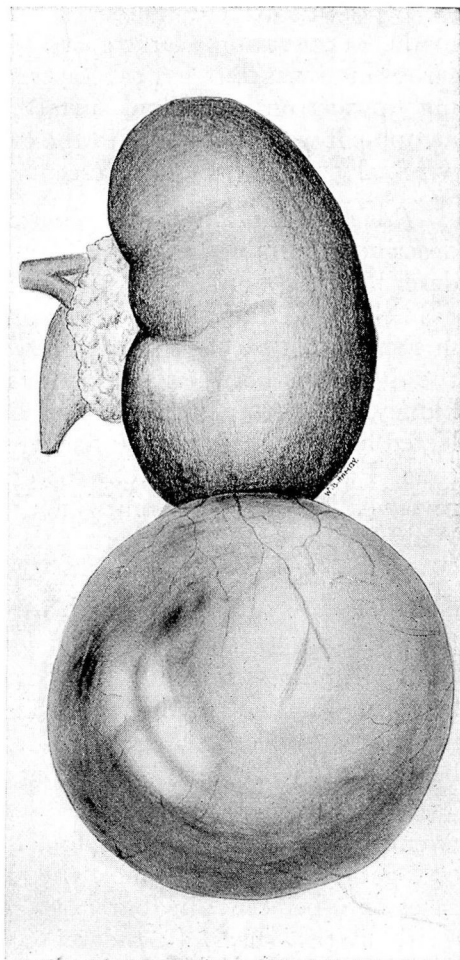


Fig. 9 — Drawing showing a solitary cyst at lower pole of kidney.

Case X.— A boy, three years of age, was brought to the clinic because of an enlargement of the abdomen. He had always been healthy but the abdomen has been protuberant since birth (fig 8).

On physical examination the only significant finding was a large mass the size of a grapefruit in the left hypochondrium. Upon roentgenographic examination this was shown to be a large mass in the region of the left kidney. Kidney function was normal as were the urinary findings. A pyelographic examination was not made.

A pre-operative diagnosis of malignant tumor of the kidney was made. At operation a large cyst 13 by 10 by 9 centimetres filled with serous fluid was found at the lower pole of the left kidney and extending upward on its lateral surface. As the kidney appeared to be atrophic it was removed with the cyst. The kidney and cyst together weighed 570 grams. Convalescence was uneventful.

Review of the Literature.—Solitary cysts of the kidney were first described by Fabry⁴ in 1624. Thomas Willis,⁵ the English clinician, described them in the seventeenth century, and in 1837 Rayer⁶ first classified the various types, this classification being followed in 1876 by an excellent treatise by Lavarán⁷ in which he discussed the difference between solitary cysts of the kidney and polycystic kidney. In a complete review of the literature in 1906, Simon⁸ collected fifty-two cases which had been reported from 1860 up to that time. Later, individual cases were cited and the literature was reviewed by Caulk,⁹ Cunningham,¹⁰ Blanchard,¹¹ Vogel,¹² Beneke,¹³ Wulff,¹⁴ Fowler,¹⁵ and others.

In 1920 Kretschmer¹⁶ again reviewed the literature adding forty-eight cases, including one of his own, to Simon's series, making a total of 100 cases.

McKim and Smith,¹⁷ in 1924, collected 117 cases from the literature, and added three. In the same year Harpster¹⁸ presented ninety-five collected cases, in eighty-two of which an operation had been performed with the following results:

In thirty cases nephrectomy was done followed by recovery in twenty-three cases; in thirty-four cases, resection of the cyst alone, or together with a portion of the kidney, resulted in death in three cases or 9 per cent; in four cases the cyst was tapped followed by death in two cases. In the remaining fourteen cases the type of operation was not stated.

In 1928, Carson¹⁹ collected 126 cases from the literature and added fifteen cases which had been reported between the years 1923 and 1927. These, with four additional cases made a total of 145.

In 1930, Grove²⁰ collected 153 cases from the literature, and added a case, and Kretschmer²¹ recently reported five cases of his own. As we have stated the addition of the ten cases cited in this paper brings the total number up to 168.

SOLITARY CYSTS OF THE KIDNEY

Structure.—The wall of a solitary cyst of the kidney is generally grayish-white in color varying from one to five millimetres in thickness. Calcification is rare but may occur as in the case cited by Kirwin.²² The inner surface is smooth and glistening and fine blood-vessels may be seen coursing through it (fig. 9). The wall of the cyst is independent of the capsule of the kidney, although frequently it is closely adherent to it. Some investigators state that the cyst has no epithelial lining while others describe the presence of a single layer of low, cuboidal epithelium. It has even been stated that the lining consists of normal cell formation of uriniferous tubules which, as the result of pressure, may be flattened.

In our series of cases the cell lining of the cysts varied. In one case the lining consisted of flattened cells separated by rather heavy connective-tissue trabeculae. In another, the cyst wall was composed of fairly dense, fairly well vascularized, simple, fibrous, connective tissue but no epithelial cells were present. If the cyst is large, pressure atrophy may be present in the adjacent kidney tissue.

A cyst usually contains clear, straw-colored, serous fluid, the specific gravity of which is low. Hæmorrhage may take place into the cyst, producing blood clots. In one of our cases the fluid had a distinct odor of urine. Fowler states that the fluid contained in a cyst is clear, watery and albuminous, and does not contain urinary elements unless it communicates with the pelvis or calyces of the kidney, which is not the case as a general rule.

Age Incidence.—Carson states that the majority of cases of solitary cysts of the kidney occur between the ages of thirty and sixty years, the average age being forty-five. Simon also states that the condition occurs most frequently in the fourth and fifth decades. In Kretschmer's review of forty-two collected cases in which the age was stated, thirty-six cases occurred after thirty years of age. The youngest patient was sixteen months old (reported by Albarran and Imbert). In our series, the youngest patient was three years of age and the oldest seventy-nine. The age incidence in our series was as follows:

<i>Age</i>	<i>Number of Cases</i>
3 years.....	1
24 years.....	1
40-50 years.....	3
51-60 years.....	1
61-70 years.....	2
71-80 years.....	2

Sex Incidence.—Of the cases reviewed by O'Neil²³ in the Massachusetts General Hospital, five occurred in men and four in women. Of those reported by Albarran and Imbert²⁴ thirteen occurred in men and ten in women. In Kretschmer's series of cases twenty occurred in men and twenty-two in women, and in our series eight occurred in men and two in women. In Simon's⁸ series, the condition occurred twice as frequently in women as in men. It is also interesting to note that most of the women in which the condition has been present were multiparous. In Carson's¹⁹ series of 146 collected cases, eighty-nine occurred in women, forty-one in men and in sixteen cases the sex was not stated.

Location and Size.—In six of the cases herein reported, the cyst occurred on the right kidney and in four it was found on the left, while in Kretschmer's collected series, in twenty-one cases the cyst occurred on the right and in twenty on the left kidney. Carson has found that the condition occurs more frequently on the right kidney. Solitary cysts of the kidney are usually unilateral although Cunningham and Zaccarini²⁵ reported the occurrence of bilateral cysts. It is well known that small cysts are frequently found on arteriosclerotic kidneys but these are not solitary cysts and should not thus be included in this discussion. In the cases reviewed by McKim and Smith the site of the cyst was as follows:

	<i>Lower pole of kidney</i>	<i>Upper pole of kidney</i>	<i>Center of kidney</i>
McKim and Smith.....	51	21	8
Kretschmer.....	13	11	
Higgins.....	7	3	

Solitary cysts may arise from the upper or lower pole, the anterior surface or the hilus of the kidney. In most of the cases reviewed herein the cyst was present on the lower pole of the kidney.

The cysts vary in size from a few centimetres in diameter to a large sac containing a litre or more of fluid. In one case in our series the cysts contained over a litre of fluid. Since the smaller cysts present no symptoms they are not found by the clinician, and only at autopsy.

Associated Pathology.—In addition to the cyst, various coexisting pathological lesions may be present. In our series a calculous pyonephrosis was present in two cases and caseous tuberculosis in one case. Cunningham reported a case of coexisting renal calculi and also a case of coexisting hypernephroma. Desno cited a case of a solitary cyst which was present in a tuberculous kidney and O'Neil²³ reported a cyst in a horseshoe kidney.

SOLITARY CYSTS OF THE KIDNEY

It is also interesting to note that in case VIII of our series, in addition to the large solitary cyst found in the kidney, a single cyst three centimetres in diameter, containing clear, serous fluid was found in the liver. This was the only other organ in which a cyst was found.

Etiology.— Various theories have been advanced in regard to the etiology of solitary cysts of the kidney. Cunningham¹⁰ states that they are probably due to an obstruction in the uriniferous tubules and to the continued excretion of urine without an outlet.

Kampmeier² states that normally the human foetus passes through a period which is characterized by the presence of numerous cystic renal tubules which if they persist and expand at the expense of the adjacent tissue, may cause a renal cyst. Caulk,⁹ who studied a large series of these cases, stated that although some cysts may be congenital in origin, it seems evident that the majority are due to obstruction. McKim and Smith¹⁷ believe they may be due to mechanical causes, they may be of neoplastic origin, or they may be congenital.

Symptomatology.— Solitary cysts of the kidney do not present any pathognomonic symptoms until they attain sufficient size to produce pressure or until they become palpable. The patient may complain of vague abdominal discomfort, and a sense of fulness, or pain in the region of the kidney. Constipation may be present and urinary symptoms may be entirely absent. Hæmaturia is a rare symptom but it has occurred in cases cited by Caulk,⁹ Cunningham¹⁰ and O'Neil.²³ In our series, hæmaturia was present in one case but this was believed to be due to congestion and enlargement of the prostate. In another case, the patient had had severe attacks of renal colic which were undoubtedly due to the coexisting renal calculi. In a third case marked urinary frequency and dysuria, pyuria and hæmaturia were present but these symptoms were explained by the presence of coexisting renal tuberculosis. Frequently the presence of the tumor is noted by the patient, as in the cases cited by Cunningham,¹⁰ Kretschmer,² Blanchard¹¹ and in one of the cases cited in this paper.

Diagnosis.— Often the condition is not diagnosed prior to operation. Bugbee²⁶ recently made a pre-operative diagnosis of a solitary cyst in the case of palpable tumor of the kidney. The cystoscopic examination and the functional tests gave normal findings. In two of our cases a correct diagnosis was made prior to operation. The presence of hydrops of the gall-bladder, an ovarian cyst or a tumor of the kidney may cause confusion in making a diagnosis. Lesions of the gastro-intestinal tract, however, can be

identified by a complete roentgenographic examination, and cholecystography may be used to eliminate the presence of pathological conditions of the gall-bladder.

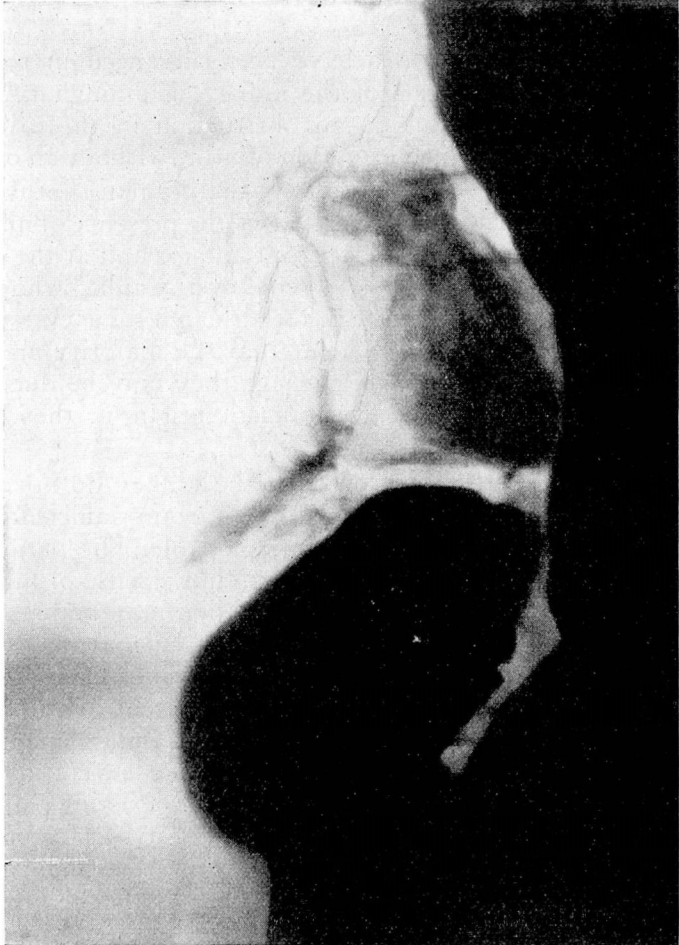

Fig. 10 — Roentgenogram showing pressure deformity of stomach and duodenum due to solitary cyst of kidney.

The roentgenogram may show the outline of the cyst, especially if it arises from the lower pole of the kidney, but cysts of the upper pole are less readily visualized. The margin of the cyst is continuous with the kidney and there may be a difference in density between the cyst and the kidney. A cyst of the upper pole may attain to such a size that its weight forces the kidney downward, producing ectopia, or the ureter may be displaced from its normal position by

SOLITARY CYSTS OF THE KIDNEY

the presence of a cyst on the kidney. A gastro-intestinal study may disclose displacement of the colon, stomach or duodenum by the cyst as was noted in one case in this series (fig. 10).

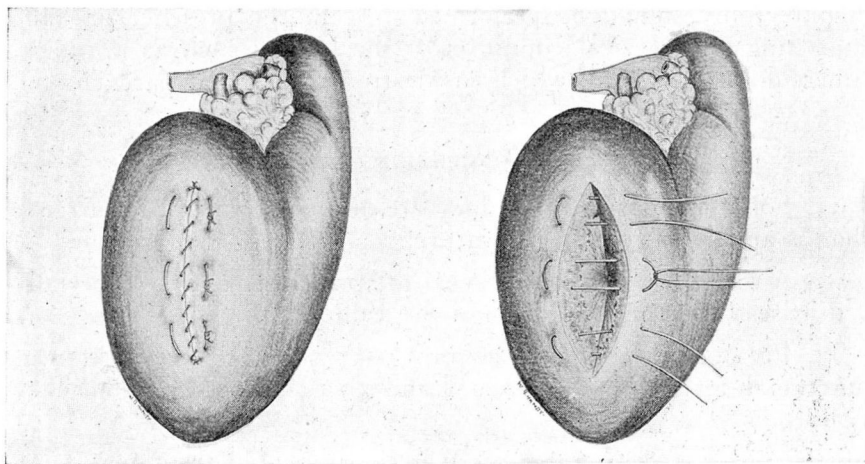


Fig. 11 — Drawing illustrating closure of kidney after removal of cyst.

As the cysts do not communicate with the pelvis or calyces of the kidney the pyelogram may be normal but if the cyst attains sufficient size to bulge into the pelvis a deformity may be shown. The findings from the pyelogram therefore depend upon the size of the cyst, its origin, and the direction in which it grows. In three cases cited by Kretschmer one pyelogram was normal and two were definitely abnormal. Urinalysis and functional tests of the kidney usually give normal findings.

Treatment.— Conservative renal surgery is especially applicable in the treatment of this pathological condition. The extraperitoneal approach naturally is preferable as adequate exposure can thus be secured. It must be remembered that the wall of the cyst is independent of the kidney capsule although adherent to it. In some cases the cyst can be successfully dissected from the kidney without removing a wedge of kidney tissue, as was accomplished in one case of our series. This is certainly the procedure of choice.

It may be necessary to resect a small wedge of kidney tissue along with the cyst in order to remove all the secreting surface of the cyst (Fig. 11). By an adequate kidney incision an excellent exposure is secured, hæmostasis being controlled by holding the kidney pedicle between the fingers. By releasing pressure upon the pedicle of the kidney spurting blood-vessels may be seen and

controlled by catgut sutures. Reapproximation of the wedge-shaped margin of the kidney is accomplished with chromic catgut mattress sutures. Any fatty tissue in the immediate vicinity is then sutured over the incision in the kidney which has been sutured. Nephrectomy should be performed only in the presence of some coexisting pathological condition of the kidney such as a tumor, tuberculosis, or calculi, which has destroyed the renal parenchyma.

CONCLUSIONS

1. Solitary cysts of the kidney are of more frequent occurrence than is apparent from the literature.
2. A roentgenogram may reveal the presence of a cyst, especially if it arises from the lower pole of the kidney.
3. Pre-operatively, a pyclogram may show a normal kidney, functional tests may be normal and there may be no urinary symptoms.
4. Conservative renal surgery is the indicated treatment for a solitary cyst, either by dissection of the cyst away from the kidney tissue or by the removal of the cyst together with a small wedge-shaped portion of the pole of the kidney. This will then allow adequate approximation of the kidney tissue.
5. Nephrectomy should be performed only in the presence of some coexisting renal pathological condition, such as a tumor, tuberculosis, or calculi, if deemed advisable.

REFERENCES

- 1 Branch, C. F.: Some Observations on Solitary Cyst of the Kidney. *J. Urol.*, vol. xxi, pp. 451-453, 1929.
- 2 Kampmeier, O. F.: A Hitherto Unrecognized Mode of Origin of Renal Cysts. *Surg., Gynec. and Obst.*, vol. xxxvi, pp. 208-216, 1923.
- 3 Morris, H.: *Surgical Diseases of the Kidney and Ureter*. Vol. i, p. 631, Cassell & Co., 1923.
- 4 Fabry: Cited by Kirwin, T. J.: Calcified Renal Cyst. *J. Urol.*, vol. xv, pp. 273-288, 1926.
- 5 Willis, T.: Cited by Kirwin, T. J.: Calcified Renal Cyst. *J. Urol.*, vol. xv, pp. 273-288, 1926.
- 6 Rayer, P. F. O.: *Traité des maladies des reins et des altérations de la sécrétion urinaire*. J. B. Baillière, Paris, 1837-1841.
- 7 Lavarán, A.: De la dégénérescence kystique des reins chez l'adulte. *Gaz. hebdomadaire de médecine*, 2s, vol. xiii, pp. 756-776, 1876.
- 8 Simon, J.: Contribution à l'étude des grands kystes séreux du rein. Paris thesis, 1906.

SOLITARY CYSTS OF THE KIDNEY

- 9 Caulk, J. R.: Obstructive Calcareous Papillitis — Retention Cyst of the Kidney. *Tr. Am. A. G. U. Surg.*, vol., vii, pp. 228-256, 1912.
- 10 Cunningham, J. H., Jr.: Large Solitary and Multiple Cysts of the Kidney. *Surg., Gynec. and Obst.*, vol. xxiii, pp. 688-696, December, 1916.
- 11 Blanchard: Cited by Kretschmer, H. L.: Solitary Cysts of the Kidney. *J. Urol.*, vol. iv, pp. 567-583, 1920.
- 12 Vogel, R.: Beitrage zur Nierenchirurgie; 2 Faele von Nierencyste. *Zentralbl. f. chir.*, vol. xxxix, pp. 1540-1544, 1912.
- 13 Beneke: Cited by Kretschmer, H. L.: *Loc. cit.*¹¹
- 14 Wulff, O.: Ueber solitaere von Haematurie begleitete Blutcysten in den Nieren, *Arch. f. Klin. Chir.*, vol. cvi, pp. 689-698, 1915.
- 15 Fowler, R. S.: Simple Serous Cyst of the Kidney. *N. Y. M. J.*, vol. xciv, pp. 1109-1111, 1911.
- 16 Kretschmer, H. L.: Solitary Cysts of the Kidney. *J. Urol.*, vol. iv, pp. 567-583, 1920.
- 17 McKim, G. F., and Smith, P. G.: Solitary Serous Cysts of the Kidney. *J. Urol.*, vol. xii, pp. 635-669, 1924.
- 18 Harpster, C. M., Brown, T. H., and Delcher, A.: Solitary Unilateral Large Serous Cysts of the Kidney. *J. Urol.*, vol. xi, pp. 156-175, 1924.
- 19 Carson, W. J.: Solitary Cysts of the Kidney. *Annals of Surgery*, vol. lxxxvii, pp. 250-256, 1928.
- 20 Grove, J. S.: Solitary Serous Cysts of the Kidney. *J. Urol.*, vol. xxiii, pp. 661-668, 1930.
- 21 Kretschmer, H. L.: Solitary Cyst of the Kidney; Report of Five Cases. *J. A. M. A.*, vol. xcv, pp. 179-182, 1930.
- 22 Kirwin, T. J.: Calcified Renal Cyst. *J. Urol.*, vol. xv, pp. 273-288, 1926.
- 23 O'Neil, R. F.: Solitary Serous Cyst of the Kidney with Report of Recent Case. *J. Urol.*, vol. xiv, pp. 269-273, 1925.
- 24 Albarran, J., and Imbert, L.: *Les tumeurs du rein*, p. 501, Paris, 1903.
- 25 Zaccarini, G.: Die solitaren cystennuren (mikroskopische Beobachtungen). *Deutsche Ztsch. f. Chir.* vol. cxxxii, pp. 295-314, 1915.
- 26 Bugbee, H. G.: Leiomyoma of Kidney; Report of Case. *J. Urol.*, vol. xxi, pp. 363-369, 1929.