

## THE TECHNIC OF THYROID SURGERY

ROBERT S. DINSMORE, M.D.

From the Proceedings of the Interstate Postgraduate Medical Association of North America, October 19 to 23, 1931, pages 41-43.

A discussion of the technic of thyroid surgery obviously precludes any description of preoperative treatment, but it is taken for granted that a careful preoperative regimen has been followed.

A satisfactory technic is one which can be carried out within a reasonable length of time, under some form of light anesthesia or analgesia augmented by local anesthesia, one in which the proper amount of the thyroid gland is removed without injury to the recurrent laryngeal nerve or parathyroid bodies, one in which the result is satisfactory from a cosmetic standpoint, and above all, one which brings about the cure of the patient.

In reviewing the literature on the technic of thyroid surgery, we must conclude that there are many variations of technic all of which fulfill the requisites mentioned above, and that the principles are the same in all, the method varying more or less with the individual operator.

The anesthetic which we use is light analgesia supplemented by local infiltration with three-fourths per cent novocain. The infiltration is carried out in three steps, a small wheal being made intradermally with a fine needle placed at the mid-point of the projected incision line. From this point the novocain is introduced, the skin and subcutaneous tissue being infiltrated over a wide area. No attempt is made to infiltrate beneath the cervical fascia or pre-glandular muscles. It is important that the neck be placed in extension without any rotation of the head.

A transverse incision is made, no attempt being made to make an elliptical one (Richter). For practical purposes the incision is made at a point midway between the episternal notch and the cricoid cartilage.<sup>1</sup> We have found that by this procedure the most satisfactory scar is produced. Generally speaking, the unsatisfactory scars are usually too low rather than too high. If an elliptical incision is made, frequently it is observed after the scar has formed, that the ellipse is much more exaggerated than had been anticipated. The incision is made with the head extended backward and when the neck is again in a normal position the transverse incision will give a slightly curved satisfactory scar.

The incision is carried directly through the skin and subcutaneous tissue across the platysma muscle and down to the cervical

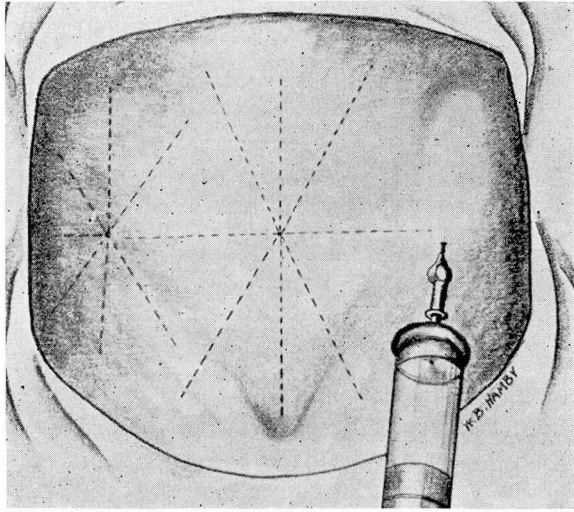


Fig. 1. With the neck in the proper position, three-fourths per cent novocain is injected into the skin and subcutaneous tissue. No attempt is made to inject beneath the fascia at this time.

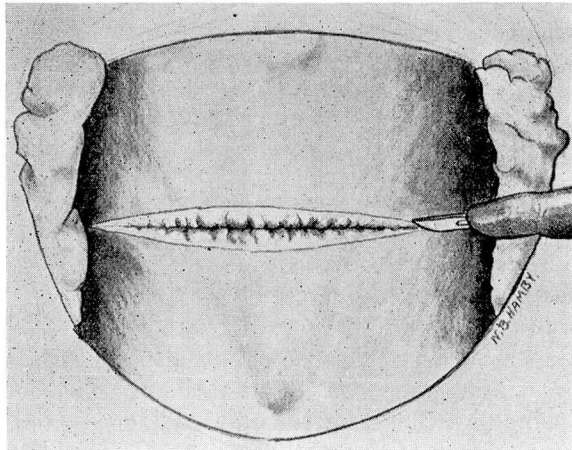


Fig. 2. A straight transverse incision is made across the neck. Dissection is carried through the subcutaneous tissue and platysma muscle down to the cervical fascia, thus giving a full thickness skin flap.

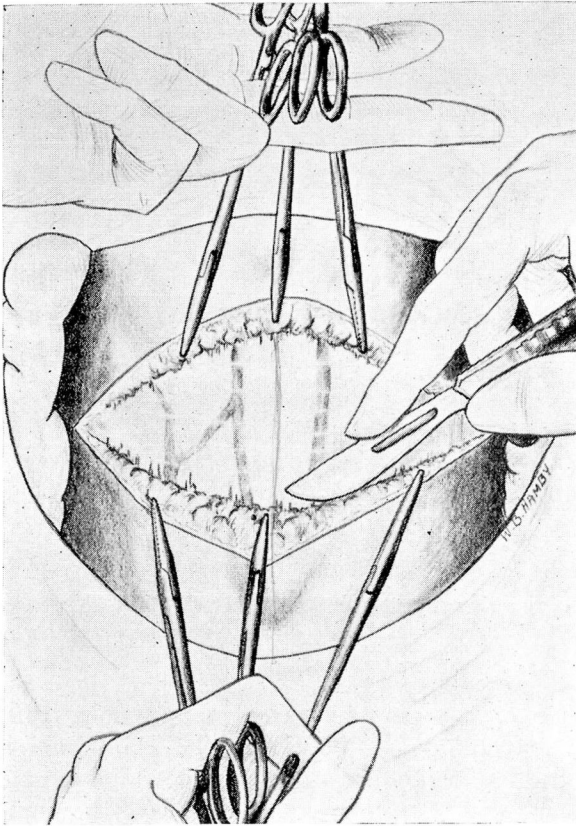


Fig. 3. The skin flaps are dissected upward and downward, below to the episternal notch and above to the level of the cricoid.

fascia, making a full thickness flap. The flaps are then dissected upward and downward, care being taken to carry the dissection down to the episternal notch and upward to the level of the cricoid. It is essential that the dissection be fairly wide as the preglandular muscles are not divided transversely. This latter practice has been discontinued in our Clinic.

After the dissection of the skin flaps, the second step of the infiltration is carried out, the novocain being injected into the immediate cervical fascia, and the preglandular muscles. After the high and low dissection of the skin flaps it is possible to make a long linear incision through the fascia and preglandular muscles, down to the capsule of the gland which is also divided in the same line and the gland exposed. The capsule is then dissected free and as much

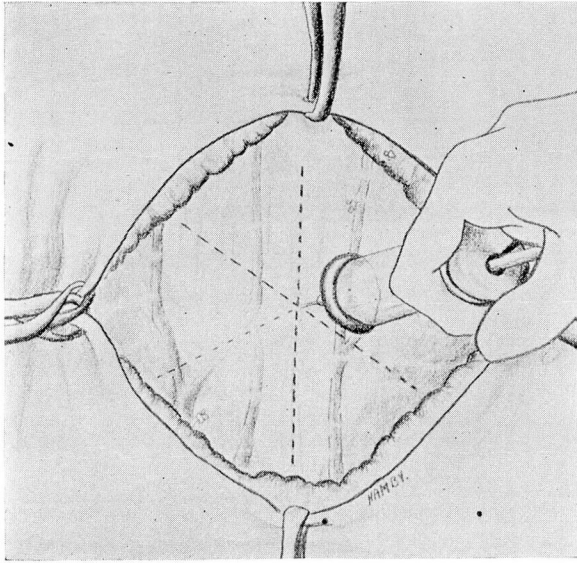


Fig. 4. After the dissection of the skin flaps, three-fourths per cent novocain is injected beneath the cervical fascia and into the preglandular muscles.

of the surface of the gland exposed as possible. We have tried various sorts of clamps for elevating the gland and have finally resorted to the use of hemostats, three of which usually are used. They are placed just within the true capsule of the gland.

The third step of the anesthesia is the infiltration of the gland itself with novocain. Ordinarily this infiltration can be carried out with from 10 to 15 cc. of novocain the greater portion of which is injected into the superior pole. After the gland has been exposed and infiltrated it can then be lifted up and the superior pole exposed. I prefer to remove the right lobe first, but here again this is simply a matter of personal choice.

Two clamps are placed on the superior pole after it has been lifted up and it is absolutely certain that the upper pole is free from the fascia connecting it with the larynx. Pemberton is always careful of this point and places his index finger beneath the superior pole. This is an important step because the clamps must be applied always from within outward. If the clamps are applied from the outside of the gland it is easy to pass by it and catch the terminal branch of the recurrent laryngeal nerve as it passes into the larynx. This observation is not a theoretical one as I have been unfortunate enough to see it demonstrated in the autopsy room. It is quite true

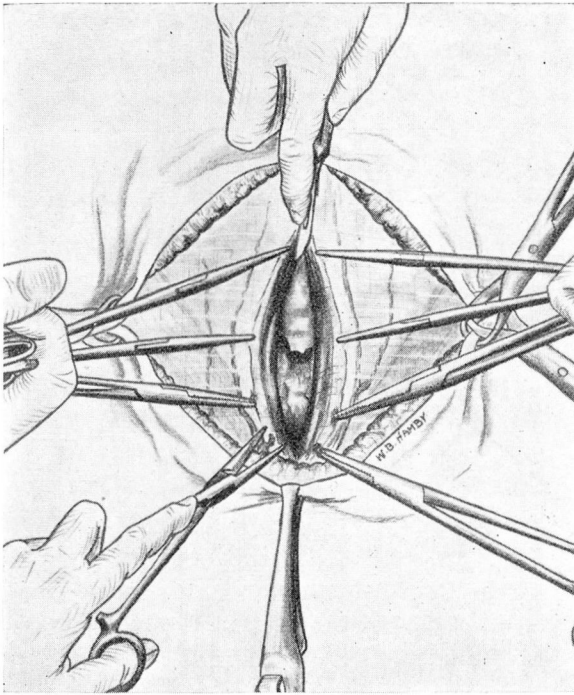


Fig. 5. A longitudinal incision is made through the fascia, pre-glandular muscles and the capsule of the gland. This dissection is carried from the level of the cricoid well down into the episternal notch. With a long incision it is not necessary to divide the pre-glandular muscles transversely.

that the upper pole is not always directly opposite the larynx but in the majority of instances this is an anatomical finding.

A second hemostat is then applied to the lateral vein of the thyroid which is ordinarily at the outer surface at the juncture of the middle and lower thirds of the gland. Hertzler<sup>2</sup> considers this one of the important steps in any thyroidectomy, stating that the line of cleavage is often lost at this point because of the fact that the fascia planes divide here, one sheath going over the carotid and the other to the gland. Guthrie routinely ligates this vessel first. The third clamp is then applied at the inferior pole. I have always made it a point to leave some thyroid tissue at the inferior pole, and I prefer to place the clamp in such a position that after it has been applied it will stand erect in the wound. I think that a great deal of the difficulty with bleeding which is encountered in thyroid surgery can be lessened if these three pilot hemostats are consecutively applied. The poles and the lateral thyroid fascia can then be divided

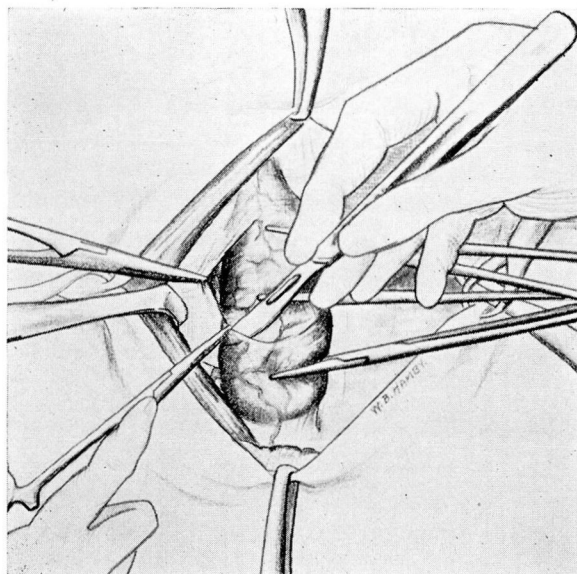


Fig. 6. The capsule of the gland is dissected cleanly from its surface laterally to the level at which the gland is to be divided. None of the capsule is removed.

and an incision made through the lateral posterior border at the point at which the gland is to be divided. This incision can then be carried in for a short distance, approximately one centimeter. After this has been done it will be noted that the gland can easily be lifted forward. From this point the gland is turned outward and the dissection carried from the tracheal side. Sistrunk always advocated this procedure and it has been a great help to me. The clamps can now be placed nearly transversely above the trachea and the dissection carried from that point outward. This procedure does away with the difficulty of placing the clamps down along the side of the trachea which is directly along the tracheo-esophageal groove and is a common site for injury to the recurrent laryngeal nerve.

After the gland has been removed, the tissues are ligated with fine catgut ties. I think it is important that as little sewing as possible be done in the ligation of these tissues as I have seen needles passed around them. In one instance, I was unfortunate enough to pass a needle through the recurrent laryngeal nerve on the right side in the case of one of my own patients in whom a massive collapse of the lung developed on the same side, and death resulted.

## THYROID SURGERY

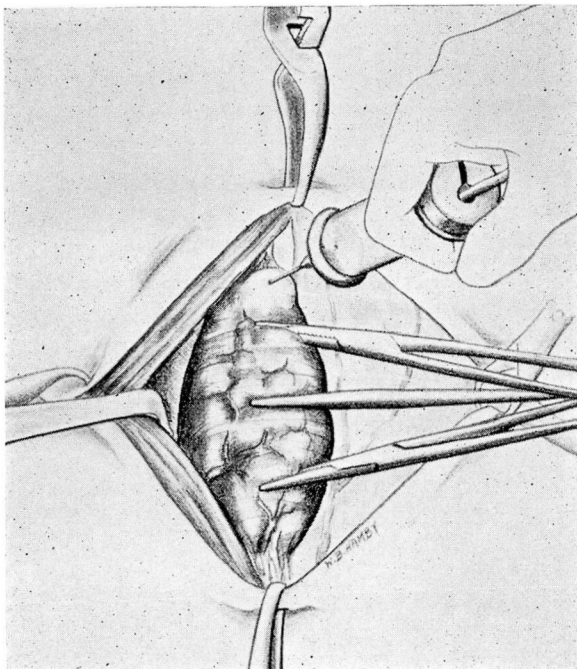


Fig. 7. After the gland has been exposed the third infiltration is made; usually 10 to 15 c. c. of three-fourths per cent novocain injected into the upper pole will suffice.

I prefer to ligate the upper pole with a double catgut suture, inserting it from the same direction as that in which the clamps were applied, that is, from within outward. After the hemostasis is complete the same procedure is carried out on the opposite side. After the ligation has been completed on the opposite side the wound is carefully inspected and the patient asked to cough in order to make sure that the ligatures have been accurately applied. It has been our practice routinely to place a small rubber tissue drain or a small tube in the wound. Recently I have been using a Y-tube the ends of which project into the cavities caused by the removal of the lobes.

An accurate closure following a thyroidectomy is of the utmost importance. One of the most distressing complications is an adherent scar or a small adhesion, which moves with swallowing. This is uncomfortable for the patient and is always noticed by his friends. I have dissected out a fairly large number of these post-operative adhesions and in most instances I have found that they

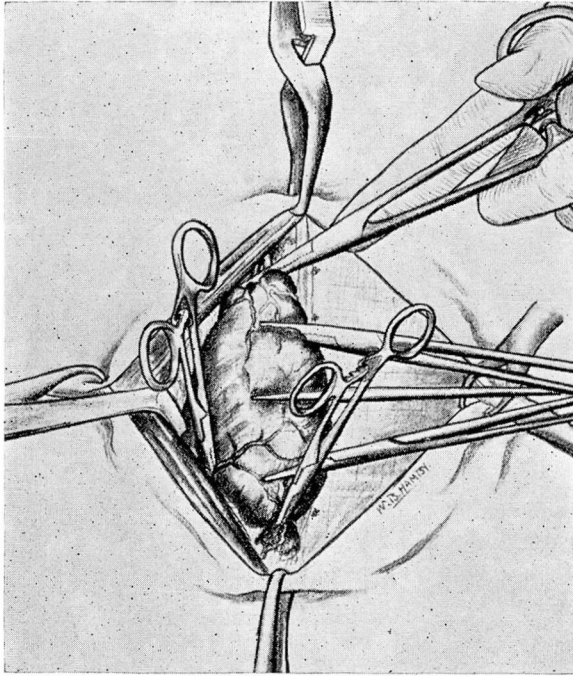


Fig. 8. After the clamps have been placed in the gland for traction, three pilot hemostats are applied. The upper pole is dissected free and lifted up, the hemostat always being directed from within outward. The lateral thyroid vessels are caught with the second hemostat. The inferior pole is then caught, the clamp being applied so as to take some thyroid tissue with it and to have the clamp standing erect.

are caused by a retraction of the preglandular muscles. After dissecting down to the cervical fascia I have found the fascia to be adherent to the trachea, the muscles having retracted. The correction of this condition is not a simple procedure as a very much wider dissection may be necessary than one would suppose in order to get the muscle and fascial layers again in approximation. All layers are closed separately. Interrupted sutures are placed in the capsule of the gland and the preglandular muscles are then approximated with fine catgut sutures and the fascia is closed with a running suture of fine catgut, a small opening being left near the lower angle of the wound for the insertion of a drain. No effort is made to close the platysma, but the full thickness flaps are closed with skin clips. If a satisfactory scar is to be obtained with skin clips it is quite important that they be placed accurately and inserted directly over the incision line and at right angles to it. It is a very common error to apply these clips from the side so that they appear



## THYROID SURGERY

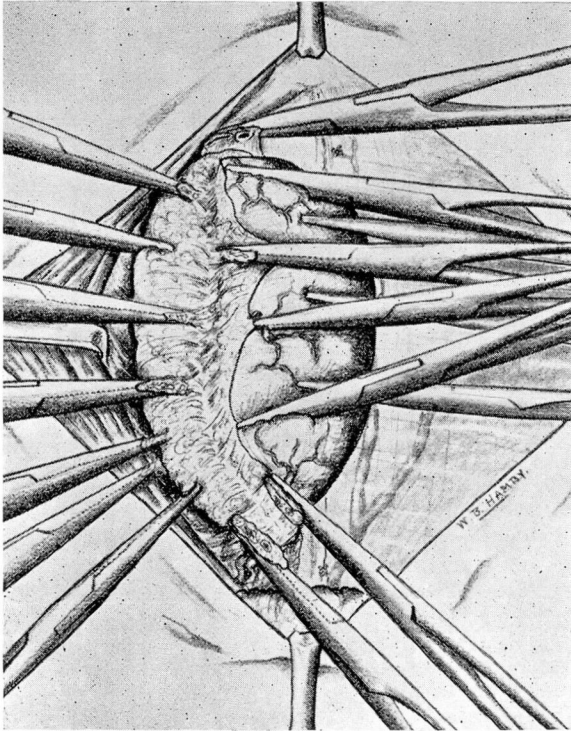


Fig. 9. After the points within the primary clamps have been divided, the dissection is begun from the outside of the gland and carried inward for about one-third of the extent of the gland.

at many different angles when the incision line is completely closed. The clips should not be applied too tightly and should always be removed in from forty-eight to seventy-two hours to prevent the formation of small scars which may result if the clips are left in place too long.

In my own hands, the technic described above has been the one in which I have seen the smallest number of injuries to the recurrent laryngeal nerve. The most common sites for injury of this type have been the superior pole, the inferior pole, and tracheo-esophageal groove at about the middle point between the level of the inferior and superior poles. If the superior pole is free and the clamps are inserted from within outward I believe that the injury at the upper pole is of rare occurrence. Injury at the inferior pole is also rare if the hemostats are kept within the gland.

After the gland has been divided at both poles and another incision has been made through the posterior lateral border and the

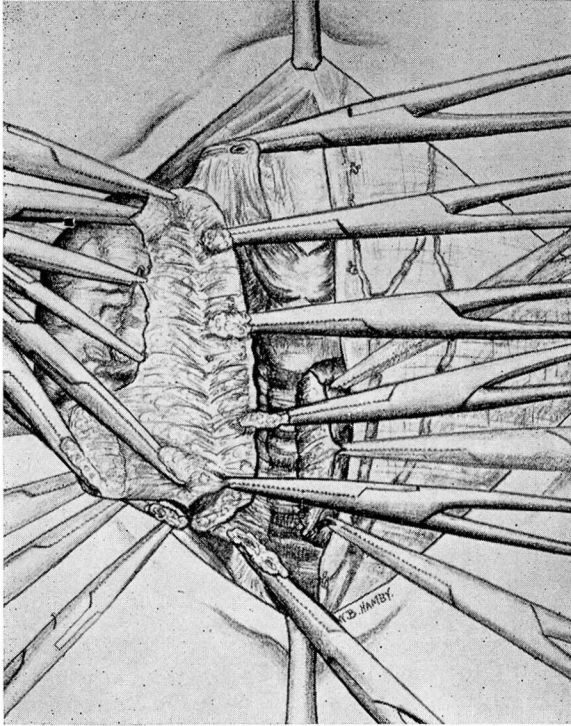


Fig. 10. After the superior pole, the lateral veins and inferior pole have been divided and the lateral incision into the gland substance has been made, the gland is turned outward and the isthmus divided. The gland can then be lifted well forward, and the clamps applied nearly transversely, that is, away from the tracheo-esophageal groove.

gland has been lifted up, the dissection can be carried across the gland in such a manner that a triangular piece of thyroid tissue is always left covering the tracheo-esophageal groove. I do not believe that this can be prevented by complete removal of the gland from the outside inward as it is very easy to rotate the trachea forward, in which case it will suddenly be found that a great deal of thyroid tissue along the lateral surface of the trachea has been removed, and there are small bleeding vessels almost in line with the recurrent laryngeal nerve.

Anatomical studies have shown that the most constant site of the superior parathyroids, is in the posterior capsule of the thyroid gland at the juncture of the upper and middle thirds. The inferior parathyroids lie usually at the juncture of the middle and lower thirds but their location is not so constant as that of the superior

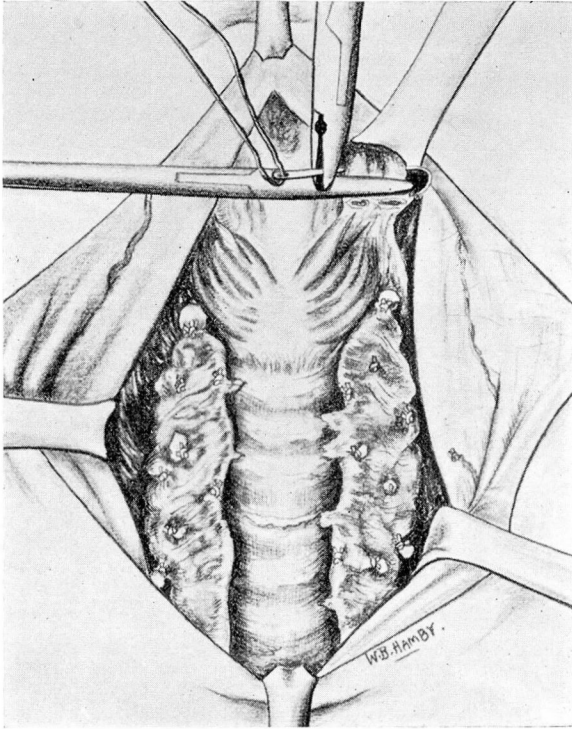


Fig. 11. The upper pole is ligated with a double catgut ligature. The pole is lifted up and the ligature always passed from within outward.

parathyroids. Millzner,<sup>3</sup> Lahey,<sup>4</sup> Terry and Searls<sup>5</sup> have called our attention to the fairly high incidence of the removal of parathyroid bodies which lie on the anterior surface of the gland. This observation coincides with our experience in this Clinic. Graham states that the most common site of parathyroid bodies found in pathological specimens is the lateral inferior border of the gland. Lahey,<sup>4</sup> Searls and Terry<sup>5</sup> have advised the routine search for the parathyroid glands and re-implantation of them if possible.

We have had no experience with the radio knife, although Jackson,<sup>6</sup> Mock,<sup>7</sup> Tinker,<sup>8</sup> and Bartlett and Bartlett<sup>9</sup> have used it. Jackson<sup>6</sup> has summarized the advantages and disadvantages of the procedure, the chief advantages being the time-saving factor, better hemostasis, and less catgut in the wound. He points out that it is especially advantageous in operations on hyperplastic glands and in malignancies of the thyroid. He has pointed out that the radio knife should never be used for the skin incision or near the skin as

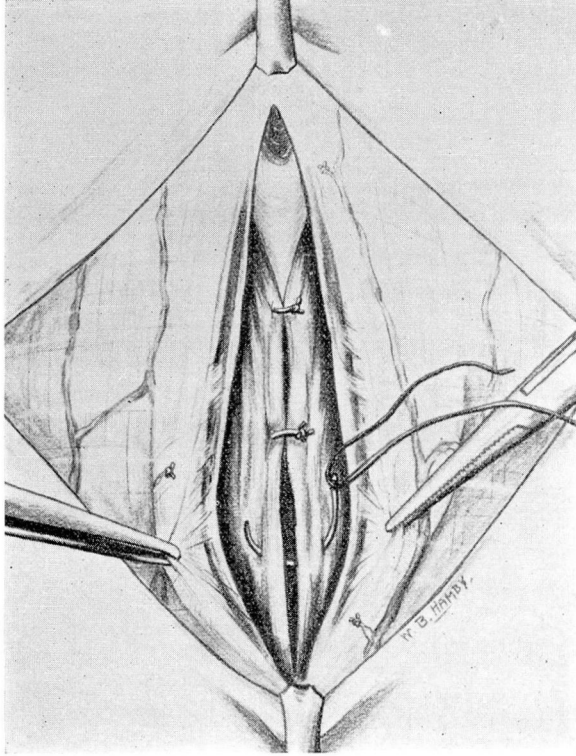


Fig. 12. The capsule is closed with interrupted sutures of fine catgut.

necrosis may result. He feels that it increases the danger of post-operative hemorrhage and that it is of no particular advantage in the case of large adenomatous goiters.

Donald Guthrie has made a very pertinent statement in which he says: "One can never afford, even though his experience in thyroid surgery becomes large, to be careless or rough in his operations upon the thyroid gland, nor can he disregard the importance of meticulous postoperative care, for it is attention to these details in the management of goiter patients that spells success."

## THYROID SURGERY

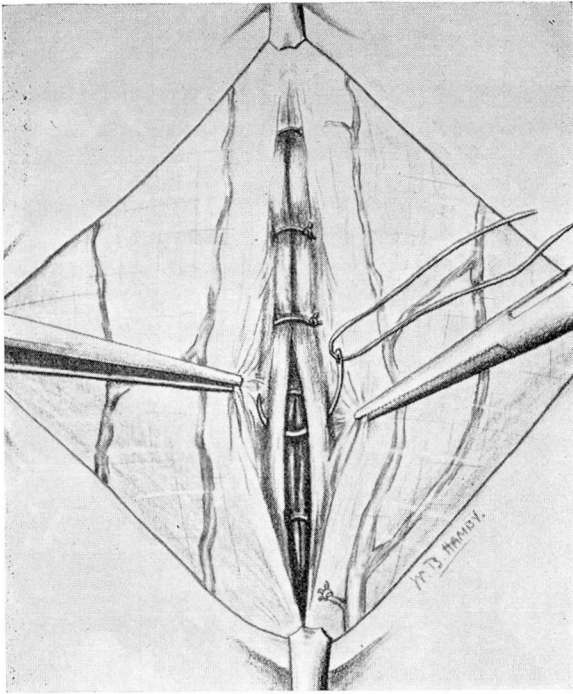
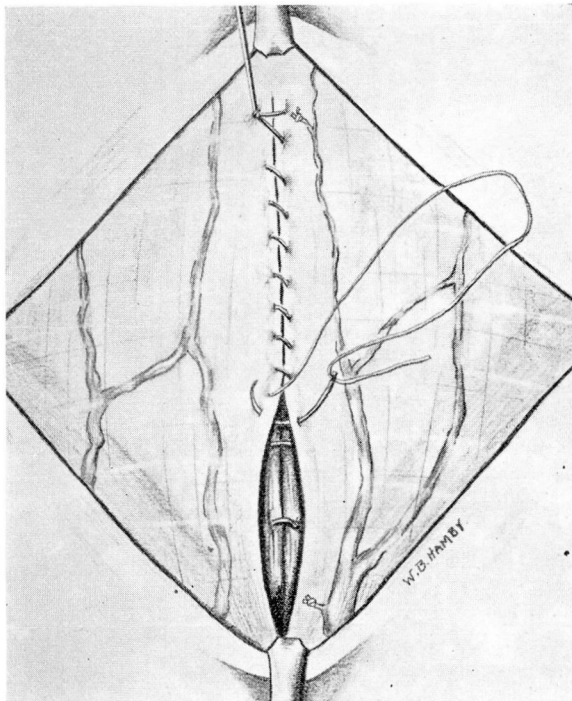


Fig. 13. The preglan-  
dular muscles are closed  
with interrupted sutures.

Fig. 14. The fascia is  
closed with a fine catgut  
running suture leaving a  
small opening in the  
lower third for the drain.



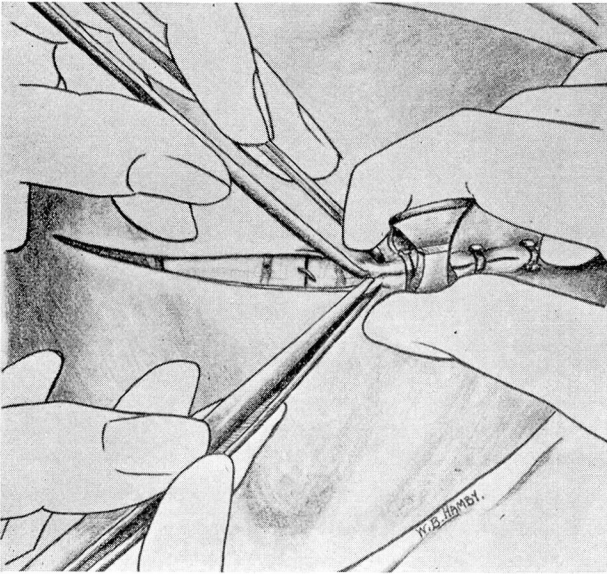
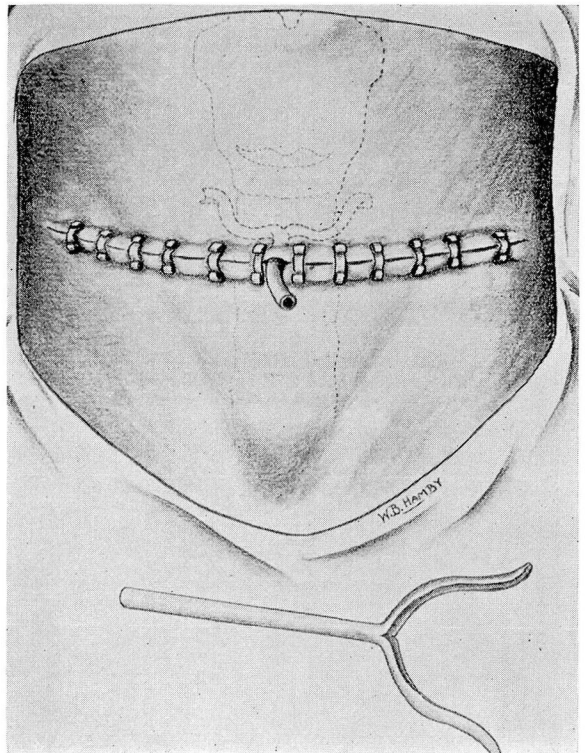


Fig. 15. If clips are used for the skin it is essential that they be inserted at right angles to the incision line. To accomplish this they must be applied from directly above the incision and not from the side, as this invariably leads to a twisting of the clip.

Fig. 16. The wound is drained with a small moulded rubber drain which is removed in from twelve to twenty-four hours.



## THYROID SURGERY

### REFERENCES

- 1 Richter, H. M.: Thyroidectomy. *Surg., Gynec. and Obst.*, 49:67-75, July, 1929.
- 2 Hertzler, A. E.: Technique for Thyroidectomy. *Surg., Gynec. and Obst.*, 47:225-234, 1928.
- 3 Millzner, R. J.: The Occurrence of Parathyroids on the Anterior Surface of the Thyroid Gland. *J.A.M.A.*, 88:1053-1055, 1927.
- 4 Lahey, F. H.: Transplantation of Parathyroids in Partial Thyroidectomy. *Surg., Gynec. and Obst.*, 42:508-509, 1926.
- 5 Terry, W. I., and Searls, H. H.: Parathyroid Preservation. *J.A.M.A.*, 89:966-967, September 17, 1927.
- 6 Jackson, Arnold S.: Thyroidectomy Performed with the Radio-Knife (Conclusions based on 160 operations). *Annals of Surgery*, 93:1132-1136, June, 1931.
- 7 Mock, H. E.: Electrosurgery in Thyroidectomy. *J.A.M.A.*, 84:1365-1368, 1930.
- 8 Tinker, M. B.: Electrosurgery in Goiter Operations. *Surg., Gynec. and Obst.*, 52:508-510, 1931.
- 9 Bartlett, W., and Bartlett, W., Jr.: A Concept of Thyroidectomy Technique of Today. *Surg., Gynec. and Obst.*, 52:855-862, 1931.
- 10 Guthrie, D.: Thyroidectomy Technique; The Post-Operative Care of the Toxic Goiter Patient. *Am. J. Surg.*, 6:631-633, 1929.