

DISEASES OF THE LARGE INTESTINE

C. C. McCCLURE

Reprinted by special permission from THE ARCHIVES OF SURGERY, 24:411-425, March, 1932.

Diseases and abnormalities of the large intestine are far too numerous to be described in one paper; I shall discuss, therefore, only the more common conditions that may be encountered in the routine examination of the gastro-intestinal tract.

The normal contour and position of the colon, as well as many of the abnormal positions that it may assume, are familiar to all physicians. It may not be so well known, however, that a transverse colon that crosses the upper part of the abdomen is more or less rare. In the majority of cases, one finds that the colon falls well below the umbilicus, and it is not unusual to find a transverse colon with its midpoint below the urinary bladder. In many cases the rotation of the colon is incomplete; frequently the embryonic stage is not fully resolved. The normal sigmoid flexure is generally from 16 to 17 inches long (40.6 to 43.1 cm.), but this length may vary, a redundant sigmoid sometimes being several feet in length. Doubtless some cases of obstipation are due entirely to this redundancy. The dilated colon, also, is often a source of difficulty. At the present time, extensive work is being done in an effort to prove that, in some cases at least, colonic stasis is directly responsible for arthritis, stasis being apt to occur, of course, when the colon is dilated, spastic or redundant. The intestinal activity is accelerated in the presence of hyperthyroidism, and diarrhea may be expected to occur; conversely, hyperthyroidism is held responsible for hypomotility of the intestines, with its accompanying symptoms of constipation and toxemia.

SPASTIC COLITIS

The etiology of spastic colitis has not been ascertained, although many theories have been advanced to account for the syndrome designated by this name; some writers even argue that it is not a definite condition, and many competent clinicians ignore its existence completely. It is my belief that spasticity of the colon is a real entity and one that can be definitely demonstrated. In the majority of cases, the condition does not become serious, although at times it causes alarming symptoms which may be readily misinterpreted. This misinterpretation occurred, in fact, in two cases that recently came under my observation.

In one of these cases the roentgenogram showed a constant filling defect in the sigmoid flexure. At operation, the only finding was spasticity in the area of the roentgenographic deformity. In the other case the same principle was illustrated, although the spastic area was not in the colon. All the cardinal symptoms of complete intestinal obstruction were present in the latter case, and

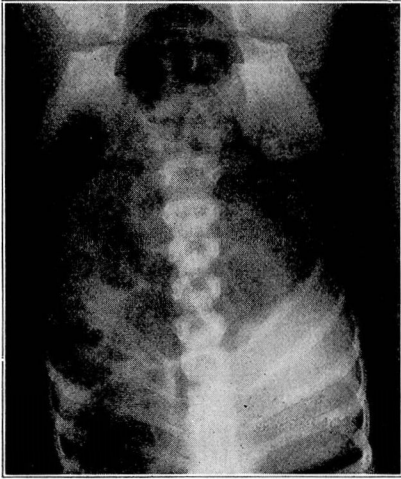


FIG. 1

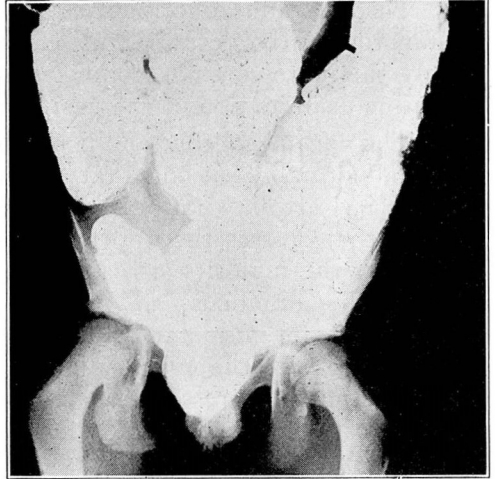


FIG. 2

Fig. 1.—Roentgenogram illustrating a case of stone in the appendix of a child. This was a retrocecal appendix that had ruptured. The arrow points to the stone.

Fig. 2.—Megacolon in a child. Note that the colon almost entirely fills the abdomen.

consequently an operation was performed. The patient died on the operating table, and at autopsy a spastic area in the jejunum was disclosed. Had a test been made with atropine or some other anti-spasmodic, doubtless an operation would not have been performed and the patient would still be alive.

Spastic colitis is a functional condition that may give rise to numerous symptoms, the most common of which are constipation, flatulence, abdominal malaise and pain (either localized or general). If the spasticity persists, it may lead to an inflammatory change with its accompanying symptoms. Since constipation is the most constant symptom, it is surprising to learn that often there is marked colonic hypermotility, the head of the barium meal reaching the rectum in a few hours. This is not difficult to understand, however, in view of the mechanism that causes spastic colitis. According to Gauss,¹ several theories have been advanced to explain hypertonicity. Among these theories are those of an unstable

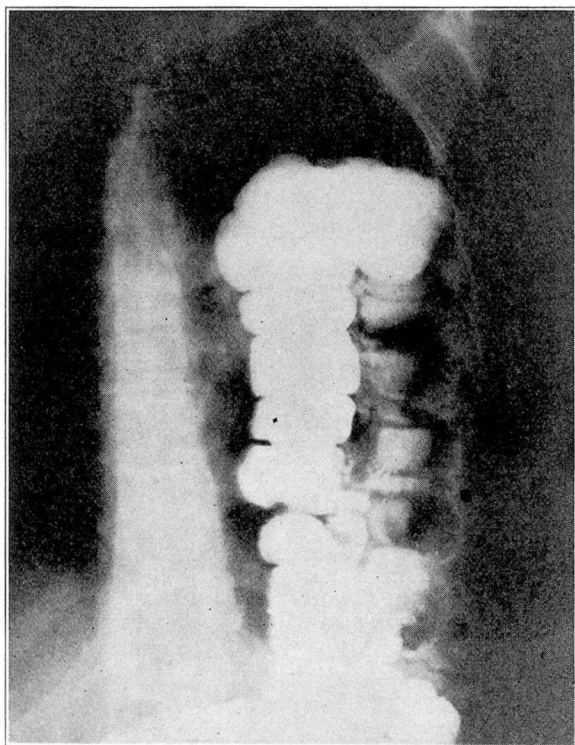


Fig. 3.—Roentgenogram showing a portion of the colon herniated high into the left pulmonic field.

nervous system, a submerged fear complex acquired in early life and an inherited spasmophilic tendency. "The direct etiologic factor is an open problem today. Nevertheless, it has been observed that usually the patient with a spastic colon is a neurotic individual given to introspection, and that the hypertonicity of the colon is a local manifestation of a general spasmophilic tendency." Spasticity, no doubt, is the underlying cause, this being due to a variable degree of reflex contraction of the smooth muscle fibers.

ULCERATIVE COLITIS

It is probable that ulcerative colitis is caused by an infection that has been superimposed on tissues the resistance of which has been lowered as the result of a predisposing condition, such as long-standing catarrhal inflammation of the bowel or severe spasticity of the colon. The ulcerations vary greatly in size, some being only as large as a pinhead while others completely surround the lumen of the colon. Some ulcerations may be very superficial, becoming

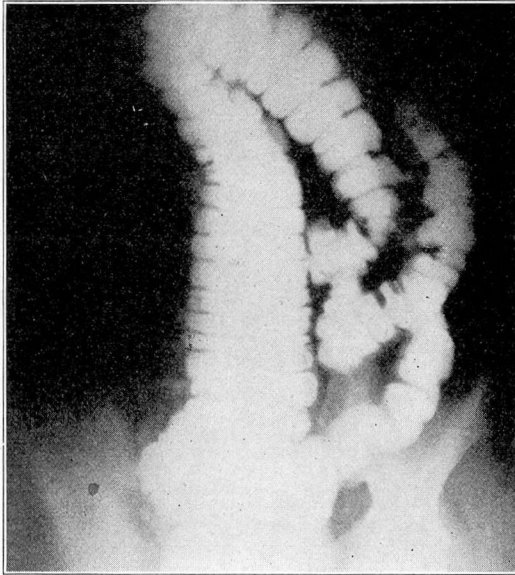


Fig. 4.—Roentgenogram showing an abnormal position of the proximal colon. Scarcely any of the colon is seen to the right of the midline. The cecum and appendix are low in the pelvis.

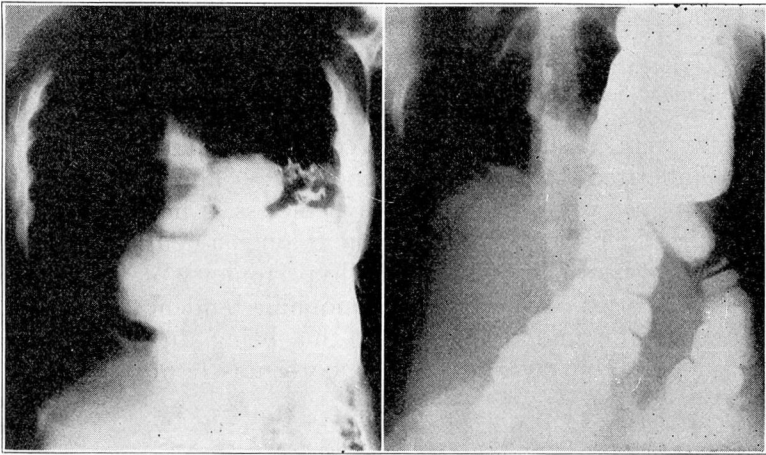


Fig. 5.—Roentgenograms showing hernia of the diaphragm on the left. completely healed in a few days, while others may extend to the muscular coat or may even penetrate the wall of the colon and involve the peritoneum.

The disease is apt to be sudden in its onset, with lancinating pains over the course of the colon, accompanied by griping and

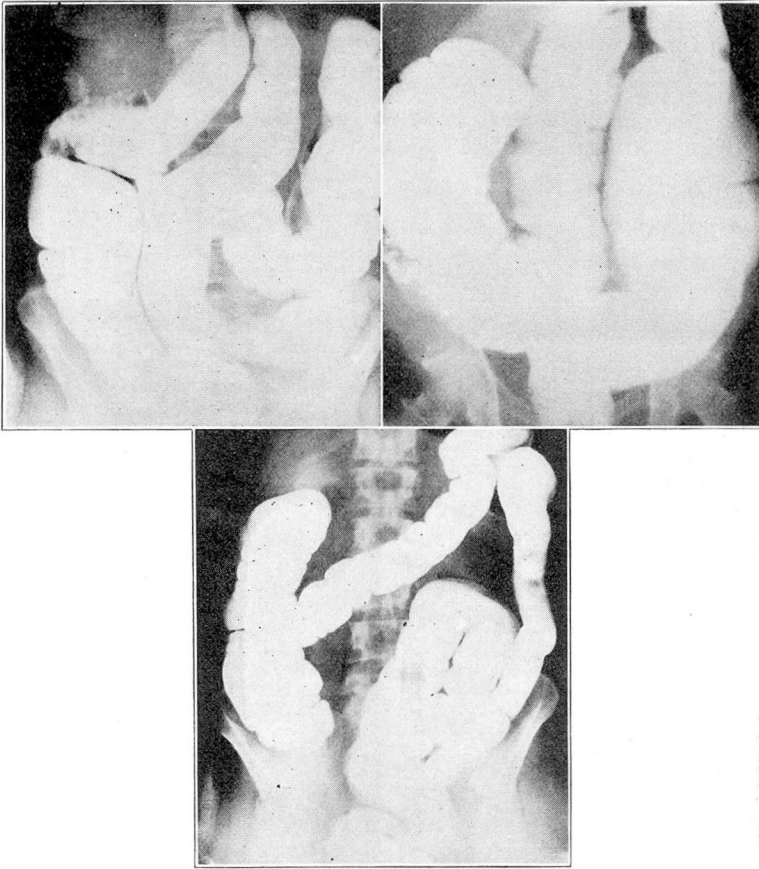


Fig. 6.—Roentgenograms showing varying degrees of redundant sigmoid.

frequent bowel movements. There are severe constitutional disturbances, and in those cases in which the disease is progressive, despite treatment, the resulting mental condition parallels the effect of the toxemia on the nervous system. These attacks occur in cycles, and between them the patient has complete comfort. After a few attacks, mucus, pus and blood are passed, and in severe cases the condition of the patient is distressing.

Ulcerative colitis may be confused with dysentery, typhoid fever or a malignant condition. It presents many of the characteristics of the later stages of bacillary dysentery, but is not so fulminating in its onset and does not produce profound toxemia, and the fever seldom is as high as in the former condition. The final differentiation, however, depends on the results of stool cultures and agglutination tests. Amebic dysentery is more gradual in its onset;

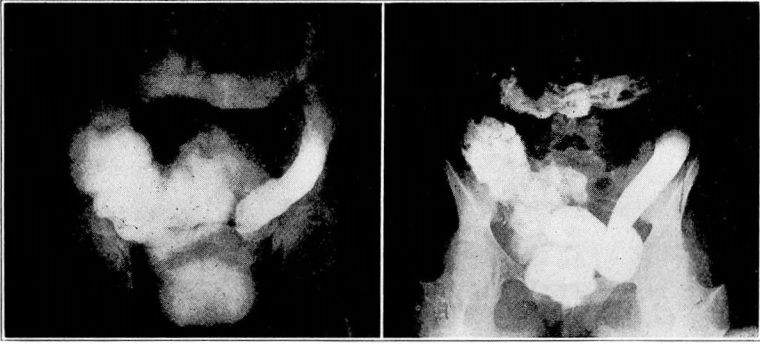

Fig. 7.—Two cases of chronic ulcerative colitis. Note the loss of tone in the colon.

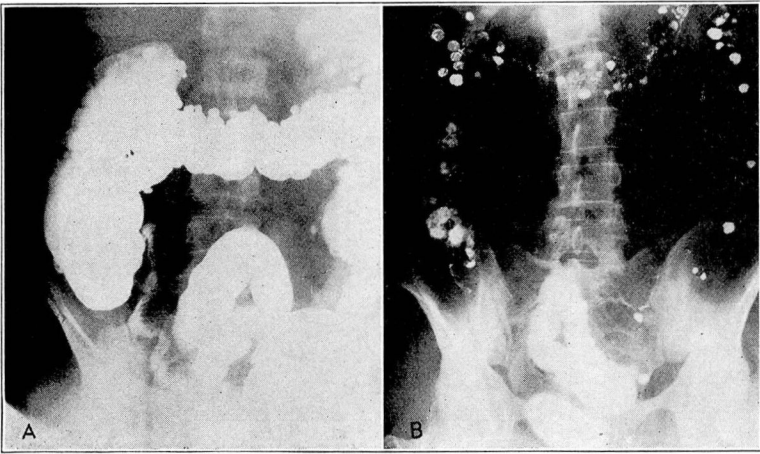


Fig. 8.—(A) A case of diverticulosis. Note the diverticula along the entire course of the colon. (B) Roentgenogram of a typical colon twenty-four hours after the administration of barium, showing many diverticula.

it presents stools containing amebae and gray, blood-stained or yellow mucus, and the condition of the patient is improved after three or four days of treatment with emetine hydrochloride. In this country, chronic bacillary dysentery is less common than is chronic ulcerative colitis, and its diagnosis is made by agglutination tests. Examination with the sigmoidoscope may reveal tumors or ulcers in the rectum and permit the obtaining from them of mucus, a slough or a scraping for examination or culture. A roentgenogram may be helpful in the recognition of colitis by revealing the presence of spasm or areas of ulceration.

Typhoid fever may be differentiated from ulcerative colitis by a history of exposure to a source of infection, followed in two or three

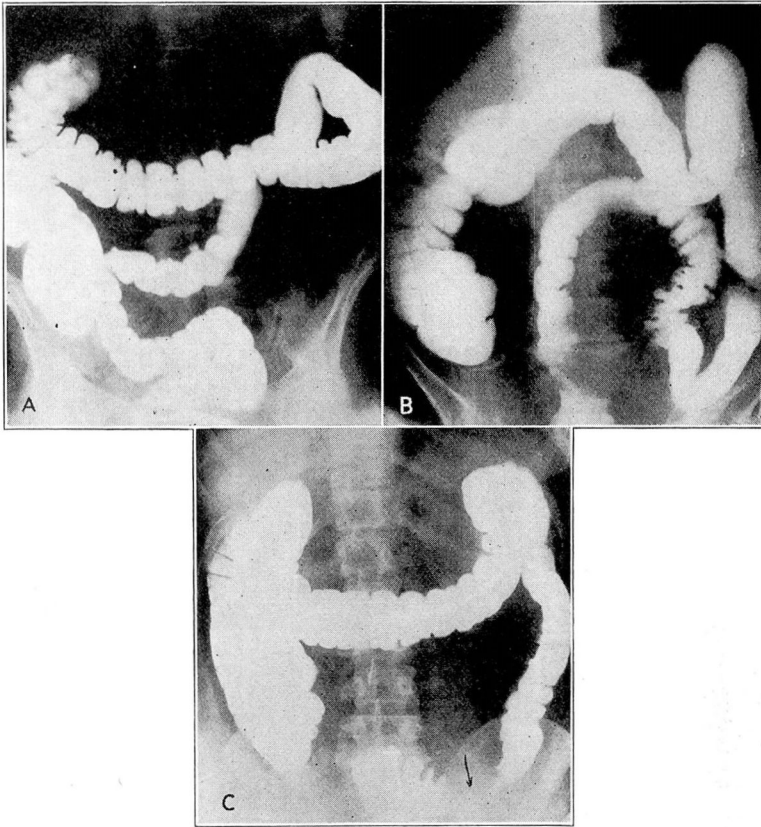


Fig. 9.— (A) Roentgenogram of sigmoid extending to right lower quadrant. Note several small diverticula in the sigmoid. (B) Diverticulosis of the sigmoid. Note the long loop of sigmoid with evidence of pressure from an extrinsic mass. (C) Roentgenogram showing almost complete obstruction in the sigmoid due to a large inflammatory mass in the area designated by the arrow. The presence of several small diverticula proximal to the lesion is evidence in favor of a non-malignant tumor.

weeks by an insidious onset, and at the end of another week by the development of rose spots and enlargement of the spleen. The temperature curve in typhoid fever usually is characteristic, and there are progressive leukopenia and lymphocytosis. Blood cultures may give positive results as early as the second day, and the Widal reaction is positive after the tenth day.

Cancer develops much more slowly than ulcerative colitis, and pain and griping are rarely seen early in malignant disease. Constipation is one of the earliest symptoms of carcinoma, as is the case in colitis, but in a case of carcinoma the patient is comfortable

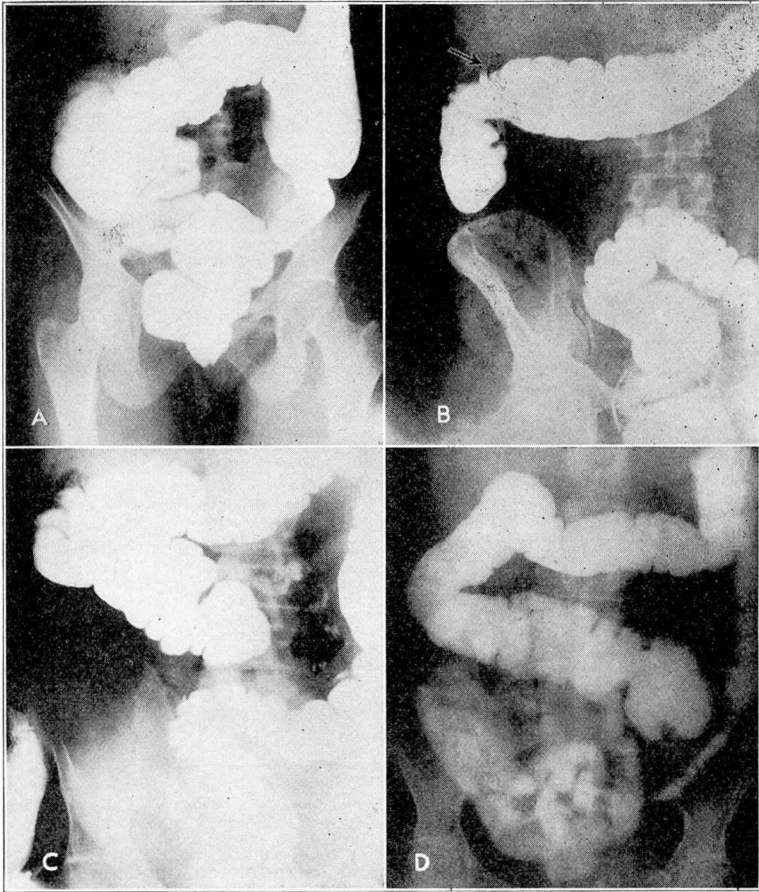


Fig. 10.— (A) Roentgenogram showing the cecum lying high in the right upper quadrant. It is in such cases as this that a diagnosis of appendicitis is difficult. (B) A similar case. The arrow points to the tip of the appendix lying high under the liver. (C) Roentgenogram showing the cecum lying in the midline. (D) Roentgenogram showing the cecum lying far to the left. Should appendicitis develop in this case, it would be difficult to diagnose. Symptoms would be referred to the lower left quadrant.

after the bowels have moved, except in the late stages of the disease, while in colitis a bowel movement fails to give relief.

PERICOLITIS

The manifestations of pericolicitis vary with the duration of the condition, the type and virulence of the infecting organism and the length of intestine involved. The chief symptoms are constipation, alternating with occasional diarrhea, constitutional disorders resulting from absorption, localized abdominal soreness or pain

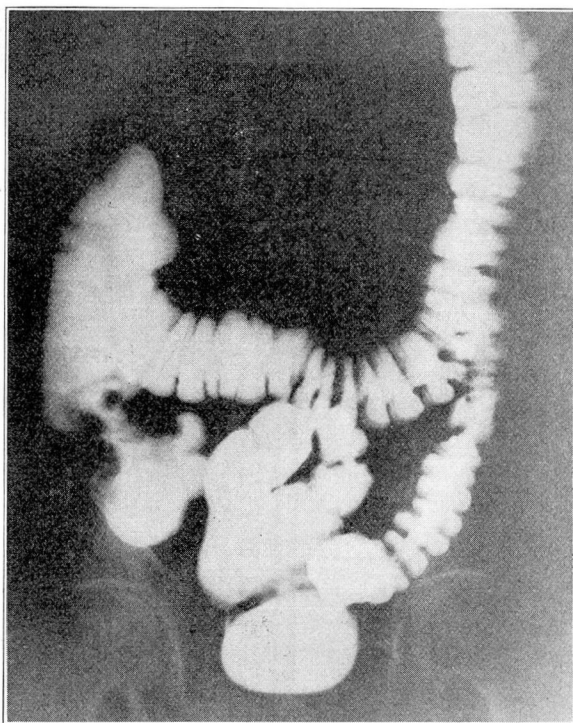


Fig. 11.— Roentgenogram showing a large filling defect in the first portion of the ascending colon due to carcinoma.

on pressure, a palpable abdominal mass, which may readily be mistaken for a tumor, and mucus or blood in the stools. Mild and sometimes alarming symptoms of intestinal obstruction may be present, depending on the degree of narrowing of the lumen of that portion of the colon involved. In cases in which the temperature is high, an abscess may be suspected.

In obscure cases it is necessary to differentiate between this condition and appendicitis, diverticulitis and cholecystitis. Fluoroscopic examination and roentgenograms following a barium sulphate enema will often aid in making the differential diagnosis, although in diverticulitis the enema is not so important as the twenty-four hour barium examination, since barium sulphate when given by mouth is so much more certain to fill a diverticulum than when given by enema.

APPENDICITIS

I do not mean to imply that all cases of appendicitis can be diagnosed by roentgenograms, but many cases cannot be diagnosed pre-

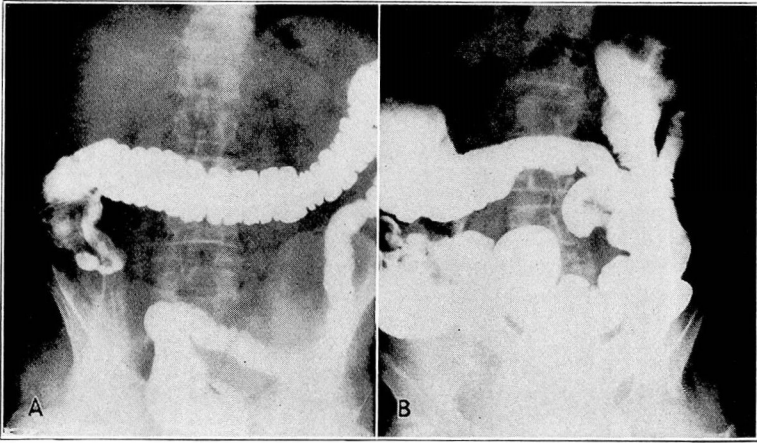


Fig. 12.— (A) Roentgenogram showing a filling defect in the cecum due to carcinoma. (B) Roentgenogram showing a filling defect in the ascending colon due to a large carcinoma.

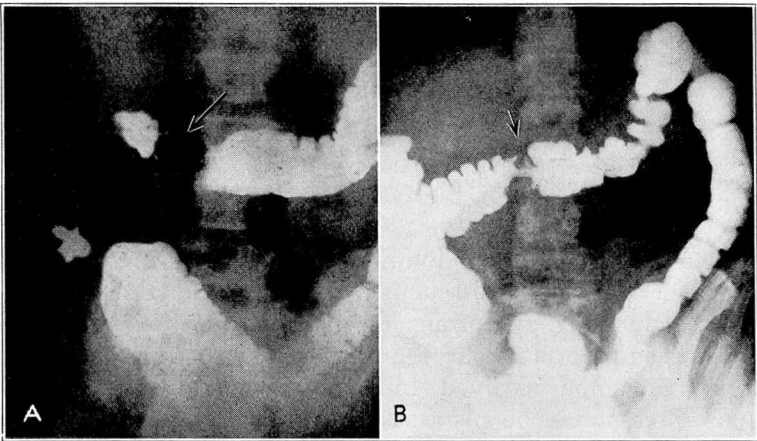


Fig. 13.— (A) The arrow points to a deformity in the transverse colon due to carcinoma. (B) A similar case, but less obstruction is present. However, note the beginning dilatation of the colon proximal to the obstructing area.

operatively by any other method. Acute appendicitis is not a problem for the roentgenologist, but one that should be handled promptly by the surgeon. The cases in which roentgenographic study is of value are those in which there is a history of vague abdominal uneasiness or distress, with a digestion that is not up to par. In many instances suspected cholecystitis can be ruled out by the roentgenographic demonstration of incomplete rotation of the colon which leaves the cecum and appendix in the region of the

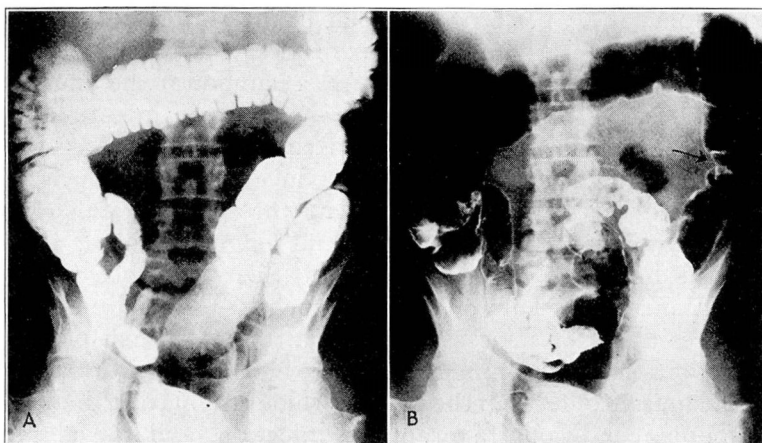


Fig. 14.— (A) A filling defect as seen fluoroscopically in the lower descending colon. The loop of the sigmoid obscures the deformed area. (B) The same case after air has been injected into the colon. The arrow points to a filling defect due to carcinoma.

gallbladder. Often also it is possible to demonstrate the presence of an elongated retrocecal appendix with the tip high up under the hepatic flexure, a finding that is of value in the differential diagnosis and of assistance to the surgeon in planning his incision. The presence of stones in the appendix also can be demonstrated roentgenographically, as well as adhesions that prevent the free movement characteristic of the normal appendix. In other types of appendiceal disease an irregular filling can be demonstrated that corresponds to definite localized tenderness. It is not often that the appendix is found in the classic McBurney position, but it can be localized accurately with x-rays, while pressure will determine the presence or absence of tenderness. Delayed emptying of the appendix (from twenty-four to seventy-two hours after the head of the colon has emptied) is thought by some authorities to be evidence of chronic appendicitis.

FOREIGN BODIES

The presence of foreign bodies can be demonstrated roentgenographically only when they are of opaque material. Serial roentgenograms and fluoroscopic examinations are essential in order to follow the progress of the foreign body through the intestinal tract and to make sure that it has not lodged at some vulnerable point.

TUBERCULOSIS

Tuberculosis of the colon and rectum may be either primary or secondary. In a review of 100 cases, Gant² found that the infection

was secondary in 75 per cent, and that in the majority of these the foci were located in the lungs, larynx or pharynx. Primary tuberculosis of the colon usually develops in the cecum or at the anus, while secondary lesions may be found anywhere in the intestinal tract, although they, too, are found most frequently in the cecum and rectum. Many factors contribute to produce this result, such as the greater speed of the intestinal content through the small bowel, which does not permit the bacilli to find lodgment there; attenuation of the bacilli by the gastric juices, their virulence not being recovered until the cecum or colon is reached; the alkaline reaction of the feces after the ileocecal region is attained, which provides a more propitious environment for the bacilli; the formation of hardened masses of feces in the cecum, which traumatize the mucosa and produce conditions favorable to infection, and the abundant lymphatic distribution in the ileocecal region, which favors the development of tuberculosis.

Several types of tuberculosis are found in the colon, the most common of which are the hyperplastic, ulcerative and miliary.

Hyperplastic tuberculosis occurs in both children and adults, most frequently in the third decade. It may be primary or it may be secondary to a focus higher up in the intestines or in some other organ. It produces a slow-growing tumor which at times is quiescent for two or three years before it attains sufficient size to occlude the lumen of the intestine and produce symptoms of obstruction. These tumors usually feel smooth when palpated, but examination of a gross section reveals a very irregular, hard and brittle type of tissue. Usually they are fixed, but they may be slightly movable. The rigidity of the terminal ileal segment is a characteristic roentgenographic observation.

In the ulcerative type of tuberculosis, the ulcers may be superficial or deep. Superficial ulceration may heal promptly, but deep ulceration progresses rapidly and is almost impossible to control. The mixed infection that must follow soon causes toxemia, imperfect digestion, constitutional manifestations, persistent diarrhea and extensive destruction of the mucosa and deeper bowel coverings. Hemorrhage, peritonitis, abscess, adhesions and other serious complications may be encountered, and if surgical intervention were instituted, a generalized miliary tuberculosis of all the abdominal viscera might be found.

The prognosis of intestinal miliary tuberculosis is unfavorable because it is secondary to a well established process elsewhere, and the patient is debilitated and unable to withstand the ravages of the fast-spreading tuberculous process.

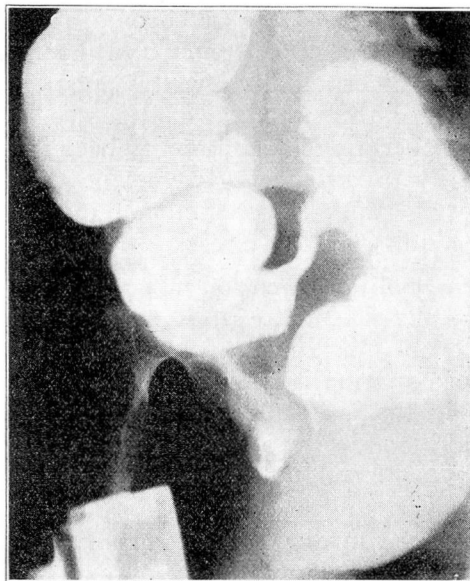


Fig. 15.—Roentgenogram showing carcinoma of the sigmoid. This could not be seen with the patient lying flat. The film was exposed with the right side of the patient uppermost. The sigmoid is a frequent location for carcinoma. The coils of the lower sigmoid and rectum overshadow these growths.

DIVERTICULA

A diverticulum is a non-neoplastic outpouching of intestine, having a lumen that connects with the bowel or that formerly connected with it. Diverticula may be congenital (true) or acquired (false), the latter form appearing more often between the ages of 40 and 60 years, and about twice as frequently in men as in women. Diverticula may develop at any point along the course of the colon, but are found most commonly in the sigmoid flexure, the descending colon, the cecum and the transverse colon. The hepatic flexure also is frequently involved, and diverticulitis at this point is at times most difficult to differentiate.

Diverticula may be single or multiple, large or small, smooth or irregular. The sacs may be quiescent for many years and then suddenly become obstructed, resulting in acute inflammation. Symptoms may then become severe and lead to the belief that appendicitis, peritonitis, intestinal obstruction, a new growth, or an abscess is present. Definite proof that many diverticula never produce symptoms is presented by the frequent finding of such pouches during the course of routine gastro-intestinal examinations and at autopsy.

Diverticulitis may be acute or chronic, more often the latter. Because of the size, form, consistency and macroscopic appearance of the tumor, a diverticulum often is mistaken for carcinoma. Doubtless many of the supposed carcinomas that have been reported cured by operation have in reality been merely inflammatory masses caused by diverticulitis. It may be that these diverticula are a predisposing cause of carcinoma, but to determine this definitely would require extensive research.

After the onset of inflammation in a severe case of diverticulitis, there will be localized tenderness, intense cramps and constipation with a sensation of blocking. When the lumen is almost occluded there are a marked formation of gas, severe pain, muscular rigidity, nausea and vomiting, an increased temperature and pulse rate and mucus, pus and blood in the stools. If the process progresses to the point of rupture, the usual symptoms of spreading peritonitis are present. If an abscess forms, there is continued localized pain and swelling until it has ruptured into the intestine or peritoneal cavity or has been drained.

Given a history of chronic left-sided inflammation, with periodic exacerbations and an absence of cachexia and loss of weight, a diagnosis of diverticulitis usually is justified. Proctoscopic examination may reveal a small opening from which pus is draining, and pus in the bowel is suggestive of diverticulitis.

If the patient's condition is extremely grave, it is not advisable to subject him to a roentgenographic examination. Cases have been diagnosed, however, in which the obstruction was almost complete, a barium sulphate enema showing the filling defect. It is often impossible to make the differentiation on the basis of the roentgen examination alone, but the small cavitation that is present in carcinoma is rarely seen in diverticulitis. The deformity, of course, is due to narrowing of the lumen of the colon, but in diverticulitis there is, as a rule, no break in the mucosa and the rugae can be seen in the deformity.

CARCINOMA

Unfortunately, early carcinoma of the colon is difficult to diagnose roentgenographically, as a filling defect does not develop until the late stages of the disease. It is impossible to see the early ulcerations, and a mass must be present that will displace a portion of the column of barium sulphate in the colon before a diagnosis can be made. After the growth has become large enough to produce partial obstruction, dilatation of the colon proximal to the lesion will be noticed. In many instances carcinoma of any portion of the

colon may be overlooked if redundancies cover up the lesion. A fluoroscopic examination should be made from all angles, therefore, in an effort to throw these redundant loops out of the field of vision and pick up some small filling defect on either the anterior or the posterior wall of the intestine. Patients suffering from early carcinoma of the colon, however, seldom present themselves for roentgenographic examination.

Fully developed cancer of the colon usually produces fairly typical symptoms: alternating constipation and diarrhea, distention of the colon, tenderness, localized abdominal pain, attacks of offensive discharge containing mucus, blood, pus and possibly tissue fragments, loss of weight, cachexia, visible peristalsis and a filling defect, with evidence of dilatation of the colon proximal to this defect. It is often difficult to pass any of the opaque medium through the area of partial obstruction when the barium meal is given by enema, though a small amount may pass the obstruction when the barium meal is given by mouth. Atropine and other antispasmodics offer little assistance in the passage of the enema through the deformed area. When cecal carcinoma is suspected, a delay in ileal emptying is a significant sign. A proctoscopic examination should always be made before a barium sulphate enema is administered, in order to detect any evidence of the disease that may be visible in the rectum or lower bowel. Barium sulphate should not be given before this examination is complete, as it coats the bowel and obscures any evidence of disease that may be present.

REFERENCES

- 1 Gauss, H.: The spastic colon. *Ann. Int. Med.*, 3:1128, 1930.
- 2 Gant, S. G.: *Diseases of the Rectum, Anus and Colon*. W. B. Saunders Co., Philadelphia, 1923, vol. 3, p. 43.