

RENAL RICKETS

Report of a Case

E. PERRY McCULLAGH, M.D. and WM. L. PROUDFIT, M.D.

Renal rickets is rickets resulting from chronic renal insufficiency. Renal dwarfism may refer to the same condition and implies dwarfism caused by renal rickets. Renal infantilism refers to such cases as show dwarfism plus hypoplasia of the genitalia. Both the term dwarfism and infantilism in this regard have the disadvantage of distracting from the idea that kidney disease and rickets are the underlying disorders. In some instances renal infantilism is an actual misnomer applying to infantilism with diabetes insipidus without concomitant kidney disease, both the infantilism and the diabetes being pituitary in origin.

In some cases renal rickets may be difficult to distinguish from primary hyperparathyroidism especially when it occurs in growing individuals. In some of the cases in the literature reviewers have disagreed on the origin of the disease, the same cases being classified by one author as primary renal disease and by others as primary hyperparathyroidism. The reason for this is that in both instances when the kidney damage reaches a certain point the effect upon blood chemistry, calcium balance, and the skeleton may become indistinguishable.

In cases in which the differential diagnosis is difficult, the history is one of the most important points. In hyperparathyroidism skeletal changes precede evidence of renal damage, while in renal rickets kidney disease has existed for a long time before bony damage becomes apparent. Hyperparathyroidism may exist without any recognizable x-ray evidence of bony disease, but in those instances in which the parathyroid disease has resulted in severe kidney damage clear-cut changes in the bone might be expected. It is well to remember also that renal rickets usually results from a congenital deformity of the lower urinary tract, so that the finding of such a condition may help greatly in the diagnosis. Both in rickets and in renal rickets parathyroid enlargement and parathyroid hyperfunction have been demonstrated. In primary hyperparathyroidism a single parathyroid adenoma is likely to be present, whereas in secondary hyperparathyroidism due to kidney disease hypertrophy of all the parathyroids occurs. Albright¹ describes a third type of hyperparathyroidism in which all parathyroids are hyperplastic and

in which the hyperparathyroidism appears to be primary in type. It is assumed to be primary because there is no other condition evident to suggest that it is a compensatory mechanism. Doubt has been expressed by some as to whether such a condition is primary or not. One point which favors the primary nature of the condition is that excision of some of the glands leads to clinical improvement. The validity of such an argument remains to be proved.

CASE REPORT

A 15 year old boy was seen in September, 1938 with a complaint of "knock-knees" of 7 months' duration.

At the age of 2 years he had been admitted to another hospital because of vomiting, fever, abdominal distention, and "difficulty in urination." A diagnosis of acute ileus had been made, and the patient had improved on conservative therapy. Nothing is known of the urinary symptoms at that time, except for the fact that there was "difficulty in urination." Apparently he got along fairly well subsequently.

At the age of 6 he had been readmitted to the same hospital for circumcision because of a redundant prepuce.

At the age of 7 he had been admitted for the third time to the same hospital with a history of fever, malaise, and weight loss of 3 weeks' duration. He also complained of pain in the left side of the abdomen. At that time his father stated that there had been a mass in the lower abdomen since the child was 2 years of age. An x-ray showed an enlarged bladder with an irregular filling defect in the posterior portion. An operation was performed on November 4, 1930, and the wall of the bladder was found to be hypertrophied. Bougies introduced through the urethra met resistance at the entrance of the bladder and, when enough force was exerted, entered the bladder "almost curving like a hairpin and proceeding up towards the symphysis." A diagnosis of a congenital flap valve at the urethral opening was made, and this "valve" was cut. A suprapubic catheter was inserted, and the incision was closed. The patient was discharged on January 29, 1931, at which time he was voiding normally. He had gained 20 pounds in weight during his hospital stay. The suprapubic wound drained urine for about one year, but the patient had no urinary symptoms except for occasional nocturia. However, his mother stated that she believed that pus had been present in the urine most of the time since the operation.

The patient had grown normally until the age of 6 years; after which he grew relatively little. There was marked anorexia. No urinary symptoms were present except for occasional nocturia.

Physical examination revealed an undeveloped and undernourished boy. The temperature and pulse were normal, and the blood pressure was 126/84. His height was 56 inches, his weight was $75\frac{3}{4}$ pounds, and his age 15 years. The skin and mucous membranes were pale. The external genitalia were underdeveloped for his age, and there was no sign of puberty. There was a genu valgum deformity of both legs. (Fig. 1)

Repeated urinalyses revealed a specific gravity of 1.007 to 1.018 with a trace of albumin. Numerous white blood cells were found in all specimens. Cultures of ureteral urine obtained at cystoscopy showed *Staphylococcus albus*. The initial red blood cell count was 2,540,000, and the hemoglobin was 43 per cent. Temporary improvement

RENAL RICKETS

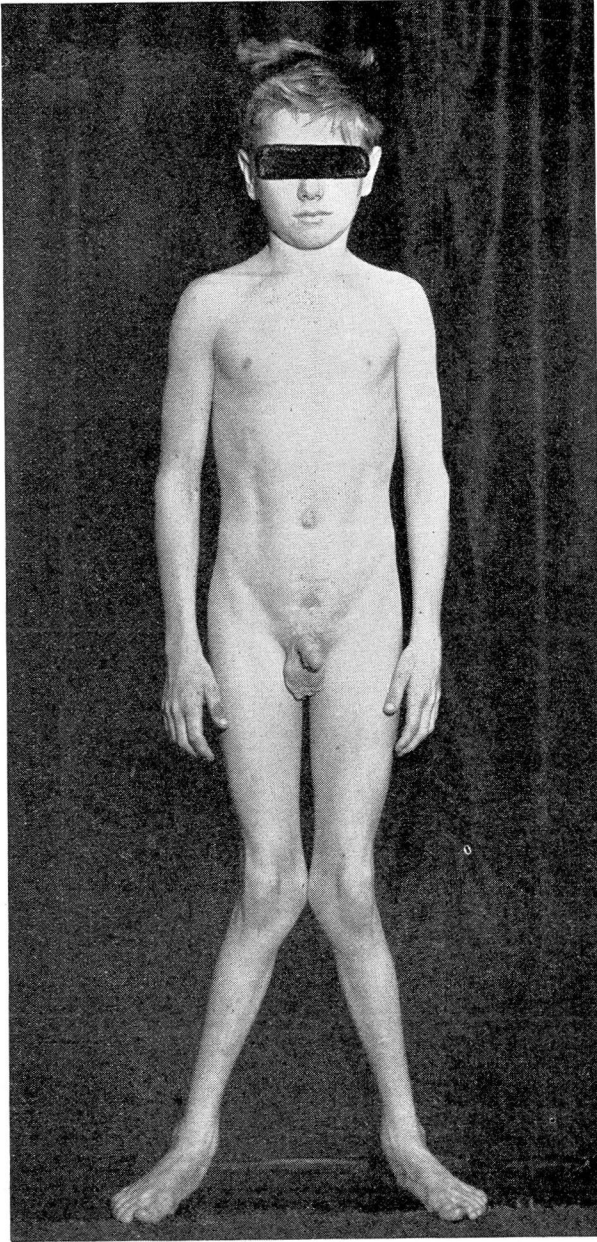
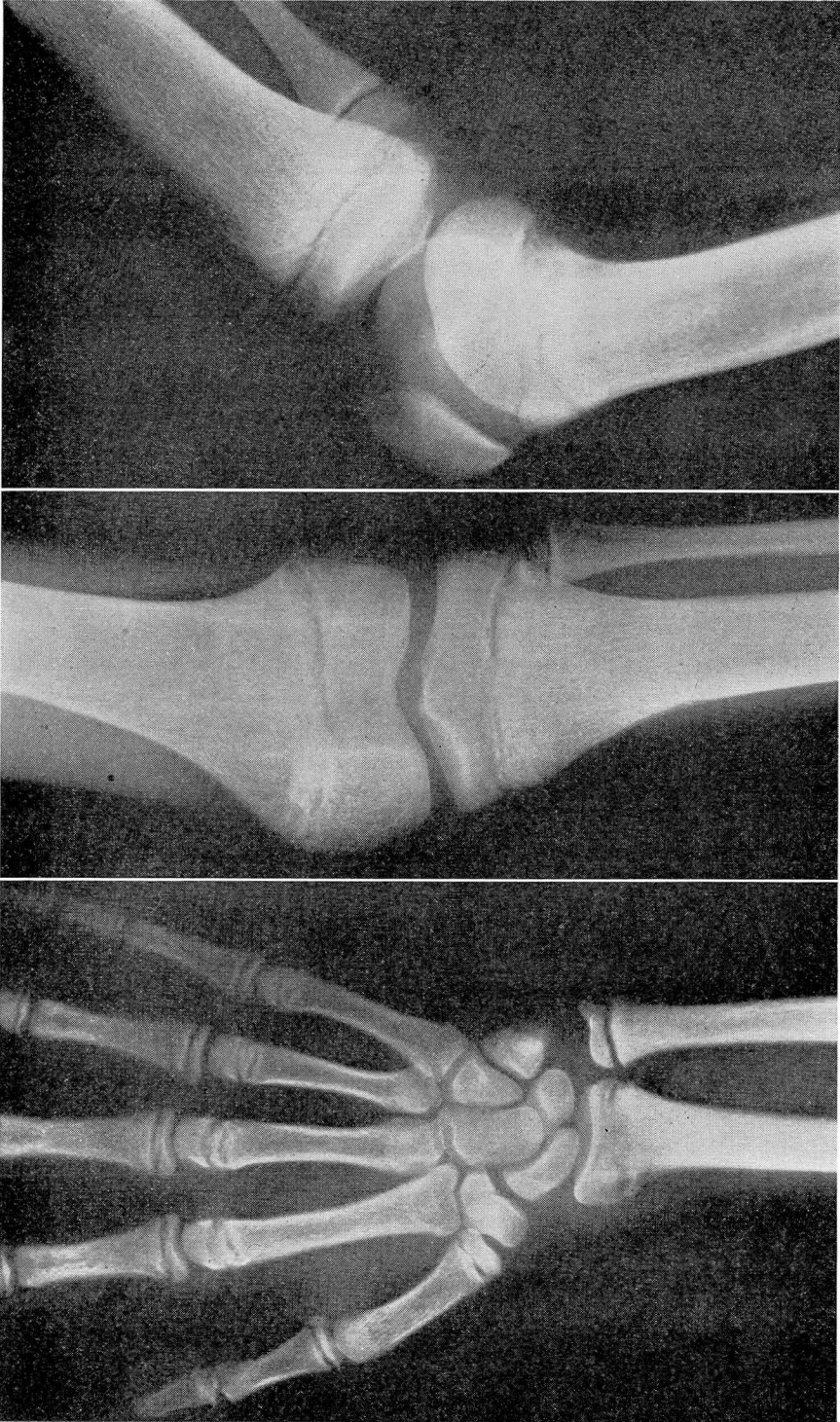

FIGURE 1. Showing extreme genu valgum.



A. Roentgenogram of the left wrist showing similar changes and, in addition, a slight displacement of the epiphysis.

B and C. Roentgenogram of the left knee showing irregular ossification at the metaphysis of both the femur and the tibia and narrowing of the epiphyseal line.

FIGURE 2

RENAL RICKETS

in the blood counts was appreciated after transfusion. The white blood cell counts were normal. The blood sugar was 104 mg. per 100 cc., the urea 150 to 219 mg., the uric acid 5.0 mg., the creatinine 4.2 to 4.6 mg., the cholesterol 145 mg., the calcium 9.5 mg. on two occasions, the phosphorus 5.5 to 6.8 mg., the serum alkaline phosphatase was 10.9 Bodansky units (normal 4 units), the blood chlorides 610 mg. per cent, and the blood carbon dioxide combining power varied from 19.5 to 42.4.

The urea clearance test showed 11 per cent excretion in the first hour and 6 per cent in the second hour.

Roentgenograms of the left knee showed irregular ossification at the epiphysis, and the epiphyseal line was narrowed and fuzzy in appearance. There was no broadening or cupping present, and the adjacent bones appeared to be normal. The left wrist showed similar changes in the distal end of the radius. In addition, there was a slight displacement of the epiphysis and a small amount of static subperiosteal calcification. The epiphyses of the metacarpals showed minimal changes. There appeared to be slightly irregular ossification at the epiphysis of both hips. The appearance of the bones seemed to be consistent with a diagnosis of renal rickets. (Fig. 2)

Cystoscopy was performed in the hospital, and about 50 cc. of residual urine was obtained. The bladder showed a moderate degree of trabeculation, but no evidence of inflammation. Ureteral catheters were passed without meeting obstruction. The cystoscope was withdrawn into the bladder neck, the appearance of which simulated bilateral hypertrophy of the prostate. The verumontanum appeared to be normal, and the prostatic urethra did not appear to be lengthened. Bilateral pyelograms revealed extreme hydronephrosis of each kidney with associated marked dilatation of each ureter. (Fig. 3)

A suprapubic cystostomy was performed on September 24, 1938. The patient was discharged from the hospital on October 12, 1938. He was instructed to follow a high calcium, low phosphorus diet and to take calcium lactate, ferrous sulfate, and vitamin preparations daily. He was seen three days later because the suprapubic tube had come out, and this was reinserted.

He was admitted to Lakeside Hospital, Cleveland,* on January 21, 1939, because of hematuria and hemoptysis of 3 weeks' duration. The physical examination was much the same as at the time he was seen by us. The suprapubic catheter was still in place. The urine was grossly bloody, and there was a marked anemia. The blood urea was 98.3 mg. per 100 cc., the creatinine 8.7 mg., the calcium 6.6 mg., the phosphorus 10.4 mg., the serum phosphatase was 13.3 mg., and the chlorides were 626 mg. The carbon dioxide combining power was 31.1 volumes per cent. The phenosulfonphthalein renal function test showed no excretion of the dye in 2 hours. The urea clearance test resulted in 2.7 per cent excretion in the first hour and 4.5 per cent in the second.

Cystoscopy showed a moderate generalized cystitis. The right ureter was catheterized, and marked hydronephrosis and hydroureter were found. The left ureter could not be catheterized. A median bar formation in the prostate was suspected. The patient was discharged on January 25, 1939, to be followed in the out-patient department. He did not return for observation, however, and was seen in the emergency ward on March 13, 1942. The suprapubic catheter had not drained for 2 days. During the previous 24 hours, the respirations had been deep and rapid, and he had experienced several chills. The patient's temperature was 38 C., the pulse was 128 per minute, the respirations 48 per minute, and the blood pressure 120/76. Small hemorrhages were

* We are grateful to Lakeside Hospital and especially to the Department of Pathology for allowing us to publish excerpts from their records, and to Dr. G. M. Jilovec for his studies of the tooth.

seen in both eyegrounds. Many moist crackling râles were heard over the base of the right lung. The urine showed a large amount of albumin and many white blood cells. The red blood cell count was 850,000 and the hemoglobin content was 14 per cent; the white blood cell count was 8,600. The blood urea nitrogen was 188 mg. per 100 cc., the creatinine 15.2 mg., and the carbon dioxide combining power was 23.3 volumes per cent. The patient became rapidly worse in spite of treatment and died the day following admission.

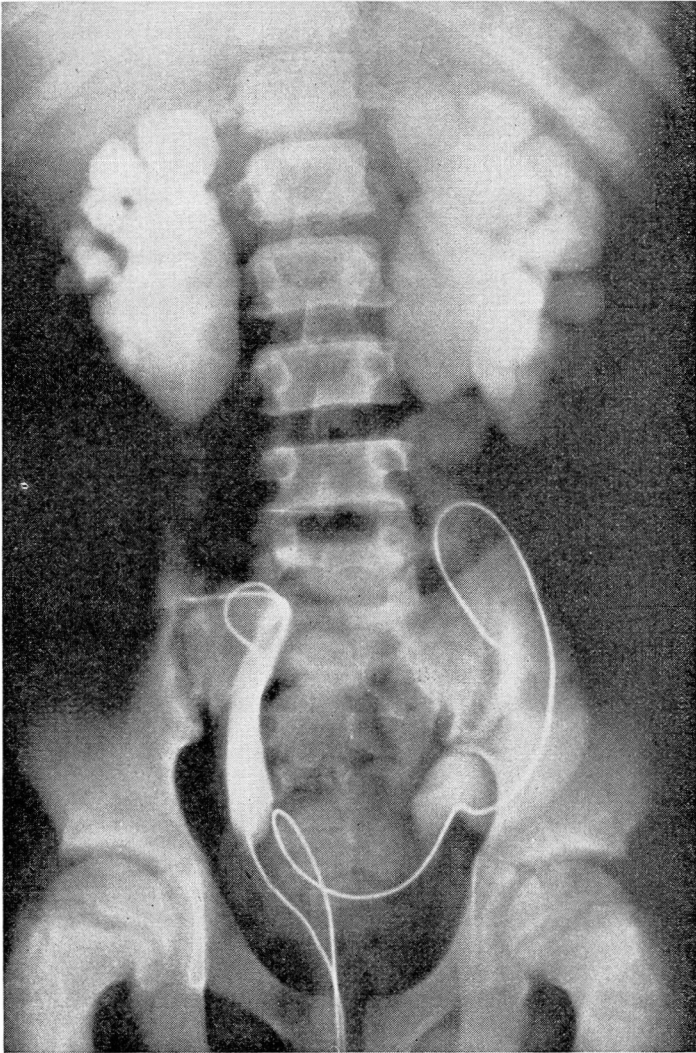


FIGURE 3

Retrograde pyelograms showing bilateral hydronephrosis and hydroureter.

RENAL RICKETS

Autopsy revealed the kidneys to be small, the right one weighing 75 grams and the left 90 grams. The capsule stripped with difficulty to reveal a rough, nodular surface. The kidney substance was cut with increased resistance. There was dilatation of the renal pelves and calyces, and in many portions the entire renal parenchyma was reduced to a mere shell only 1 mm. thick, although in other areas the thickness was as much as 1.5 cm. The usual architecture of the cortex and pyramids was absent, and the boundary between the cortex and the medulla could not be distinguished. The small renal vessels were thick walled and prominent. The renal pelves were extremely dilated, as were the ureters, which measured 2.5 cm. in circumference.

The bladder was thick walled, with a suprapubic fistulous communication with the exterior. The mucosa was thrown up in thick folds and was markedly hyperemic. The ureteral orifices were widely patent. A slight elevation of the urethra was present at the bladder neck, and in this region the urethral floor was irregular and slightly nodular. The prostate was quite small.

Microscopic examination of multiple sections of both kidneys showed marked destruction of the renal substance and distortion of the usual architecture. The glomeruli were greatly reduced in number, were rather cellular, and in certain instances were surrounded by a thick zone of fibrous tissue. There was widespread fibrosis throughout the kidney and some focal round cell infiltration. No normal tubular epithelium was seen. Most of the tubules were greatly dilated and lined with flattened or low cuboidal cells, containing a pink-staining, homogenous material. Other tubules were extremely small and surrounded by fibrous tissue. The arterioles showed a considerable degree of thickening of the wall, particularly of the intima, and some reduction in the size of the lumen. There was edema and round cell infiltration of the connective tissue beneath the epithelium of the renal pelvis.

Sections of the ureters showed a thick, edematous, fibromuscular wall. The mucosa was composed of a layer of transitional epithelium which was piled up in places in such a way as to suggest squamous metaplasia. Beneath this there was a marked infiltration of small round cells and plasma cells.

The bladder wall showed edema, fibrosis, and infiltration with small round cells and plasma cells. The mucosa was composed of transitional cell epithelium. Longitudinal sections through the bladder neck from the verumontanum to the trigone showed transitional cell epithelium beneath which there was edematous tissue infiltrated with small round cells. There was chronic inflammation in the portion of the prostate in this region. In other sections of the prostate there was moderately dense fibromuscular tissue containing glands of the usual type and small areas of round cell infiltration.

In the posterior capsule of the thyroid 5 small bodies were found. These bodies were orange and resembled enlarged parathyroid glands. The weights of these glands were 58 mg., 85 mg., 92 mg., 128 mg., and 185 mg., giving a total weight of 548 mg. The average total weight for these glands should be about 100 mg.

Microscopic examination of the parathyroid glands showed that almost all of the cells were chief cells. The chief cells had the usual appearance, containing large round chromatic nuclei and finely granulated cytoplasm. In a few portions there was formation of alveoli.

Sections were made through the distal epiphysis of the left radius and the proximal epiphysis of the right tibia. Microscopic examination of these sections showed prolifera-

tion of the provisional zone of ossification. (Fig. 4) Some of the bony trabeculae had outer rims of osteoid tissue. In one of the sections there was an infraction of the cartilage, which was replaced by a fibrinoid type of material. The bony tissue itself differed from that usually seen in vitamin D deficiency rickets in that it was poorer in calcium. A 6 year old molar was extracted, decalcified, and sectioned. Nothing could be demonstrated which is not commonly found in teeth in this area. Unfortunately, no teeth which were calcifying later in the life of the patient were examined.

The examination of the other organs showed no significant findings except for bronchopneumonia. The thyroid, adrenals, pancreas, and testes were normal.

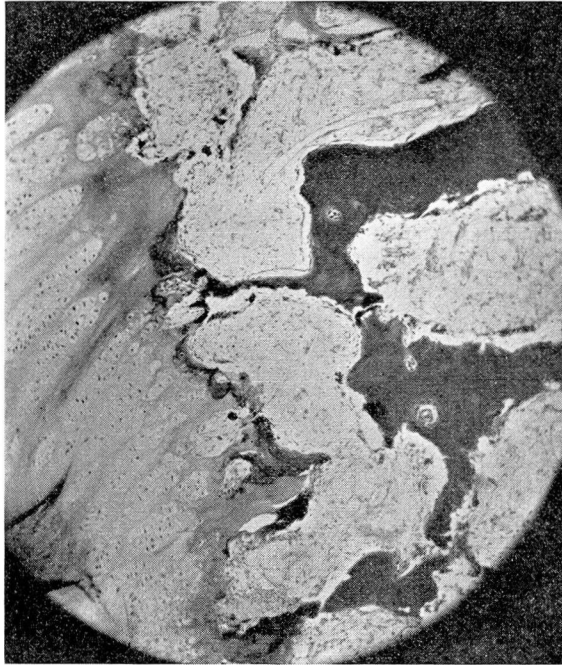


FIGURE 4. Section of the bone showing the irregular zone of advancing ossification and osteoparasis.

COMMENT

What causes such parathyroid enlargement? The answer must be theoretical. To begin with, renal failure results in many changes including phosphorus retention and chronic acidosis. The primary action of the parathyroid hormone appears to be upon the kidney, and its primary effect is in increasing the rate of phosphorus excretion. This is the first effect to be measured after injection of parathyroid extract. It seems reasonable to assume then that an abnormally high blood phosphorus

RENAL RICKETS

level may stimulate parathyroid activity and lead to overwork hypertrophy. A second factor is the tendency to low blood calcium.

What causes the blood calcium to be low? Several factors may be operating. The high phosphorus levels tend to bring the blood calcium down. The tendency to low calcium levels is further aggravated by the chronic acidosis which increases the excretion of calcium. It seems likely also that the excretion of phosphorus through the bowel would interfere with proper calcium absorption.

Why does the bone disease occur? This is not known, but here again it may be worthwhile to theorize. Phosphorus retention in itself obviously could not be an adequate explanation. There are several possible explanations. The first is that chronic acidosis leads to a continued high rate of calcium excretion, and this, we believe, is the chief factor. The very high level of calcium in the stool represents both unabsorbed calcium and excreted calcium. In this case the patient's nutrition was poor. He refused most of the food offered him, and no attention had been given to his receiving supplementary vitamins. It seems likely therefore that Vitamin D deficiency was an additional factor in producing calcium starvation.

What is the evidence that hyperparathyroidism exists in renal rickets? In 1921 Pappenheimer and Minor² studied the parathyroids in 14 cases of human rickets and in 18 normal cases. They showed that there was a decided increase in the size of the parathyroids in the cases of rickets. This suggested possible hyperfunction. Hamilton and Schwartz^{3,4} in 1932 and 1933 found that a large dose of calcium chloride or calcium gluconate given orally to rachitic rabbits caused a more marked rise in serum calcium than occurred in normal animals, and demonstrated that this property was transferable in rachitic blood. They showed this in the following way. Normal blood injected into rabbits after feeding them a large dose of calcium caused only a slight elevation as compared to that seen in the controls. However, when these animals were fed calcium and then injected with rachitic blood, a rise in blood calcium occurred which was much greater. The rise was identical to that seen after giving the animals parathyroid extract. They cautiously concluded that "the blood of rachitic rabbits is abnormally rich either in parathyroid hormone or in some other substance with identical effect on the serum calcium."

Shelling and Ramsen⁵ applied this test to clinical cases of various types and found three positive tests. One was in a case of osteitis fibrosa cystica, one was in a case of florid rickets of several years' duration, and

one was in a case of renal rickets shown at autopsy to have reached hypertrophy of the parathyroid glands. The normal cases were calculated to contain from 3 to 7 units of parathyroid hormone per 100 cc. The case of osteitis fibrosa had 42 units per 100 cc., and the case of renal rickets had 14 units per 100 cc. In short, hyperparathyroidism according to this test was found in these three types of cases and might be considered primary in the first and secondary in the other two. This test was not applied in the case reported here.

SUMMARY

A case is presented of renal rickets in a 15 year old boy. The disease followed a deformity of the lower urinary tract and was associated with delayed puberty and enlargement of all the parathyroid glands.

The most important lesson to be learned from this case is that early effective treatment of the urinary obstruction probably would have prevented this fatal ailment.

BIBLIOGRAPHY

1. Albright, F.: Discussion of case records of the Massachusetts General Hospital. *New Eng. J. Med.*, 214:323, 1936.
2. Pappenheimer, A. M., and Minor, J.: Hyperplasia of parathyroids in human rickets. *J. Med. Research*, 42:391 (June-September) 1921.
3. Hamilton, B., and Schwartz, C.: Rickets and hyperparathyroidism. *Proc. Am. Soc. Clin. Investigation.*, 11:817, 1932.
4. Hamilton, B., and Schwartz, C.: Rickets and hyperparathyroidism. *Am. J. Dis. of Child.*, 46:775, 1933.
5. Shelling, D. H., and Remsen, D.: Renal rickets. *Bull. Johns Hopkins Hosp.*, 57:158, 1935.