

## MULTIPLE MYELOMA WITH NITROGEN RETENTION

R. H. McDONALD, M.D.

The early clinical diagnosis of multiple myeloma is rendered difficult by the relative vagueness of the symptoms and by the scarcity of physical signs. The first symptoms are usually indefinite pains in the lower chest or the lumbosacral spine. Since the patient is usually in the fourth or later decades of life, these pains are apt to be regarded as being arthritic, myositic, or fibrositic in origin and are treated as such. Most patients, therefore, have increasing symptoms before a thorough investigation with careful urinalyses, blood studies, x-ray studies, serum protein determinations, and finally bone marrow studies establish the diagnosis. Albuminuria is a frequent finding, and renal failure is a common complication in well-defined cases.

In the following case an azotemia of unknown origin was the outstanding clinical feature without other indications of myeloma. The original problem was to explain an increased blood urea, and the correct diagnosis was only determined by methodical elimination of the various causes of azotemia. In retrospect, however, the history was more suggestive of the diagnosis than it appeared to be at first consideration.

### CASE REPORT

A Greek restaurateur, age 42, was admitted to the Clinic August 6, 1942, with the chief complaint of nausea and vomiting of 3 weeks' duration. He stated that he had been well until the preceding June, at which time following heavy lifting he had experienced a very severe pain in the left costal margin and left lower chest. It had persisted for several days and had been associated with cough and sputum. It had been partially relieved by the application of adhesive plaster, but some localized tenderness had remained over the affected area. Hematuria had not been present at the time of injury, but 3 weeks subsequently the patient had developed diurnal urinary frequency without dysuria occurring every 2 to 3 hours and nocturnal frequency two or three times. Three weeks before admission he had begun to vomit approximately an hour after meals, and at the time of admission he was unable to retain any food. There had been no epigastric pain at any time, and hematemesis was denied as well as melena. He had lost 25 pounds in weight since the onset of the illness which had been completely afebrile as far as he was aware. Albumin had been found in the urine, and the patient had been treated for kidney disease. Further history appeared irrelevant.

Physical examination revealed a well-developed and adequately nourished, rather healthy looking adult. The skin and mucous membranes were normal in color and tex-

## MULTIPLE MYELOMA

ture. The pulse rate was 92, the temperature 97 F., the blood pressure 110/70. The pupils were equal and reacted normally to light and accommodation. The optic disks were clearly outlined, and the retinae appeared normal. The ear drums were clean and shiny. The maxillary sinuses were somewhat dull to transillumination. There was considerable dental repair with several gold crowns and well-marked pyorrhea and gingivitis. There were no palpable lymph nodes in the neck and no thyroid enlargement. The chest was symmetrical, and the respiratory movements were normal. Slight tenderness was demonstrated in the left chest anteriorly, but no swelling was noted over any of the ribs. The heart was of moderate size, regular, and rhythmic. There was no palpable enlargement of the kidneys, liver, or spleen, and no abdominal masses. Some tenderness was elicited on deep pressure over both costovertebral angles. The external genitalia were of normal male type. A bilateral inguinal hernia was present. The rectal sphincter was of normal tone, and the prostate of normal size and consistency. Neurologic examination revealed hyperactive reflexes, but no abnormal reflexes were elicited, and there were no sensory nor motor changes. No gross skeletal abnormalities were demonstrated.

A routine urinalysis was reported as follows: pH 4.5, specific gravity 1.015, albumin 3 plus, sugar negative; microscopically, numerous white blood cells were seen. There were 3,500,000 red blood cells, with a hemoglobin of 68 per cent; and 9,650 white blood cells. The fasting blood sugar was reported as 116 mg. per cent. The blood Wassermann and Kahn reactions were negative. The urea clearance test of the renal reserve showed 52 per cent function in the first hour, and 44 per cent in the second hour. Blood urea was 156 mg. per cent.

An x-ray of the chest was reported as being normal. Films of the lumbosacral region were reported normal with the exception of a little osteo-arthritis. There were no suspicious urinary tract shadows, and both kidneys were normal in size and position. There were, however, many calcifications in the prostate. An excretory urogram showed poor function in both kidneys. The total renal function was not of sufficient quantity during the one-hour period for diagnosis. A cholecystogram revealed a normally functioning gallbladder without evidence of calculi. The esophagus, stomach, and duodenum appeared normal except for some hypertrophy of the gastric rugae. During fluoroscopy there was no obstruction to the passage of barium. The colon showed no evidence of organic lesion. There was no evidence of diaphragmatic hernia. The absence of free hydrochloric acid was demonstrated in the gastric juice even after histamine stimulation on two occasions, with a total acidity of 25 on the first test and 60 on the second.

The patient was given intravenous glucose using a maximum of 2,000 cc. of 10 per cent glucose in normal saline daily. Considerable clinical improvement was manifested within a few days, and at the end of a week the patient was able to retain a normal diet but still complained of generalized pain of rather indefinite character. At the end of 2 weeks the blood urea was 39 mg. per cent having steadily decreased from the initial elevated reading. In the meantime routine urinalysis had shown only a small amount of albumin and a few white blood cells. A culture of urine was reported as showing a *Staphylococcus albus* of nonurea-splitting type. Retrograde pyelography and cystoscopy were carried out with entirely negative results.

Further investigation revealed the true nature of the underlying condition. A test for Bence-Jones protein in the urine was positive. A recheck of the blood count showed 2,610,000 red blood cells, with a hemoglobin of 49 per cent; and 4,100 white blood cells. The volume of packed cells was 51 per cent of normal, the volume index 0.98, color index 0.94, and saturation index 0.96. Erythrocytes showed slight anisocytosis and slight pallor, but were normal in shape on stained preparation. No regenerative forms were

R. H. McDONALD

seen. The differential leukocyte count showed 61 per cent neutrophiles, 30 per cent lymphocytes, 1 per cent eosinophiles, and 8 per cent monocytes. No abnormal forms were seen. The icteric index was 4, and the platelets were normal. Marked rouleaux formation was noted. The serum proteins totaled 9 mg. per cent, of which albumin constituted 4 mg. per cent and globulin 5 mg. per cent.

Sternal puncture was easily performed, the sternal cortex being soft and thin. Approximately  $\frac{1}{2}$  cc. of bloody material was obtained, and on stained preparation numerous atypical plasma cells were the only recognizable cellular elements.

Subsequently, an x-ray of the skull revealed numerous extensive defects suggestive

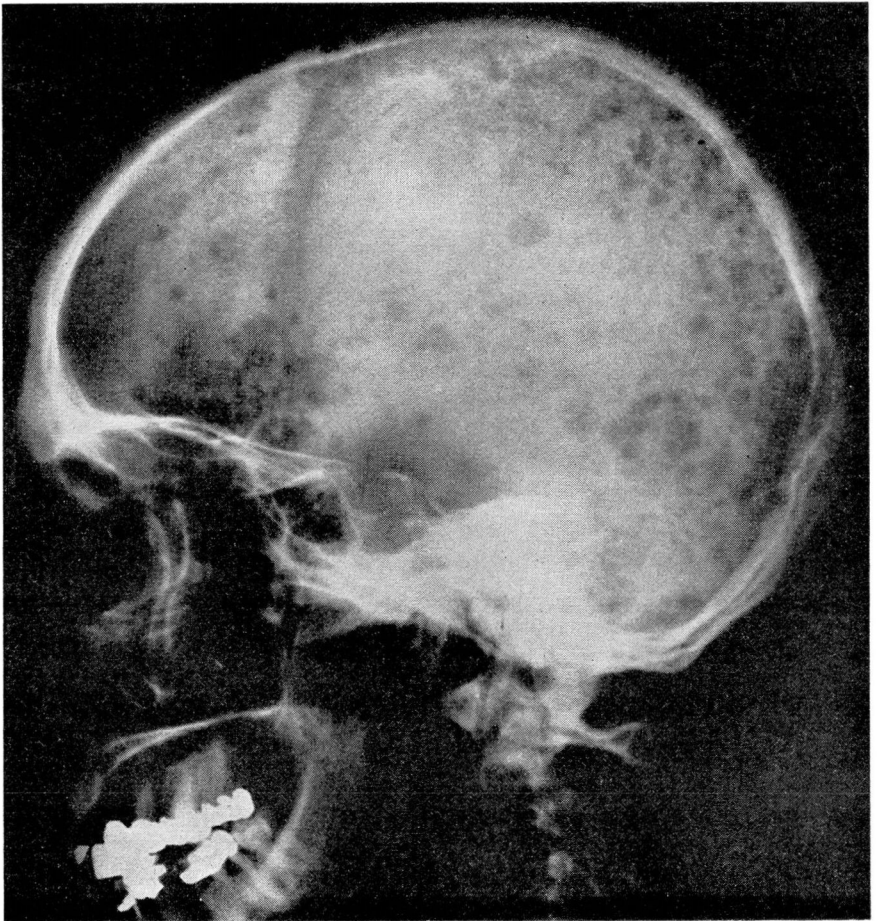


FIGURE 1

X-ray of the skull showing characteristic bony defects of multiple myeloma.

## MULTIPLE MYELOMA

of multiple myeloma, and a more critical examination of the chest x-rays revealed several areas in the ribs at least suggestive of myelomatous degeneration which had been previously overlooked.

### DISCUSSION

This patient presented many characteristic signs of multiple myeloma. The case illustrates the necessity for considering this condition in the differential diagnosis of vague generalized pain. He reported an episode of acute pain in the lower chest which has been noted in many of our cases. Physical examination was of little aid in establishing the diagnosis, although once it had been made, very definite localized tender areas could be demonstrated on several of the ribs. No definite thickening could be discerned, and no egg-shell crackling of the cortex was elicited. The presence of Bence-Jones proteinuria was readily established. Renal failure occurred earlier than usual, and uremia dominated the clinical picture when the patient was first seen. The anemia was not so marked as frequently occurs. A moderate lymphocytosis was present, but no eosinophilia and no atypical plasma nor myeloma cells were seen in the smear. Immaturity of the red or white blood cells could not be demonstrated. The rouleaux formation, which has been described as being characteristic of this condition, was very evident. The total serum protein was considerably elevated with characteristic reversal of the albumin-globulin ratio. X-ray studies of the chest and spine failed to reveal the characteristic changes on first observation. In studies of the skull, however, the characteristic changes were immediately obvious despite the fact that the patient had no local symptoms. The great value of studies of the bone marrow by sternal puncture is evident.

No specific therapy for this relatively rare disease is available. X-ray irradiation over localized painful areas is of some symptomatic value. The etiology is still obscure. Generally, it has been regarded as a neoplasm originating from some cell of the bone marrow. By other writers it has been related to an atypical leukemia, and because of this conception the term myelomatosis has been used.