

## SECONDARY CLOSURE OF WOUNDS

lation of the entire edge of the wound by pressure from various devices designed to prevent the sutures from cutting.

6. In the presence of considerable oozing or gross contamination, a small rubber drain is inserted through the skin edges at the dependent part of the wound.

7. A gauze dressing is applied to the wound, and over this, sterile mechanic's waste (cotton) is placed to assure an even distribution of pressure. Pressure is then applied with a woven elastic bandage.

8. If the wound involves a joint, the joint is splinted to insure absolute immobility.

9. The wound is inspected for infection after five days, and if it is healing well, the pressure dressings and splint are reapplied. The sutures are not removed for two or three weeks, even if they tend to cut partially through the tissues. The incidence of infection in these cases is low, and the results are good when pressure and immobilization can be attained, even when the wounds are closed under great tension.

### SUMMARY

The effective secondary closure of wounds shortens the duration of convalescence and minimizes deformity from contracture of wounds. Whenever possible, closure of a defect by suture is preferable to the grafting of skin.

## CHRONIC LARYNGEAL STENOSIS

### *Report of a Case Treated by Skin Grafting*

PAUL M. MOORE, M.D.

Chronic laryngeal stenosis is a diminution in the size of the airway through the larynx, due to formation of scar tissue and adhesions in the larynx as a result of trauma or disease. The same condition may occur immediately below the larynx in the upper end of the trachea. According to Chevalier Jackson<sup>1</sup> 75 to 85 per cent of his cases are the result of high tracheotomy. For years he and his many followers have emphasized the importance of placing the tracheotomy tube as low in the neck, and consequently as far from the laryngeal structures, as possible. If circumstances should demand a fairly high emergency tracheotomy, this should be changed to a low tracheotomy as soon as the patient can reach a properly equipped operating room. Even in a dire emergency, however, one can make the opening in the trachea well below the danger level

by using Jackson's technic. Other traumatic causes are external injuries and wounds of the larynx and the effect of unrecognized foreign bodies in the larynx. Chronic laryngeal stenosis may also be produced by ulcerative laryngitis, diphtheria, perichondritis, syphilis, or tuberculosis.

At one time treatment entailed repeated and more or less forceful dilatations over a prolonged period of time. Unless the dilatations were continued, the dilated lumen subsequently contracted to its former inadequate size. The patient was forced to continue wearing a tracheotomy tube.<sup>2,3</sup>

The endolaryngeal method was greatly advanced by the development of the soft rubber, core molds of Jackson.<sup>1,4</sup> Even this required a long period of treatment and repeated changes to a larger size until the desired result was obtained.

Laryngostomy and tracheostomy with excision of the offending scar tissue gained in importance after Schmiegelow<sup>5</sup> combined it with placement of an India rubber drain within the involved area. The drain was anchored by transfixing the larynx and drain with a silver wire. The neck wound was then closed, and after weeks or months the drain and wire were removed through the mouth by direct laryngoscopy.

The greatest progressive step, however, was made by Arbuckle<sup>6,7</sup> when he combined the external operation and excision of scar tissue with the placement of a skin graft over the denuded area. This materially shortened the duration of treatment, obviated repeated manipulations, and produced a permanent recovery. Figi<sup>8,9</sup> modified Arbuckle's method, and it was his procedure which was followed in the case reported.

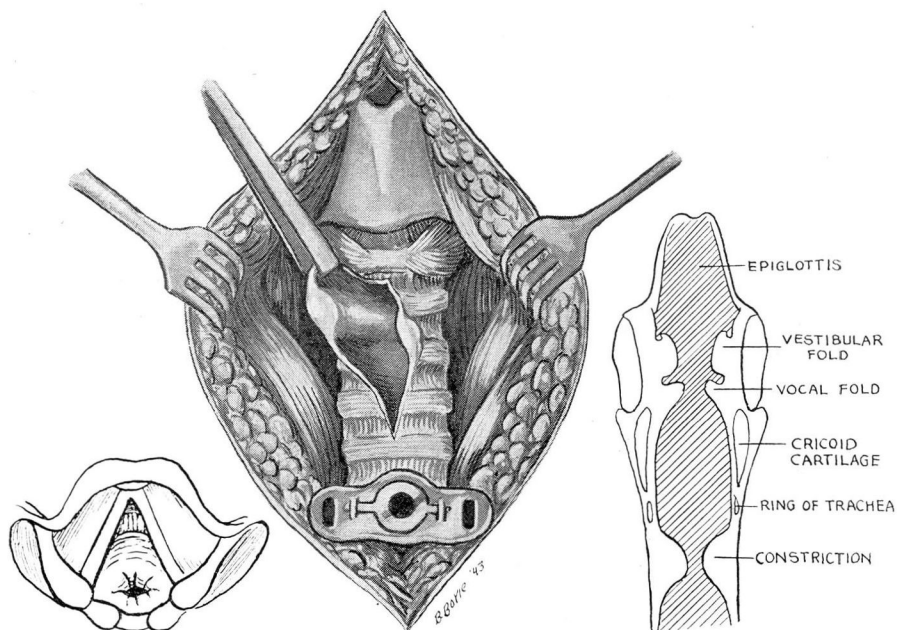
#### CASE REPORT

**History.** A white man, aged 27, was first seen on December 19, 1941. He gave a history of multiple papillomata from the age of 3. At the age of 5 a tracheotomy was done, and he wore the tracheotomy tube for a number of years. The last removal of a papilloma was at the age of 16, and at approximately the same time the tracheotomy tube was removed. He had no trouble until six weeks before consultation. At that time he had a slight cold, sore throat, and laryngitis. This persisted, and two weeks after onset he felt something "give" in his throat during a severe paroxysm of coughing. He coughed up a little blood-tinged sputum and became severely dyspneic. Afterward, he had recurrent episodes of coughing and marked dyspnea and was unable to work. Between episodes his breathing was fairly good, but he noted progressive weakness and loss of appetite and weight.

**Physical examination.** Examination showed a thin white man weighing 120 pounds. Blood pressure was 140 systolic and 90 diastolic. The lung fields were clear on auscultation and x-ray examination. There was a severe respiratory stridor. The nasal septum was deviated to the right causing partial obstruction. The nasal passages were

## CHRONIC LARYNGEAL STENOSIS

normal otherwise, and the sinuses were clear to transillumination. Nasopharynx and ears were normal. The faucial tonsils were small and buried. The crypts contained debris. Mirror laryngoscopy showed a small web between the vocal cords anteriorly. The left cord was somewhat injected, but both cords were smooth and moved normally. The subglottic region was not well visualized.



**Operation.** On December 20, 1941 a direct laryngoscopy was performed, and a stenosis of the larynx was found in the subglottic region. The airway was very small and situated posteriorly. A piece of tough scar tissue was removed for biopsy and the airway enlarged anteriorly by electrocoagulation. The tissue removed showed scar tissue covered with normal tracheal mucosa and no evidence of a new growth.

On December 29 another direct laryngoscopy was done. At this time the airway was large enough for a 3.5 mm. bronchoscope to be passed. This was followed by a 4 mm. bronchoscope. The tracheobronchial tree was normal below the stenosis. The stenotic area was again subjected to electrocoagulation.

The stenosis re-formed, however, and a tracheostomy was performed on February 17, 1942, under avertin-ether anesthesia. A midline incision was made from the thyroid cartilage to the suprasternal notch and carried down to the anterior tracheal wall by sharp and blunt dissection. The opening for the tracheostomy was made below the previous opening and as low in the neck as possible. A longitudinal incision was then made through the trachea from the cricoid cartilage down to the tracheal ring just above the new tracheostomy opening, thus leaving a bridge of cartilage above the tracheostomy tube to hold it in place. A diaphragm of dense scar tissue about 1 cm. thick was found just below the level of the cricoid cartilage. This was attached to the anterior and lateral walls. The posterior wall where the opening in the diaphragm was located was normal. The cartilaginous framework of the larynx and trachea was not deformed. The scar

tissue was removed by sharp dissection. A mold of air-foam rubber was cut to fit the trachea. A Thiersch graft from the left upper arm was wrapped around it and fastened with silk sutures as advised by Figi. This was then placed in the trachea so that it extended above and below the denuded area. The mold was then anchored to the tracheotomy tube with heavy linen thread. The wound was closed in layers. Through and through sutures were considered unnecessary, because the tracheotomy tube prevented the mold from slipping down, and the thread anchored to the tube kept it from slipping up into the glottis.

On the tenth postoperative day the thread anchor to the tracheotomy tube was cut, and the air-foam rubber mold was removed through the glottis by direct laryngoscopy. A 30 F. Jackson core mold was inserted and anchored to the tracheotomy tube.

The patient was discharged on the thirteenth postoperative day. Three days later (six days after the insertion of the core mold) he returned complaining bitterly of pain and inability to swallow. The core mold was removed by direct laryngoscopy. The air-foam rubber mold previously used with the skin graft was covered with the finger from a rubber glove and inserted through the laryngoscope. It was again anchored in place by a linen thread tied to the tracheotomy tube. When he was discharged two days later, he was swallowing normally and was quite comfortable. Three weeks later the mold was removed under direct laryngoscopy, and the following week the tracheotomy tube was removed. It is now almost two years since the tracheostomy. He has had no further trouble and has been working regularly for over a year.

#### SUMMARY

A case of subglottic laryngeal stenosis treated with excision of the scar tissue and skin grafting is presented. This technic eliminates repeated manipulations and shortens the period of treatment. The patient was hospitalized for fifteen days with complete recovery in a period of thirty-nine days.

#### REFERENCES

1. Jackson, Chevalier and Jackson, Chevalier L.: *The Larynx and Its Diseases*. (Philadelphia: W. B. Saunders, 1937).
2. Clerf, Louis H.: Cicatricial stenosis of the larynx. *Ann. Otol., Rhin. & Laryng.* 42:1 (March) 1933.
3. Negus, V. E.: Treatment of chronic stenosis of the larynx with special reference to skin grafting. *Ann. Otol., Rhin. & Laryng.* 47:891 (December) 1938.
4. Cummings, Geo. O.: Atresia of trachea following injury: Dilatation with core molds. *Ann. Otol., Rhin. & Laryng.* 49:801 (September) 1940.
5. Schmiegelow, E.: Stenosis of the larynx; a new method of surgical treatment. *Arch. Otolaryng.* 9:473 (May) 1929.
6. Arbuckle, M. F.: Cicatricial stenosis of the larynx. A proposed method of treatment with report of three cases. *Arch. Otolaryng.* 8:686 (December) 1928.
7. Arbuckle, M. F.: The cause and treatment of cicatricial stenosis of the larynx. *Ann. Otol., Rhin. & Laryng.* 39:134 (March) 1930.
8. Figi, Frederick A.: Epithelioma of the larynx, pharyngotomy and diathermy: depression of frontal region. Fat transplant; loss of nasal ala and upper lip, reconstruction; stenosis of the larynx. Laryngofissure and skin graft. *Surg. Clin. North America* 11:829 (August) 1931.
9. Figi, Frederick A.: Chronic stenosis of the larynx with special consideration of skin grafting. *Ann. Otol., Rhin. & Laryng.* 49:394 (June) 1940.