

## NODULAR PAPILLOMATOUS BROMODERMA

EARL W. NETHERTON, M.D.

Bromides are prescribed more often than many other common drugs and are also ingredients of many proprietary preparations. However, nodular, papillomatous, fungoid bromoderma is relatively uncommon. This type of bromide eruption occurs most often in women. The lesions usually appear after weeks or months of continuous bromide ingestion. There is no correlation between the amount of drug ingested, duration of medication, and onset of the eruption. The nervous and psychic manifestations of brominism may be present but are often absent. Likewise, constitutional manifestations of brominism may occur without an associated papillomatous bromoderma. A history of ingestion of bromide or sedatives is an important aid in the differential diagnosis. It should be pointed out, however, that a habitué of proprietary sedatives is often reluctant to admit ingestion of drugs.

If the practitioner is unfamiliar with this lesion, he is most apt to consider it a carbuncle or some unusual pyogenic infection and may subject the patient to a needless operation. The most striking feature of this type of bromoderma is the high incidence of severe pain and tenderness of the lesions. The patient frequently walks with a limp and may come to the physician's office on crutches. The pressure of bandages and clothing causes discomfort, although occasionally pain is not a prominent symptom.

A painful, nodular, papillomatous, pustular lesion not surrounded by acute cellulitis should indicate the necessity for considering bromoderma in the differential diagnosis. The initial lesion is a small, light red to yellowish red papule or group of painful papules. These papules become papulopustules, enlarge slowly by peripheral extension, may become confluent, and terminate in large, rounded or oval, irregular, fungoid or papillomatous, raised lesions. Usually the margins of the larger lesions are rather sharply demarcated and are surrounded by a narrow zone of erythema. During the early and more active stage of development the surface of the lesions is studded with small pustules. The exudate has a foul odor. As the pustules dry up, comedo-like plugs form, or if the pus is expressed, numerous small sievelike depressions remain on the surface of the lesion. This results in a cribriform appearance of the surface characteristic of this type of bromoderma. Scarring and hyperpigmentation are common sequelae of nodular bromoderma.

Areas of predilection are the lower anterior and lateral surfaces of the legs. Large fungoid and nodular lesions of bromoderma sometimes

occur in nursing infants whose mothers are taking bromides, and in the child the lesions show a predilection for the face and extremities. The eruption is usually bilateral, although it may be unilateral. It may consist of one or many large fungoid lesions with a few smaller papulopustules, or it may be extensive with numerous lesions. In most cases observed at the clinic the eruption consisted of few lesions. The papillomatous type of bromoderma not infrequently develops at the site of trauma.

Fungating nodular bromoderma must be differentiated from blastomycosis cutis, late nodular syphilid, tuberculosis verrucosus cutis, dermatitis vegetans, and carcinoma. Of these diseases blastomycosis most closely simulates papillomatous bromoderma. The margins of lesions of cutaneous blastomycosis are more sharply demarcated and more perpendicular. The abscesses are smaller and located along the rolled sharp margins. The surface of blastomycosis is more papillomatous and in the moist type bleeds easily. The exudate from bromoderma has a more offensive odor and does not contain the budding forms of blastomyces. Lesions of blastomycosis are not usually painful.

The nodular serpiginous margin of a bromoderma may simulate roughly that of late syphilid. The syphilid is of duller color and consists of a granulomatous infiltration which involves the whole thickness of the skin. The punched-out marginal ulcers and the atrophic scar with an areola of hyperpigmentation usually present in the older portion of a late syphilid do not occur in bromoderma.

Lesions of tuberculosis cutis are usually more verrucose, more chronic, less painful, and usually not so purulent. Likewise the margins are infiltrated and granulomatous.

Dermatitis vegetans is a rare, chronic, purulent, vegetating process, which usually involves the folds of the body, particularly the genitorcral regions and axillae. Occasionally a vegetating, papillomatous, pyogenic dermatitis involving the legs may roughly simulate a bromoderma; however, the presence of painful papulopustules and nodules is an important and distinctive characteristic of bromoderma.

Although a dry papillomatous area of a chronic bromoderma may simulate carcinoma cutis, the possibility of this error in diagnosis would be obviated if the whole eruption were carefully evaluated, since bromoderma does not tend to undergo malignant degeneration.

Prompt relief of pain and the rapid involution of the lesions after the administration of sodium chloride are observed in bromoderma and not

## NODULAR PAPILLOMATOUS BROMODERMA

in the other lesions mentioned. In the clinical investigation of doubtful cases microscopic examination of the exudate and other well known laboratory procedures should be utilized.

Sodium chloride therapy for bromoderma advocated by Wile and his associates is exceedingly satisfactory and one of the most outstanding contributions to dermatologic therapeutics by contemporary dermatologists.<sup>1,2</sup> Untreated bromoderma subsides slowly, often requiring weeks to disappear after bromide ingestion has been discontinued.

The presence of bromine in the urine or a high bromine blood level, although not conclusive, is strong supportive evidence in doubtful cases of bromoderma. A satisfactory method of determining the bromine level of the blood serum is now available and is more valuable than examination of the urine for bromine.<sup>3,4</sup> Wile emphasized that bromine cannot always be found in the urine of patients with brominism until after the administration of sodium chloride.<sup>2</sup> He also cautioned against the production of nephritis by too rapid displacement of bromine by administration of large amounts of sodium chloride.

### CASE REPORTS

**Case 1.**—A woman, aged 45, came to the clinic because of an "ulcer" on the left leg. During the past year she was depressed and cried easily. During the past six months she lost 15 pounds. For three years she suffered from hot flashes and during the past year menstruated only three times. Six weeks prior to admission a painful red papule developed on the calf of the left leg, according to the patient at the site of a mosquito bite. The lesion gradually enlarged and became more painful, and a dark area developed at the apex. No pus was obtained upon incision, after which the lesion enlarged more rapidly, and small pustules appeared on its surface. Two roentgen ray treatments were given without benefit. The lesion continued to enlarge and became so painful that the patient was unable to walk without crutches.

Since cultures of exudate showed pure growth of *Staphylococcus albus*, wet dressings of allantoin solution were applied, after which the lesion became more painful and the erythematous areola more prominent. Because of lack of response to treatment, her surgeon attempted to prevent spread of the "infection" by producing an elliptical incision with the cautery needle around the lower, more rapidly advancing portion of the lesion. An iodoform pack was placed in the incision. At the same time a smaller, painful papulopustule on the upper left calf was excised.

A few days later she was seen in the department of dermatology. A dime-sized, clean, superficial ulcer involved the upper portion of the left calf. This was a postoperative wound. Lower on the lateral and posterior surface of the same leg was an irregular, papillomatous, vegetating, pustular lesion, about the size of a silver dollar and surrounded by a zone of erythema. The margin was raised, sloping, and fairly well demarcated. The peripheral portion was papillomatous and in places studded with small pustules. No part of the surface was cribriform. The central portion was brownish red, depressed, and scarred. There was a gaping, elliptical incision below the lesion (fig. 1).

The pain was severe, and the slightest pressure or movement caused discomfort greater than would be warranted by the appearance of the lesion.

A clinical diagnosis of bromoderma was made. When questioned about ingestion of sedatives, the patient promptly admitted taking a proprietary preparation containing

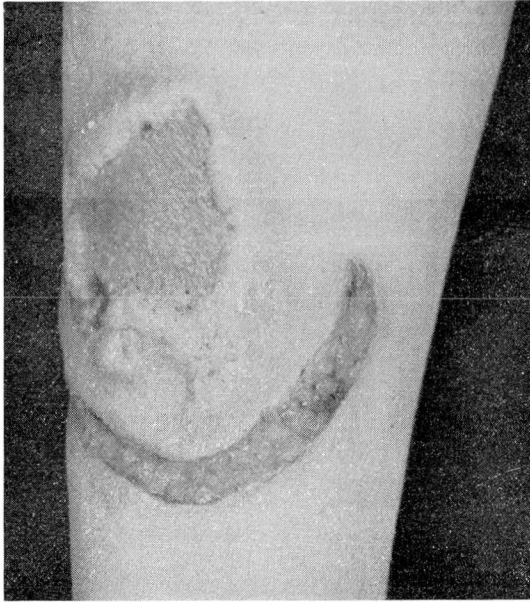

FIG. 1

sodium and potassium bromide. In fact she produced a bottle of the remedy during the interview. Examination of the urine by the Belote technic showed the presence of bromine. Wassermann and Kahn reactions of the blood were negative. Other laboratory investigations showed normal findings.

Within five days after intravenous administration of decinormal saline the pain completely disappeared, and within three weeks the lesion healed.

**Case 2.**—A woman, aged 43, came to the clinic on November 13, 1942 because of a painful lesion on the right leg. For the past eighteen months she had been taking a brown, salty liquid for “nervous exhaustion.” In July she scratched the lateral surface of the right leg on a rosebush. Within a week a papule developed at the site of the injury, became very painful, and continued to enlarge slowly until she came to the clinic. During the last week of October a group of painful papulopustules developed on the midportion of the right antetibial area. The eruption was treated with moist dressings, sulfathiazole salve, and about eight roentgen ray treatments, none of which was beneficial.

There was a rounded, palm-sized, raised, light red, crusted, pustular, poorly demarcated, very painful lesion on the lateral surface at about the junction of the middle and the lower third of the right leg. A narrow erythematous areola surrounded the lesion. The crusts were yellowish, thin, and loosely adherent. On the noncrusted surface

## NODULAR PAPILLOMATOUS BROMODERMA

were small pustules. The newer lesions on the right shin consisted of a group of pea-sized, light red, tender papules and papulopustules (fig. 2). The patient was restless, emotionally unstable, and complained of the painfulness of the cutaneous lesion. A diagnosis of bromoderma was made.

The bromide level of the blood serum was over 100 mg. per 100 cc. The patient lived out of the city and did not wish to remain for intravenous saline therapy. One gram of sodium chloride in enteric coated pills was administered orally four times a day. The nerve sedative was discontinued. Response to treatment was entirely satisfactory but was not so prompt as with the use of the intravenous administration of saline.

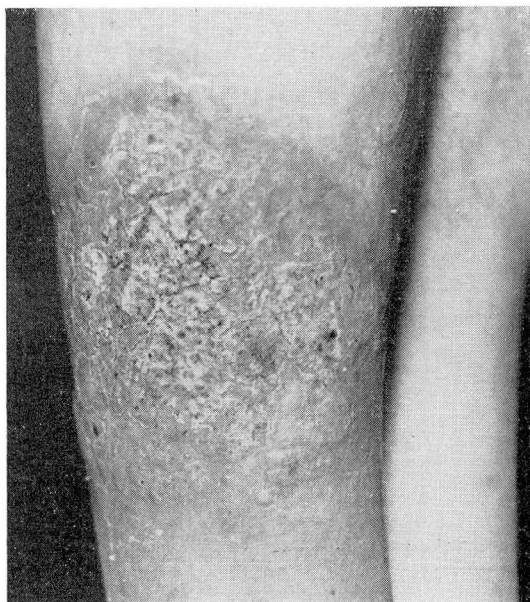

FIG. 2

**Case 3.**—A married woman, aged 32, was seen in August 1941 with the chief complaint of “sores” on the right leg of fifteen weeks’ duration. She was neurotic and according to the referring physician was difficult to manage. She denied taking bromides but had taken phenobarbital for several years. Her physician had not prescribed bromides. The eruption had appeared as a small, crusted, pustular lesion on the right shin shortly after shaving the legs. The lesion enlarged gradually by peripheral extension and was tender but not painful. It was thoroughly curetted in June but returned within ten days and became larger.

On the midportion of the right antetibial region was a palm-sized, oval, well demarcated, chronic inflammatory lesion. The central portion was pink, depressed, and scarred. The periphery was papillomatous, pustular, and partially covered with brown, seborrheic, loosely adherent scales. The pustules were small. The margin of the lesion was raised but not sharply above the normal skin. There was an erythematous areola. The youngest papillomatous, fungoid nodule was confluent with upper lateral portion

of the original lesion. A similar quarter-sized lesion was present below and to the right of the original plaque (fig. 3).

Both blastomycosis and bromoderma were considered tenable in the differential diagnosis. Although the clinical features were more suggestive of bromoderma than blastomycosis, the lack of extreme tenderness and pain commonly present in bromoderma was confusing. Repeated examination of smears from pustules failed to demonstrate blastomyces, and cultures failed to grow the fungus. Despite the denial of bromide ingestion a blood serum bromine level was determined and showed 91 mg. bromine in 100 cc. of blood serum. The Wassermann and Kahn reactions of the blood were negative.

A final diagnosis of bromoderma was made, and the patient returned to her physician for saline therapy. No subsequent follow-up was obtained.

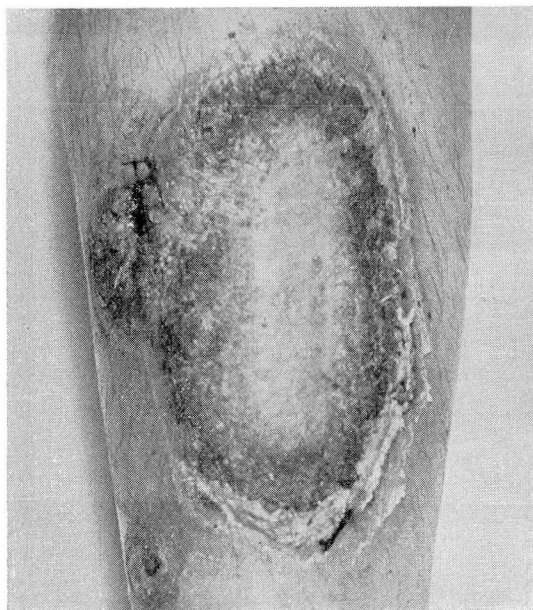

FIG. 3

**Case 4.**—A woman, aged 59, came to the clinic on March 17, 1938 because of a very painful eruption on the lower right leg. In 1933 she bruised the right shin, and within a week an exceedingly painful, red area appeared at the site of the injury. A large, very painful, pustular and crusted area developed on the anterior surface of the right leg, and a few months later a similar eruption appeared on the lower part of the left leg. After about two years the eruption disappeared leaving hyperpigmented scars. In April 1937 she again injured the right shin, and in a few days painful lesions similar to those that developed in 1933 appeared near the injury. The eruption spread, and the pain became so severe that she remained in bed most of the time from August 1937 to January 1938. She had a poor appetite, was nervous, and had frequent fainting spells. About the middle of February 1938 she injured her right leg again. Large bullae developed, and within three days the eruption spread to encircle the leg just above the

## NODULAR PAPILLOMATOUS BROMODERMA

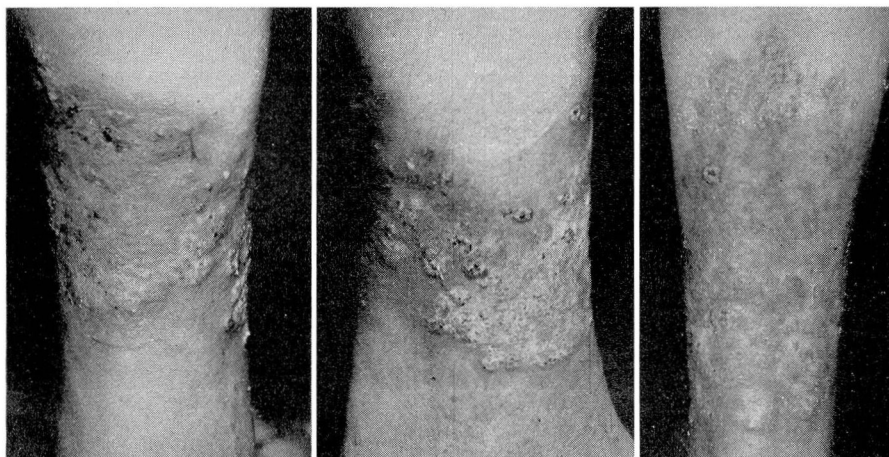


FIG. 4

ankle. The pain was severe, and the odor of the purulent exudate became offensive. During the past ten years she took a great deal of medicine, including proprietary preparations for stomach trouble, but denied taking any medicine for about five months before she came under our care. During September 1937 she took white tablets but did not know what they contained. History of drug ingestion in this case was confusing and unsatisfactory.

The eruption, which encircled the right leg just above the ankle and involved a hyperpigmented scar on the right shin, consisted of light red, vegetating, papillomatous nodules and erythematous areas studded with small pustules and match-head to pea-sized papulopustules. The nodular, more papillomatous portions of the eruption were sharply demarcated, but the margins were sloping. There was a narrow areola of erythema (fig. 4). The eruption was exceedingly painful, and the exudate had an offensive odor.

The Wassermann and Kahn reactions of the blood were negative. Cultures for blastomyces failed to grow any fungus. The blood bromine level could not be obtained, and the urine was not examined. Although the history of drug ingestion was not satisfactory, it was determined that she suffered from fainting spells, chronic stomach trouble, and other vague complaints, and that for years she had taken medicine periodically and at times regularly for several months. The nodular, vegetating, pustular, exceedingly painful eruption and the offensive odor of the exudate were sufficiently characteristic to permit a clinical diagnosis of bromoderma. After two intravenous injections of normal saline solution the pain decreased, and the patient returned to her family physician for further saline therapy.

### COMMENT

Bromine may cause an acneform eruption, erythema nodosum-like nodules, an erythematous vesiculo-bullous dermatitis, or papillomatous, nodular, fungoid lesions. The latter type of bromoderma is rather un-

common. Papillomatous bromoderma may at times be treated surgically before the exact nature of the lesion is recognized. This occurred in two of the cases herein reported. In a discussion of a case of bromoderma presented before the New York Dermatological Society, Traub referred to a woman who had extensive bromoderma on the legs.<sup>5</sup> One of the granulomatous tumors was diagnosed as malignant degeneration. Amputation of the leg was advised but was refused by the patient. After the eruption was identified and sodium chloride was administered, the lesions disappeared completely. In the same discussion Whitehouse cited two similar cases in which amputation of a leg was advised because of an erroneous diagnosis of sarcoma.

Unlike most drug eruptions the lesions caused by bromine and iodine do not disappear quickly after the drug is withheld. Prior to the outstanding contribution of Wile, Wright, and Smith there was no satisfactory treatment for bromoderma, consequently the fungoid cutaneous lesions caused by bromine would often last weeks or months after the ingestion of the drug had been discontinued.<sup>1</sup> These authors were able to corroborate observations of Laudenheimer, von Wyss, and others, whose researches demonstrated that the ingestion of bromide led to a gradual accumulation of the drug in the tissues and fluids of the body, caused by displacement of chlorine by bromine. Because of this phenomenon Laudenheimer attempted to explain the systemic symptoms of brominism as a manifestation of chloride deficiency. Wile and his associates were able to substantiate Laudenheimer's assumption by showing that introduction of large amounts of chloride was followed by gradual return of the normal chlorine content of the tissues and body fluids, relief of symptoms of brominism, and beneficial effect upon bromodermas. They also found that the normal chlorine content of the urine must be determined for each patient. With the ingestion of bromide the chlorine content of the urine began to increase on about the second or third day and continued to increase up to about twice the normal level; then there was a gradual return to normal even though the drug was continued. The normal chlorine level of the urine was not reached until after the drug was withdrawn. They were unable to demonstrate bromine in the purulent exudate of bromoderma or a sensitization to iodides and bromides by intracutaneous and scarification tests. They stated that "The local phenomena of iododerma and bromoderma do not find their explanation on simple bacterial nor simple chemical grounds. The ultimate explanation probably lies in a complex biochemical reaction. The classification of such cutaneous phenomena, however, as true sensitization or allergy is as yet unjustifiable in the light of present



## NODULAR PAPILLOMATOUS BROMODERMA

knowledge." Two decades have passed since the article of Wile and his associates was published, and, so far as I have been able to determine, the mechanism of the production of iododerma and bromoderma remains obscure.

In a second report Wile confirmed this early observation.<sup>2</sup> He treated three women who presented the mental symptoms of brominism together with nodular bromide lesions of the skin by the administration of decinormal saline solution at two and three day intervals. Although bromine could not be demonstrated in the urine prior to the administration of saline solution, it was present after the first two injections. Likewise mental symptoms were promptly relieved with diminution and gradual disappearance of the cutaneous lesions. In the first case treated symptoms of shock developed almost immediately after administration of 500 cc. of decinormal saline solution intravenously. The next day a catheterized specimen of urine contained many casts and large amounts of albumin. Wile attributed these reactions to the irritating effect of the rapid production of chemical changes in the tissues and the rapid liberation of bromine with the passage of the bromine salt through the renal epithelium. He later cautioned against rapid liberation of bromine from the tissues by too extensive saline therapy.

Belote described a simple color test for bromine in body fluids as follows:<sup>6</sup> To urine suspected of containing bromine is added a few crystals of potassium permanganate. The urine is agitated, and a few drops of concentrated sulfuric acid is added. Small pieces of dried filter paper previously soaked in a saturated solution of fluorescein in 60 per cent acetic acid are moistened with 2 per cent acetic acid and held over the mouth of the test tube containing the urine, potassium permanganate, and sulfuric acid. If bromine is present, the yellow paper becomes bright pink.

### SUMMARY

The frequent ingestion of bromides in prescribed medication and proprietary preparations occasionally causes an eruption, which must be differentiated from blastomycosis cutis, late nodular syphilid, tuberculosis, verrucosis cutis, dermatitis vegetans, and carcinoma. Until Wile and his associates showed that the intravenous administration of decinormal saline solution caused the rapid disappearance of the lesions, there was no satisfactory treatment for bromoderma, which would often persist for weeks or months after the ingestion of the drug was discontinued. Recognition of papillomatous bromoderma will prevent surgical interference to which these lesions are at times subjected.

REFERENCES

1. Wile, U. J., Wright, C. S., and Smith, N. R.: A preliminary study of the experimental aspects of iodid and bromid exanthems. *Arch. Derm. & Syph.* 6:529 (Nov.) 1922.
2. Wile, U. J.: Further contributions to the experimental aspects of iodid and bromid exanthemas. *Arch. Derm. & Syph.* 8:407 (Sept.) 1923.
3. Katzenelbogen, S., and Goldsmith, H.: Hematoencephalic barrier; diagnostic value of bromide test in mental disease. *Am. J. Psych.* 10:1045, 1931.
4. Katzenelbogen, S., and Czarski, T.: Improved colormetric method for determination of bromide concentration in blood and cerebrospinal fluid. *Proc. Soc. Exp. Biol. and Med.* 32:136, 1934-35.
5. Bromoderma, presented by Dr. J. G. Eller. *Arch. Derm. & Syph.* 32:152 (July) 1935.
6. Belote, G. H.: Simple color test for bromine in body fluids. *J.A.M.A.* 88:1696 (May 28) 1927.

PARIETAL NEURALGIA

R. H. McDONALD, M.D.

Pain referred to a cutaneous area is one of the commonest complaints heard in any diagnostic clinic. When the reference of pain is over the thorax or abdomen, it is our common habit to think of the possibility of some visceral pathologic state, which, by means of a nervous connection involving the spinal cord, refers itself to the cutaneous surface. The reference of visceral pain through the efferent nervous connections to the spinal cord and its spread therefrom to the cutaneous sensory area supplied by the same cord segment or even to adjoining segments, if the stimulus be of sufficient intensity, has been suggested by the work of McKenzie<sup>1</sup>, Head<sup>2</sup>, and Sherren<sup>3</sup> and has found wide acceptance throughout medical literature. These cutaneous zones of somatic reference have been described on the basis of embryonic development and charted with a view to their use in diagnosis. Practically, however, it has been shown that they are of relatively little value, and constant relationships between visceral pathologic states and cutaneous manifestations have not been consistent. In general the principle still holds that clinical investigation must first envision the possibility of such an origin of pain, to be excluded only after the most thorough search. Frequently the most careful search will fail to uncover any such visceral basis, and in these the possibility of pain of parietal origin must be considered. Failure to appreciate the possibility of parietal origin for distress may lead to an unwarranted diagnosis of visceral disease with the sequelae of needless surgical procedures. Repeated examples of this, usually in the abdominal area, are commonplace, and this frequently explains the persistence of symptoms after repeated surgical attempts for relief. Such patients are frequently regarded as being