

LONG SURVIVAL OF A PATIENT WITH CEREBELLAR MEDULLOBLASTOMA AND MALIGNANT GOITER TREATED BY ROENTGEN THERAPY

Report of a Case

U. V. PORTMANN, M.D., and R. H. THOMPSON, M.D.

Department of Therapeutic Radiology

The following case report is of interest because the patient has survived eleven years following roentgen therapy for cerebellar medulloblastoma and four years following treatment for malignant adenoma of the thyroid gland.

Case Report

A woman, aged 27, was first seen at Cleveland Clinic Hospital by Dr. W. James Gardner on October 2, 1935. She was semicomatose, restless, and responded to questions only in monosyllables. She had divergent strabismus, papilledema, paresis of the left side of the face, left arm and leg, a positive Babinski sign, left patellar clonus, and bilateral ankle clonus. Laboratory examinations of blood and spinal fluid gave negative findings. The patient had no fever.

Five weeks prior to admission she had complained of attacks of frontal headaches which had increased in frequency and severity for at least a week, then changed in location to the occipital region. These attacks were associated with diplopia, vertigo, and occasional vomiting. She had given up her position as a public school music supervisor to rest in bed. Her symptoms had increased, however, and she entered a hospital and was examined by Dr. Louis J. Karnosh, who considered the diagnosis consistent with encephalomyelitis. He advised removal to Cleveland Clinic Hospital, where she was admitted in the condition described. Further questioning elicited the information that a few weeks prior to the onset of symptoms she had been struck on the head by a falling suitcase. This injury indicated the possibility of a frontal subdural hematoma.

On the third day after hospital admission the patient suddenly became somnolent and soon stopped breathing, although the pulse remained regular and of good quality. Artificial respiration and stimulants brought about normal respiration in about a half-hour, and she was taken to the operating room. A bilateral trephine was done over each parietal eminence. No evidence of hematoma could be found. Brain cannulas were inserted through the openings, and 90 cc. of cerebrospinal fluid was replaced by air. The wounds were closed and ventriculograms taken. The films revealed an obstructive hydrocephalus in the region of the fourth ventricle. A wide occipital craniotomy revealed a bulging mass in the left cerebellar hemisphere displacing the right lobe and herniating it through the foramen magnum. The aqueduct was patent. A brain cannula was introduced into the left cerebellar lobe, and at a depth of 4.0 cm. a cyst was drained of about 40 cc. of thick yellow fluid. As the patient's condition precluded other operative procedures, the wound was closed. A diagnosis of cystic glioma of the left cerebellar hemisphere was made.

Postoperatively she had headaches, and other signs of increased intracranial pressure necessitated one lumbar puncture and a few intravenous injections of sucrose solution.

Diplopia, nausea, and projectile vomiting persisted, and she had an attack of paroxysmal tachycardia. It was considered advisable to aspirate the cyst again under local anesthesia. At this time only a few drops of fluid were removed, and a fragment of necrotic tumor tissue was obtained for microscopic study. From this material Dr. Allen Graham made a diagnosis of medulloblastoma which has been confirmed by several other pathologists (fig. 1).

The patient was then given protracted roentgen therapy, the course being completed in December, 1935. Three areas of the occipital region were each given a total of 1350 roentgens (skin dose), the cervical, thoracic, and lumbar spinal areas each receiving 850 r. The physical factors were 200 Kv. and filter equivalent to 1.0 mm. h.v.l. copper. Four months later (April, 1936) the patient returned for a second course of roentgen therapy. She could walk without support, but change of position caused nausea. At the second course of treatment the occipital fields received 1500 r. and those along the spine each 600 r. She continued to improve and resumed teaching. Her gait was somewhat unsteady, and there were slight nystagmus and paresis of the left hand. A third course of roentgen therapy was given during January, 1937. The occipital fields received a total dose of 1200 r. and the spinal areas each 10,000 r. A summation of the amount of roentgen therapy administered in three courses during approximately two years (December, 1935, to January, 1937) shows that the external dose to the occipital region totaled 4050 r. through three fields. The tumor dose in the cerebellum approximated not less than 6000 r. In addition the spinal fields each received 2450 r.

During the next year the patient made good progress; however, nystagmus persisted, the Romberg test was positive, and she experienced difficulty in executing some movements on the piano with her left hand. She was seen periodically during the next few years, and gradually these conditions improved.

In August, 1941, a slight enlargement of the thyroid gland was noted. It was not considered significant until a year later when Dr. R. S. Dinsmore examined her and found enlargement of the left lobe of the thyroid gland and small nodules in the region of the posterior cervical lymph nodes. There had been no loss of weight or symptoms of hyperthyroidism. A biopsy was considered advisable, and a cervical gland was removed

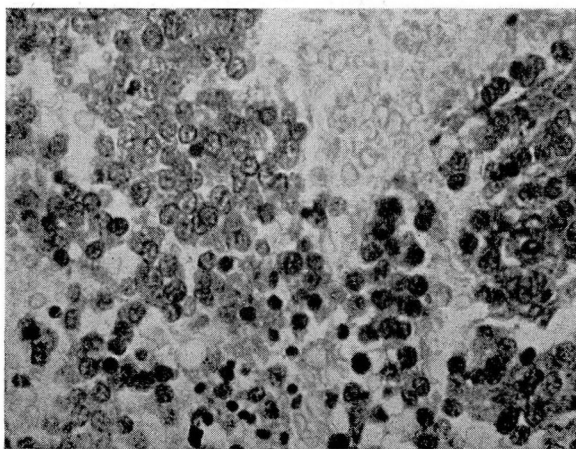


FIG. 1. Medulloblastoma. Showing uniform small cells, so-called medulloblasts, found in biopsy of cerebellar tumor x500.

for microscopic examination. Dr. Graham reported carcinoma of the thyroid gland, probably malignant adenoma (fig. 2). Thyroidectomy was considered inadvisable. The patient was given roentgen therapy to the left side of the neck, receiving 4000 r., with physical factors the same as before.

When she was seen recently (August, 1946) there was no evidence of recurrence of either the brain or thyroid gland tumors.

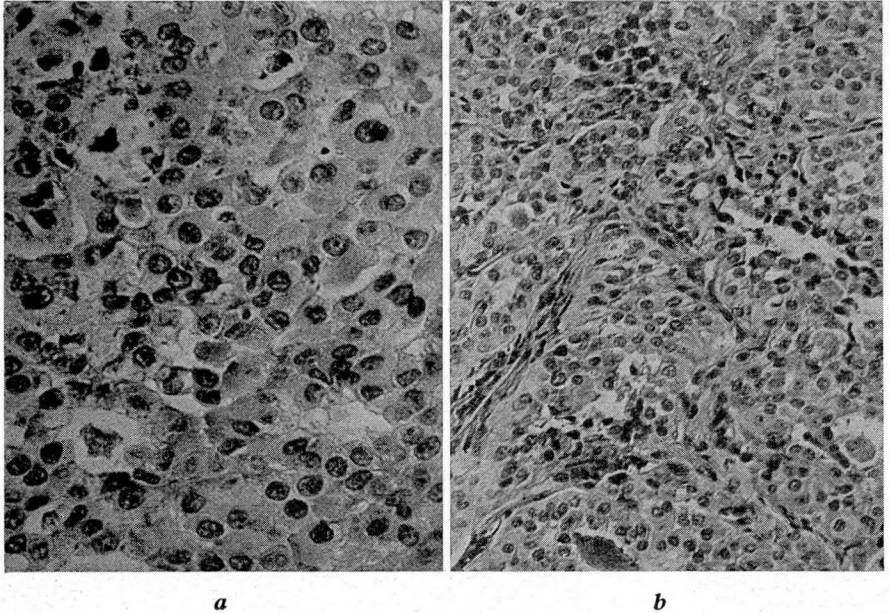


FIG. 2. Carcinoma of thyroid, probably malignant adenoma type. Sections of tissue from biopsy of left cervical gland. Showing poorly developed lumen containing colloid (a) x250, (b) x500.

Although there are reports of patients with cerebellar medulloblastoma who have lived for as long as six years, the average survival rate is about two. In our experience we have seen very few young people with malignant disease of the thyroid gland who have survived more than two years.