

DENTAL FINDINGS IN HYPOPARATHYROIDISM IN RELATION TO PATIENT AND PROGENY

Report of a Case

CHARLES A. RESCH, A.B., D.D.S.

Department of Dentistry

Hypoparathyroidism with decreased incretion of parathyroid hormone results in tetany, which is accompanied by a marked drop in serum calcium and a normal or elevated serum phosphorus. The tissues become depleted in calcium and develop neuromuscular irritability. In mild cases this may be evidenced by twitching, while in severe cases there are regular spasms of muscles with convulsions. The relationship of hypoparathyroid tetany to the teeth and oral structures has been the object of study and some animal laboratory experimentation by several investigators. Dental tissues, particularly dentine, are regarded as sensitive indicators in alteration of calcium metabolism.

As early as 1879 Magitot¹ postulated that hypoplasia of the enamel was associated with tetany. Fleischmann² in 1908 found parallel horizontal rows of bands superimposed around the teeth of children suffering from tetany. This was regarded as a type of enamel hypoplasia.

Erdheim³ and Toyofuku⁴ in 1911 made rat studies consisting of autotransplantation of parathyroid tissue, which produced changes in pulp, dentine, and enamel of the teeth. The greatest abnormality was found in the dentine. Gies and collaborators⁵ in 1917 confirmed these findings in similar experiments on young rats, demonstrating that parathyroidectomy, without disturbance of the thyroid, resulted in deficient calcification of the teeth without producing effects on the general formation and dimension. Schour and coworkers⁶ in 1937 found no retardation of eruption of the incisor teeth in albino rats. These workers demonstrated marked alteration of tooth substances appearing in the parathyroidectomized animals that survived for a long period. The alterations were particularly severe in those animals subjected to repeated pregnancy and lactation. Parathyroidectomized rats with a short period of survival, however, tended to show little change except an increase of density in the dentine. These changes occurred in the structures undergoing calcification at and following this operation. Tooth substance calcified prior to these operative procedures showed no alteration in structure. In these reports no reference has been made to the tooth structure of the progeny of the parathyroidectomized rats. There are

also no experimental data to illustrate the relation of pregnancy in hypoparathyroidism to dental pathology in humans.

In the case to be presented tetany existed over a period of twelve years, during which time the patient married and had four pregnancies, with all children living and well. The economic level of this family was low so that protein intake and fruits were either low or almost negligible. The patient stated that about once a month the children received an excess of candy.

Case Report

A woman, aged 25, came to the Clinic complaining of convulsions for a period of twelve years. She had been well until the age of 13, when at the onset of puberty she developed a large goiter. This was removed and was said to have weighed $1\frac{1}{2}$ pounds. Six months after thyroidectomy the first convulsion occurred. For several years these convulsions averaged about one a month, always associated with menstrual periods. The patient married at the age of 17, and her first child was born one year later. The patient had no convulsions during pregnancy or lactation. The second child was born two years after marriage. This child never had cod liver oil or orange juice, with the diet consisting chiefly of cereals and vegetables. Four years after marriage a third child was born, and six years after marriage a fourth child.

The patient had been seen by several physicians in the period of twelve years, and a tentative diagnosis of epilepsy had been made.

Physical examination revealed blood pressure 105 systolic and 70 diastolic. Hearing was slightly diminished. Immature cataracts were present in both eyes. The thyroid showed an enlarged, nodular, firm right lobe. Trousseau's sign was positive in less than one minute. Chvostek's sign was also positive. Reflexes were sluggish. Blood calcium was 4.9 mg. per 100 cc., blood phosphorus 7.6 mg. per 100 cc. fasting.

Dental examination revealed all the teeth present except the six-year molars, lower left bicusps, and the third molars. Dental caries was evident in several teeth. There was a total lack of oral hygiene, many teeth being covered with soft materia alba. No hypoplasia of the enamel was evident. The mucous membrane of the mouth was normal. The gingival tissues were slightly hypertrophic with some active inflammatory reaction and with slight suppuration on pressure. Soft tissue pockets were present interproximally,

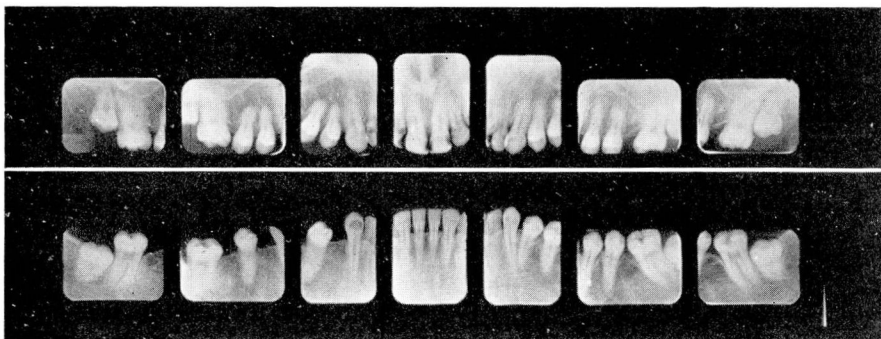


FIG. 1. Roentgenogram of teeth of patient.

but the teeth were not loose. Roentgenograms (fig. 1) revealed well formed teeth, the crowns of the posterior teeth having an unusually heavy cap of enamel. The roots of the upper bicuspid teeth were somewhat stunted. The alveolar bone appeared to be of normal density. There was little alveolar resorption around the teeth, although the teeth were traumatized by malocclusion. The cortical bone of the alveolar process (lamina dura) was sharp and distinct. The periodontal membrane space appeared of uniform, normal width. The third molars were unerupted but apparently had adequate space for eruption. They also had somewhat short roots. The D.M.F. quotient (decayed, missing, and filled) was 17.

The patient was placed under treatment, during which time the fifth child was born. Later, the teeth of all the children were examined. Roentgenogram studies were made of the teeth of two of these children. The eldest child, aged 10, showed marked malocclusion of the teeth of a class III type (Angle) prognathism. The teeth were, however, of normal shape, size, and color. There was no hypoplasia of the enamel. The gingival tissues were normal. The right bicuspid were in the process of eruption. The incisor teeth and the six-year molars had erupted. Six deciduous teeth were still present. No caries was noted in the teeth of the second dentition, although the molars presented occlusal pits of faulty calcification. A small carious lesion of the lower deciduous molar remaining was noted. The roentgenograms (fig. 2) of this patient revealed well formed teeth but somewhat smaller than average. Some teeth of the permanent dentition appeared congenitally absent. A developing upper cuspid, unerupted, presented a follicular type cystic development. The alveolar bone was of poor quality with weak trabeculae, suggesting demineralization. The periodontal membrane was uniform but thin. The cortical bone margins of the alveolar bone (laminae dura) were not prominent. The dental age approximated that of the chronologic age.

The second child, aged 9, had considerable malocclusion of the teeth with a so-called end to end bite, suggestive of retrusion of the maxilla. The gingival tissues were normal. Twelve teeth of the second dentition were present, including the incisors and first molars. Eleven deciduous teeth were present, in six of which evidence of extensive dental caries was seen. The molar teeth of the second dentition showed deep pits of inadequate calcification in the occlusal surface. Through lack of cooperation, x-ray studies of this patient were not obtained.

In the third child, aged 7, the occlusion of the teeth was normal. The soft tissues were normal. Of eighteen deciduous teeth present, seven were carious. Four molars of

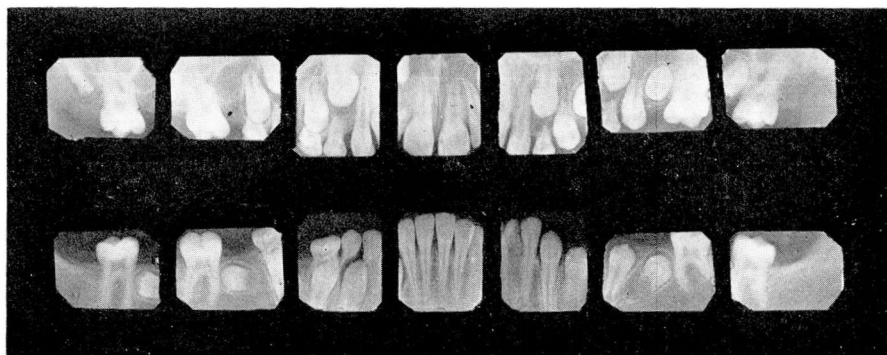


FIG. 2. Roentgenograms of teeth of child aged 10.

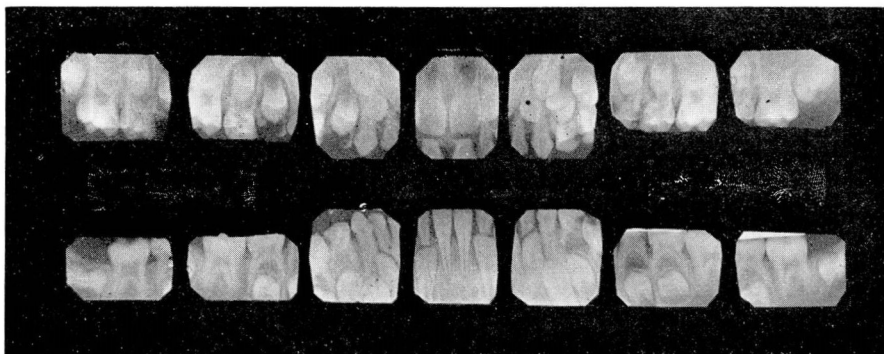

FIG. 3. Roentgenograms of teeth of child aged 7.

the second dentition, with the lower central incisors, were present and none of these were affected with dental caries. Roentgenograms (fig. 3) revealed badly carious deciduous molars, accompanied by dental sepsis. Well developed calcified posterior teeth were present, and there was no caries of the erupted six-year molars. In the upper incisors there was some sub-calcification of the dentine, as evidenced by indistinct pulp chambers. The enamel caps appeared thin and under-calcified. There was no clinical evidence of hypoplasia of the enamel of the teeth.

The fourth child, aged 5, had eighteen deciduous teeth, of which four showed caries. The lower six-year molars were erupted. The investing mucosa appeared normal. There was some malocclusion with an open bite anteriorly. Roentgenograms could not be obtained.

The fifth child, aged 22 months, was born after the patient had been under treatment for tetany throughout pregnancy. The child had sixteen deciduous teeth with no evidence of dental caries. The mouth, tissues, and occlusion of the teeth were normal.

Seven years after the patient was first seen roentgenograms of the lower arch were again obtained. In the meantime the patient had had the upper teeth removed. Unfortunately, there was no opportunity to study the extracted teeth histologically. However, a radiogram at this time revealed slight extension of the caries in three of the teeth, and in one a small new cavity was present. One lower tooth had been removed. The third molars had not erupted. No variation was detected in bone consistency other than could be explained by variation in x-ray technic. There was no evidence of alveolar resorption.

Summary

Clinical and roentgenographic findings on the dental structure of a patient with long-standing tetany, the result of hypoparathyroidism, has been presented. Studies are also presented of the five children, four of whom were born during the period of tetany symptoms. The anterior teeth of two children studied in roentgenograms revealed a suggestion of under-calcification with less dentine density and thin enamel caps. Three of the four children born during the period when the mother exhibited symptoms of tetany demonstrated malocclusion. Two of these four children had some evidence of prognathism of the mandibles

or suggestion of maxillary underdevelopment. This might also be said of the third child, who exhibited an open bite anteriorly. Dental caries was marked in the deciduous teeth of three of the children born during the period of tetany. This included the child whose occlusion was normal. The erupted teeth of the second dentition showed developmental occlusal pit defects but no caries. The eruption of the teeth was consistent with the chronologic age of the children. Anodontia was present only in the eldest child. Without fruit juices and vitamins supplementing the diet, in no instance did the gingival tissues of the patient or children show a striking deficiency state.

While under treatment, which included a diet list of high calcium and low phosphorus content, the patient had her fifth child. Dental examination of this child at the age of 22 months demonstrated no caries. All the deciduous teeth were present except the second deciduous molars, whose eruption occurs usually between 2 and 2½ years.⁷ Occlusion was normal.

Conclusions

In a patient with long-standing tetany accompanied by very poor dietary regime and oral neglect, the caries index was not significantly greater than average. Mann *et al.*,⁸ in a recent report on the activity of dental caries in malnutrition and in well nourished patients, noted that the D.M.F. quotient (decayed, missing, and filled) of the experimental malnourished group average was 4.54 as compared to the control group average of 14.94. Our patient exhibited a D.M.F. quotient of 17. Possibly dietary deficiency may have controlled caries sensitivity in this case. I prefer to believe, however, that hypoparathyroidism had no effect upon the calcium metabolism of the developed tooth, and, inasmuch as the teeth were well developed and calcified prior to the onset of tetany symptoms, no structural defects resulted from this condition, which can be considered predisposing toward dental caries in an adverse environment. The children born during the period of tetany, however, readily developed caries of the deciduous teeth, causing their early loss. This, in turn, resulted in the malocclusion of the teeth with altered jaw development. The finding that the third child had normal occlusion supports this view. The retention of the carious deciduous teeth in this child would account for the maintenance of proper space for developing teeth of the second dentition, inhibiting the tendency toward altered jaw development. The malocclusion in the fourth child appears to be congenital, possibly pernicious habits such as thumb-sucking being contributory; this was not brought out in the history. The low incidence of caries in the child is difficult to explain. The ano-

dontia of the oldest child may be related to the endocrine dyscrasia of the mother. This condition, however, may be associated with genetic variation, and as it does not involve any of the other three children but follows the Mendelian pattern, I believe that heredity rather than congenital endocrine factors should be considered primary. The period of eruption of the teeth was not disturbed, as has been pointed out by other investigators. Hypoplasia of the enamel of the teeth in either the deciduous or second dentition was not found. This does not agree with statements of early investigators. There was roentgenographic evidence of impaired calcification of upper incisor teeth of the second dentition (which completes coronal development prior to birth) and of the deciduous teeth whose calcification begins about the fourth month *in utero*. Although marked caries susceptibility appeared to be present in the deciduous teeth of the children, it could not be described as widespread or rampant, and the fact that the teeth of the second dentition showed little evidence of caries suggests some protective factor^{9,10} modifying the effects of structural defects, an inadequate diet, possibly excessive sugar intake, and poor oral hygiene habits. Although the diet as described by the patient appeared to be substandard, clinically no deficiency state could actually be considered as affecting the soft investing tissues of the mouth of the patient and children.

I gratefully acknowledge the cooperation and assistance of Dr. E. P. McCullagh of the Department of Endocrinology and Dr. H. S. VanOrdstrand of the Department of Medicine.

References

1. Magitot, L., cited by Thoma, K. H.: *Oral Pathology: A Historical, Roentgenological, and Clinical Study of the Diseases of the Teeth, Jaws, and Mouth* (St. Louis: C. V. Mosby, 1941) p. 25.
2. Fleishmann, L., cited by Thoma, K. H.¹
3. Erdheim, J., cited by Thoma, K. H.¹
4. Toyofuku, T., cited by Thoma, K. H.¹
5. Gies, W. J., et al., cited by Thoma, K. H.¹
6. Schour, I., Chandler, S. B., and Tweed, W. R.: Changes in teeth following parathyroidectomy; effects of different periods of survival, fasting, and repeated pregnancies and lactations on incisor of rat. *Am. J. Path.* **13**:945-970 (Nov.) 1937.
7. McCall, J. O., and Wald, S. S.: *Clinical Dental Roentgenology: Technic and Interpretation Including Roentgen Studies of the Child and Young Adult* (Philadelphia: W. B. Saunders, 1940) p. 106.
8. Mann, A. W., Driegin, Daniel, Spies, T. S., and Hunt, S. F. M.: Comparison of dental caries activities in malnourished and well nourished patients. *J. Am. Dent. A.* **34**:244-252 (Feb.) 1947.
9. Agnew, R. G., and Agnew, M. C., cited in American Dental Association, Research Commission: *Dental Caries: Findings and Conclusions on Its Causes and Control Stated in 195 Summaries by Observers and Investigators in Twenty-Five Countries*. Compiled by the Advisory Committee on Research in Dental Caries: Daniel F. Lynch, Chairman, Charles F. Kettering and William J. Gies. (Lancaster: Lancaster Press Inc., 1939) p. 45.
10. Briggs, E. F., cited in *Dental Caries*.⁹