

NITROGEN MUSTARD THERAPY

Report of 16 Cases Thus Treated

DONALD W. BORTZ, M.D., and RUSSELL L. HADEN, M.D.

Division of Internal Medicine

Following World War I the therapeutic value of nitrogen mustard (HN_2) was investigated by numerous workers both in this country and in Europe. In the United States Krumbhaar,¹ Pappenheimer and Vance,² and Warthin and Weller³ presented their observations on its action in certain neoplastic diseases in mice and rats. The medical profession took no advantage of the results of this research until its value was suggested by the Allied catastrophe at Bari during the invasion of Italy in 1943.⁴ At this time the actions of the mustard gases were thoroughly studied and their potentialities realized.

Shortly after this incident the first report on the clinical use of nitrogen mustard was made by Gilman,⁵ Goodman, *et al.*,⁶ who presented a series of terminal cases in which tris-amine hydrochloride had been used. In 1946 there appeared several reports^{6,7} of the value of nitrogen mustard in the management of certain types of neoplastic diseases. These articles present an excellent evaluation of the present status of nitrogen mustard therapy, and the reader is referred to them for a thorough understanding of the actions of the halogenated alkyl amines.

In this article we will present our experience with the methyl bis-amine hydrochloride and the results thus far noted.

With two or three exceptions, all of our patients were ambulatory, remaining at bedrest for only thirty minutes following each injection. No ill effects were noted.

The nitrogen mustard was prepared in 10 cc. of sterile normal saline solution, 0.9 per cent, and in all but 1 case was injected directly and rapidly into the antecubital vein. Extreme care and caution were always exercised to prevent tissue infiltration. In 1 case, because of poor veins, an intravenous infusion of saline was started and the nitrogen mustard injected into the tubing to prevent subcutaneous extravasation. The dosage always given was 0.1 mg. per kg. body weight injected daily on four consecutive days. The only immediate side effect was nausea and vomiting, which occurred in 5 cases, 1 necessitating interruption of treatment upon two different courses. However, upon resumption three days later and one day later, respectively, no ill effects were encountered.

Bone marrow studies have not been routinely made, but the use of nitrogen mustard is accompanied by a depression of the total nucleated

cell count, reaching a maximum by the twenty-first day, with rapid recovery by the fourth week.⁸ Lymphopenia may develop within forty-eight hours, with recovery in two weeks, and neutropenia in the third week, with recovery by the fourth week. Thrombopenia may be produced, but serious bleeding has never occurred. In only 1 instance has any hemorrhagic tendency (case 14) occurred. No evidence of phlebotrombosis has been observed. Serial blood counts were not always obtained because of difficulty experienced by patients having to return long distances to the Clinic.

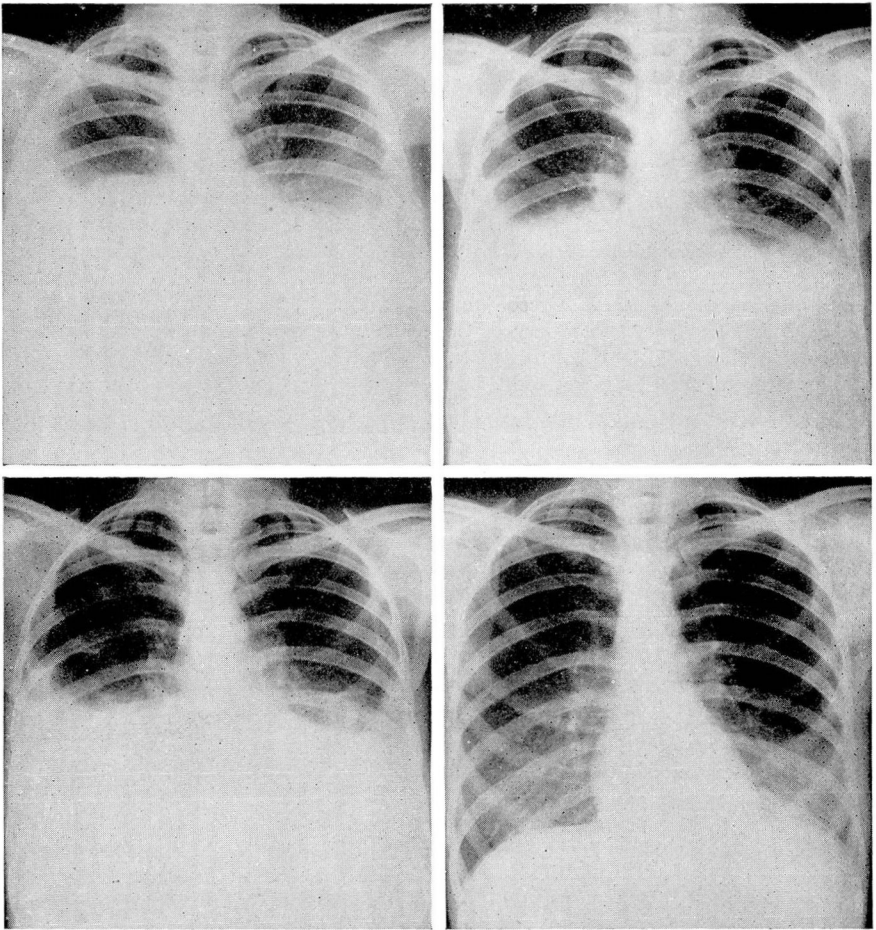
Case Reports

Case 1. A woman, aged 24, had had a diagnosis of Hodgkin's disease made by biopsy in January, 1946, and had subsequently received thirty or more x-ray treatments. During the past three months the patient had suffered from a cough, particularly at night, a weight loss of 10 pounds, fatigue, weakness of the legs, and had failed to respond to x-ray therapy. Physical examination revealed shotty glandular enlargement in the cervical, axillary, and inguinal areas. Breath sounds were harsh and diminished in the region of the chest. Laboratory data disclosed a normal blood count and differential count, and the blood sugar and serologic tests were negative. Sedimentation rate was 1.55 mm. per minute. X-ray examination of the chest revealed prominence of lung markings with probable interstitial infiltration in the lower portion of both lungs and a patch of infiltration in the upper part of the right lung. Slight irregular enlargement of both hilar zones was noted. A recent fracture of the right sixth rib with surrounding mottled destruction was also observed. Bronchoscopy was noncontributory. Nitrogen mustard was given daily for four consecutive days without ill effects. Repeated efforts for follow-up observations have failed.

Case 2. A woman, aged 70, had suffered from recurrent episodes of hives of two weeks' duration for ten years. During the past nine months, red, weeping, burning, and itching skin lesions had appeared and had failed to respond to treatment with a multitude of ointments. Physical examination revealed generalized cutaneous lesions which were of split-pea to palm size. Some of the lesions had dry serous crusts and tended to form in perfect circles. The scalp, face, hands, and feet were clear. Laboratory data disclosed urinalysis, blood sugar, blood Wassermann and Kahn tests, and complete blood count all normal. Skin biopsy revealed a histologic picture of mycosis fungoides. X-ray irradiation, 75 r to all areas, was applied. One week later a series of injections of nitrogen mustard was begun, and when this treatment was completed some of the lesions appeared to be fading decidedly, and there was less infiltration. Blood examination at this time was negative except for a red cell count of 3,410,000, 11 Gm. hemoglobin, leukopenia of 3750, and 83 per cent neutrophils. Urinalysis was negative. Two weeks following treatment with nitrogen mustard the itching had subsided and the lesions had improved, some disappearing completely, others with decreased to absent infiltration and receding redness. Three weeks after beginning treatment the blood count was 4,300,000 red cells, 10 Gm. hemoglobin, 4000 white cells, and 71 per cent neutrophils. At this time, peculiar recurrence of the lesions began to appear, so that a second course of the alkyl amine was given one month following the first. This series was accompanied by severe nausea and some vomiting. Three weeks later the blood study showed 3,500,000 red cells, 9 Gm. hemoglobin, 1000 white cells, 51 neutrophils, and 40 lymphocytes. Five days later

there were 2,850,000 red cells, 9 Gm. hemoglobin, 2450 white cells, 56 per cent neutrophils, and 44 per cent lymphocytes; and eleven days later there were 2,550,000 red cells, 8 Gm. hemoglobin, 2000 white cells, 56 per cent neutrophils, and 44 per cent lymphocytes. Within the month following the second series the lesions had failed to improve and the itching had persisted, so that local irradiation was again resorted to.

Case 3. A woman, aged 25, complained of the onset of fatigue, enlargement of cervical and later axillary and inguinal glands in November, 1945. A biopsy showed lymphoblastoma. Repeated courses of irradiation were associated with much nausea and vomiting. She had noted recent severe pain in the left upper quadrant and back and a weight loss of 10 pounds. Physical examination revealed decided pallor, generalized glandular enlargement, decreased breath sounds at the right base, and an extremely tender, full, obese abdomen. The spleen was palpable 3 fingers' breadth below the costal margin.



a b
c d
FIG. 1. Case 3. Roentgenograms of the chest.

NITROGEN MUSTARD THERAPY

Laboratory data: Urinalysis, blood Wassermann and Kahn tests, and blood sugar were negative. A blood count revealed mild hypochromic anemia. X-ray examination of the chest demonstrated pleural effusion and thickening of the pleura at each base (fig. 1a). The patient was given nitrogen mustard on four consecutive days and experienced much nausea and vomiting, obtaining some relief with phenobarbital. Five hundred cc. of citrated whole blood was given. Six weeks later she had gained 8 pounds, felt greatly improved, and the anorexia had completely subsided. She had experienced slight edema about the ankles for the past three days. Abdominal pain had subsided, but there was no change in the size of the nodes, spleen, or liver. The blood examination showed 63 per cent hemoglobin, and there was somewhat increased bilateral pleural effusion (fig. 1b). The patient was given a second course of nitrogen mustard therapy and five weeks following this series had gained 5 more pounds in weight and was breathing more easily. There was much edema about the ankles, evidence of pleural effusion at both bases, and much voluntary splinting of the abdominal wall. A slight degree of generalized adenopathy persisted, and a 2 plus pitting edema over the tibia was present.

Blood examination demonstrated 3,700,000 red cells and 53 per cent hemoglobin; roentgenograms of the chest showed only the effusion, which had decreased since the previous examination (fig. 1c). A third series of nitrogen mustard injections was given. Five weeks later the patient returned with low back pain, which had followed the first menstrual period she had had in six months. She felt remarkably improved. The glandular enlargement was minimal, the lungs appeared clear, and the edge of the spleen was now barely palpable through a thin, soft abdominal wall. The blood count at this time revealed 2,420,000 red cells and 2570 white cells, and the hemoglobin content was less than 50 per cent. X-ray examination of the chest was negative (fig. 1d). No additional nitrogen mustard was given. Upon our recommendation the patient received several blood transfusions under the supervision of her referring physician. She returned five weeks later, complaining of aching of the legs and arms and a loss in weight of 2 pounds. A few small epitrochlear and inguinal nodes were palpable, but the spleen was no longer palpable. The blood count revealed 3,570,000 red blood cells, 8.5 Gm. of hemoglobin, 2950 white blood cells, 72 per cent neutrophils, 4 per cent eosinophils, and 24 per cent lymphocytes. Roentgenograms of the chest gave entirely negative findings. A fourth series of nitrogen mustard injections was given without serious difficulty.

Case 4. A man, aged 50, had developed itching of the skin over the back ten months prior to his initial visit. Four months later a generalized exfoliative type of dermatitis had appeared. Physical examination revealed widespread thickening of the skin, associated with pruritus and scaling. Stony hard generalized glandular enlargement and a 1 plus pitting edema over the tibia were present. Urinalysis showed 1 plus albuminuria. Blood studies disclosed 75 per cent hemoglobin, and the white cell count was 3900 with a normal differential count. Blood sugar and Wassermann tests were negative. Roentgenograms of the chest showed evidence of aortic calcification. Biopsy of a lymph node revealed lymphoblastoma of indeterminate type, and examination of sternal marrow was compatible with the diagnosis of Hodgkin's disease. A series of nitrogen mustard injections was given. Three weeks later the urine contained 2 plus albuminuria, the skin remained unchanged, and the itching was minimally improved, but the patient had gained slightly in weight. Six weeks after the initial course he was given a second series because of the subjective relief of itching and the objective softening of the skin. The blood count at this time was 3,180,000 red blood cells, 9.5 Gm. of hemoglobin, 4350 white blood cells, 66 per cent neutrophils, 2 per cent eosinophils, 28 per cent lymphocytes, and 4 per cent monocytes.

Case 5. A man, aged 55, had developed a severe upper respiratory infection in September, 1946. Ten days after its subsidence, enlargement of the cervical glands had occurred. Physical examination was negative except for the glandular enlargement and a diffusely enlarged thyroid gland. The laboratory examination disclosed urinalysis, blood sugar, and Wassermann reaction normal. The red cell count was 5,130,000, the white cell count 11,300, and the hemoglobin 94 per cent. The differential count was normal. X-ray examinations of the chest and dorsal region of the spine were also negative. A biopsy from the nasopharynx was made but revealed only a chronic inflammatory lesion. Biopsy of a left cervical node indicated a diagnosis of lymphoblastoma. A series of x-ray treatments to the cervical region was given and was repeated one month later because of recurrence of symptoms. For the succeeding two months x-ray therapy was again administered because of cervical adenopathy, and on July 14, 1947, a series of nitrogen mustard injections was given. The blood examination at the end of the series revealed 84 per cent hemoglobin and 6700 white cells. Urinalysis was reported normal.

One month following completion of the series the patient experienced rapidly progressive swelling of the face and left side of the neck. Three days later he entered the hospital as an emergency case. There was marked edema of the eyelids and of the left side of the face, which was hard and dusky in color. Respirations were difficult. Cervical nodes were matted in the left and enlarged on the right. The chest was clear. The liver was palpable 3 fingers' breadth below the right costal margin. Mediastinal compression was believed to have occurred. The blood examination revealed 68 per cent hemoglobin, 6950 white blood cells, 81 per cent neutrophils, 5 per cent lymphocytes, 13 per cent monocytes, 1 per cent metamyelocytes. Roentgenogram of the chest disclosed progression of the mediastinal tumor with probable atelectasis of the right middle lobe and infiltration in the left upper lobe. The condition of the patient was grave, but a course of nitrogen mustard was started, and continuous oxygen administered nasally. He expired eight hours following the third injection. Permission for autopsy was refused.

Case 6. A man, aged 22, had had a cold, flu, pneumonia, and questionable whooping cough at the age of 6 and following this had developed enlargement of the right cervical glands. At the age of 8, material obtained elsewhere by biopsy of a node from the neck was positive for Hodgkin's disease. During the next ten years he had received about one hundred blood transfusions and much radiation therapy. Five intramuscular injections of anticytotoxic serum had been given. Four independent biopsies done elsewhere led to a concurrence in the diagnosis of Hodgkin's disease. When he was initially seen here, physical examination revealed evidence of cervical and supraclavicular glands and one large axillary node. The liver was palpable 3 fingers' breadth below the costal margin and was slightly tender. The spleen was also palpable 3 fingers' breadth below the costal margin. Urinalysis and x-ray examination of the chest were negative. The blood examination revealed 4,130,000 red cells, 10.5 Gm. hemoglobin, and 3900 white cells. The differential count disclosed 58 neutrophils, 6 eosinophils, 1 basophil, and 35 lymphocytes. The patient received a course of nitrogen mustard and one month later had gained 12 pounds in weight and felt exceedingly well except for a severe attack of shingles. The spleen was palpable 3 fingers' breadth and the liver at 2 fingers' breadth below the costal margin. The adenopathy had almost subsided. Two months after this first course the glandular enlargement was barely perceptible, but the liver and spleen remained unchanged. Three months after the initial course he had maintained his weight but had developed anorexia. The glandular enlargement was absent, the spleen was palpable at 2 fingers' breadth and the liver at 3 fingers' breadth below the costal margin. The urinalysis was negative, and there were 3,720,000 red cells, 9.5 Gm. hemoglobin, and 4050 white cells. The patient received a second course of nitrogen

NITROGEN MUSTARD THERAPY

mustard and one month later had gained an additional 7 pounds, was symptom-free, had no enlarged glands, and the spleen was palpable at 1 to 2 fingers' breadth below the costal margin. X-ray examination of the chest was then negative, and the blood examination revealed 4,850,000 red cells, 12.0 Gm. hemoglobin, 3650 white cells, 57 per cent neutrophils, 16 per cent eosinophils, 22 per cent lymphocytes, and 5 per cent monocytes. One month following the last observation he was maintaining his weight but had been experiencing dizziness, which was attributed to his work in a hot kitchen. The spleen was palpable 1 to 2 fingers' breadth below the left costal cage, and the liver dullness was noted 1 to 2 fingers' breadth below the right costal cage. No adenopathy was present. X-ray examination of the chest remained negative. The blood count revealed 5,050,000 red blood cells, 14 Gm. hemoglobin, 4700 white blood cells, 74 per cent neutrophils, 10 per cent lymphocytes, 8 per cent eosinophils, and 8 per cent monocytes. Additional mustard therapy was deferred.

Case 7. A woman, aged 43, had had generalized glandular enlargement in 1941, and a biopsy had demonstrated lymphosarcoma. She had received irradiation treatment to the nodes in 1941, 1944, and 1946. Ten months prior to admission, intermittent, sharp, stabbing pain had appeared in the right hip, at times awakening her from sleep. She had lost 21 pounds in weight during the past ten months and had suffered from anorexia, general weakness, and nervousness. It was believed that her symptoms manifested cord metastasis. The physical examination was entirely negative. Urinalysis, Wassermann reaction, and blood sugar were negative. Blood examination revealed 3,950,000 red cells, 4200 white cells, 10.0 Gm. hemoglobin, 79 polymorphonuclears 3 eosinophils, 16 lymphocytes, and 2 monocytes. A series of nitrogen mustard injections was given, considerable nausea and vomiting following the second injection. Mild mental hallucinations occurred five to six hours after this injection and lasted a half-hour. The nausea and vomiting responded to phenobarbital given orally. The patient was seen four weeks later, stating that she had been completely free of all pain since the course of treatment. Blood count revealed 3,950,000 red blood cells, 10 Gm. hemoglobin, 4200 white blood cells, 79 per cent neutrophils, 3 per cent eosinophils, 16 per cent lymphocytes, and 2 per cent monocytes. Additional treatment was deferred.

Case 8. A man, aged 62, had developed widespread pruritus eight months prior to admission. Four months later a generalized glandular enlargement had appeared. Physical examination revealed no cervical but axillary and inguinal glandular enlargement, and the liver was palpable 3 fingers' breadth below the costal margin. The urinalysis, blood count, blood sugar, and Wassermann test were negative. Sternal puncture gave negative findings, and x-ray examination of the chest was also negative. Biopsy of an inguinal node revealed lymphoblastoma. Roentgen treatment was given to various areas, but four months later the cervical nodes were enlarged. The liver was palpable at the costal margin. The blood examination revealed 1,700,000 red cells, 28 per cent hemoglobin, 60 per cent neutrophils, 20 per cent lymphocytes, 2 per cent eosinophils, 6 per cent atypical lymphocytes, and 1 per cent metamyelocytes. A course of nitrogen mustard therapy was administered, during which time the patient received three 500 cc. transfusions of fresh whole blood. He felt improved following this series, and no ill effects were observed. Attempts to contact the patient for follow-up observations have failed.

Case 9. A man, aged 47, was found to have polycythemia elsewhere in 1943. At that time twelve to fifteen x-ray treatments had been given without improvement. Since then the patient had been extremely nervous, was unable to do any hard work, and felt completely exhausted. Physical examination revealed the mucous membranes to be plethoric

and essential hypertension to be present. The spleen was palpable 2 fingers' breadth below the left costal cage. The urinalysis, blood sugar and urea, and Wassermann reaction were negative, as was x-ray examination of the chest. Blood studies revealed 8,640,000 red cells, 162 per cent hemoglobin, 13,500 white cells, normal differential count, and the total amount of cells present per kilogram of body weight was 98 cc. A full series of nitrogen mustard injections was given and accompanied by moderate nausea and vomiting. Upon return of the patient one month later the plethora had disappeared, and he felt stronger, though noon-day exhaustion persisted. The blood pressure remained unchanged, being 220 systolic and 120 diastolic. The spleen was no longer palpable. The blood count now showed 7,330,000 red blood cells, 21 Gm. hemoglobin, 5500 white blood cells, and 50 cc. of cells per kg. of body weight. No additional therapy was instituted.

Case 10. A man, aged 41, suffered the onset of intermittent fever, anorexia, and weakness in March, 1946. Physical examination disclosed enlargement of axillary and left posterior cervical glands and spleen palpable 3 fingers' breadth below the costal margin. Urinalysis, blood sugar, Wassermann reaction, undulant fever skin test, and agglutination were negative. Blood study revealed 4,780,000 red cells, 75 per cent hemoglobin, 10,650 white cells, and normal differential count. The patient received one blood transfusion, followed by a course of splenic irradiation. Three months later he had improved, having had only one attack of fever. The spleen was still palpable 3 to 4 fingers' breadth below the costal margin, and a complete blood examination with a differential count was normal. No treatment was added at this time. In June, 1947, general aching appeared, with night sweats, splenic pain, and a loss of 15 to 20 pounds in weight. There was shotty axillary and inguinal enlargement, splenomegaly 3 fingers' breadth below the costal margin, and a few rales at the base. The blood examination was normal, with the exception of 18 per cent monocytes in the peripheral blood. An additional series of x-ray treatments was given. Five months later it was evident that the condition of the patient was growing progressively worse, and pronounced weakness, exhaustion, and weight loss occurred. The spleen was not palpable, but there was generalized enlargement of the lymph glands. There were 3,160,000 red cells, 58 per cent hemoglobin, 9600 white cells, and a normal differential count. A series of nitrogen mustard injections was given without ill effect. He improved for two weeks but again became weak, peripheral edema developed, the abdomen became distended, and moist rales were present in both bases. The blood examination revealed 6.5 Gm. hemoglobin and 8600 white cells. Urinalysis was normal. A series of nitrogen mustard injections was given, and it was advised that transfusions be given at home. Two weeks following this, however, his death was reported. Details were not available.

Case 11. A woman, aged 62, had noted slowly progressing enlargement of the cervical glands for the past two years and lack of energy for the past two months. During the four months preceding her visit she had had a total of twenty-three x-ray treatments for a "tumor behind left eye". Her vision was growing progressively worse, and dyspnea was slowly increasing. Physical examination revealed only large, scattered, firm cervical nodes. No eye changes were detected. Laboratory examination demonstrated the blood count, urinalysis, blood sugar, and Wassermann reaction normal. Roentgenograms of the chest revealed fluid at the left base with very large paratrachealperibronchial nodes (fig. 2a). Biopsy of a cervical node demonstrated a necrotic neoplasm, the configuration suggesting lymphoma. A complete series of nitrogen mustard injections was administered without ill effect, and the patient felt alert and stronger. One month later she felt definitely improved, was eating well, and the cervical node enlargement had almost

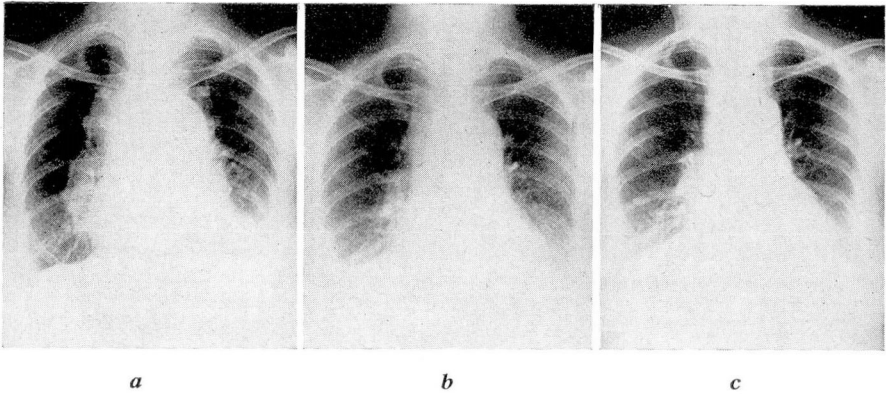


FIG. 2. Case 11. Roentgenograms of the chest.

completely subsided. Examination of the eyes was negative. There were 3850 white blood cells and 12.0 Gm. hemoglobin. X-ray examination of the chest revealed decided reduction in the mediastinal shadow with complete absence of any pleural effusion (fig. 2b). Because of the marked improvement and feeling of well-being, additional nitrogen mustard therapy was deferred. Six weeks later the patient was continuing to improve, and the headaches had been completely absent. The complete blood count and urinalysis were negative, and roentgenograms of the chest showed continued regression in the size of the mediastinal shadow (fig. 2c). Examination of the fundi showed the presence of optic atrophy in the left eye, and visual fields suggested bitemporal hemianopsia. X-ray examination of the skull demonstrated marked ballooning of the sella, which was believed to represent a part of the lymphoblastoma process.

Case 12. A girl, aged 17, had a history of fever and enlarged cervical glands of one month's duration. Physical examination disclosed cervical and axillary glandular enlargement. Urinalysis, blood urea, blood sugar, and Wassermann test were negative. The blood count revealed 5,080,000 red cells, 10.5 Gm. hemoglobin, 33,000 white cells, 96 per cent neutrophils, 3 per cent lymphocytes, and 1 per cent monocytes. Roentgenograms of the chest demonstrated an upper mediastinal tumor mass and right pleural effusion. The patient entered the hospital and was given two courses of x-ray treatment. The mediastinal and hilar masses in the chest completely cleared, and the blood returned to normal except for a mild hypochromic anemia. During the next two months x-ray therapy was again administered but the patient failed to respond satisfactorily. She received one course of nitrogen mustard injections, after which she felt moderately improved, although little change was noted in a hepatomegaly or pulmonary involvement with effusion. A second series was given three months later and a third course administered three weeks following this. There was little if any perceptible improvement. The patient received blood transfusions during each series because of a lowered hemoglobin content, the red cells at one time being 3,850,000 and hemoglobin 63 per cent. She expired suddenly in her sleep at home three to four weeks after the last series of injections.

Case 13. A woman, aged 55, had first noted enlargement of the right axillary lymph nodes in 1939, and biopsy had revealed lymphoblastoma. During the next seven years the patient had received x-ray treatment to enlarged glands in the cervical, axillary, and inguinal regions. When seen in April, 1947, she had only slight, discrete

enlargement of the cervical glands. The spleen was palpable 4 fingers' breadth and the liver 5 fingers' breadth below the costal margin. Urinalysis was negative. Blood examination demonstrated 3,820,000 red cells, 4950 white cells, 68 per cent hemoglobin, and a normal differential count. X-ray examination of the chest showed no enlarged glands in the hilus. A series of nitrogen mustard injections was administered. Through personal communication four months later it has been learned that no improvement followed the therapy and that the family physician was continuing irradiation therapy.

Case 14. A man, aged 39, had had a birthmark removed from the left little toe in May, 1945, at another institution. Histologic examination of the specimen revealed it to be a malignant melanoma. The patient had developed pronounced edema of the left leg shortly after excision. About June, 1946, nodules began to appear over his body and failed to respond to x-ray therapy to the pituitary gland. He had lost 12 pounds in weight during the past year. The only positive findings were extensive lymphedema of the left leg to the hip and many nodules, 0.5 to 3 cm. in size, over many areas of the skin surface. Slight darkening of color was present in a few of them. Urinalysis, blood sugar, and Wassermann reaction were negative. Blood study revealed 4,780,000 red cells, 6350 white cells, and 63 per cent hemoglobin. X-ray examination of the chest disclosed slight infiltration in the left upper lobe and a soft tissue shadow 1.5 to 2 cm. just below this. A series of nitrogen mustard injections was given without ill effect, and two weeks later on gross examination many of the lesions appeared smaller. A gain of 5 pounds in weight was observed. Blood study disclosed 4,600,000 red cells, 75 per cent hemoglobin, and 8160 white cells. Urinalysis was normal. The lesions in the chest had decreased slightly in size. Another series of nitrogen mustard injections was given one month after the initial course, and three weeks later no changes were noted in roentgenograms of the chest. The cutaneous lesions were not altered, a recent right subconjunctival hemorrhage was fading out, and several areas of ecchymoses in the right wall of the chest were subsiding. The blood examination at this time revealed 3,350,000 red cells, 58 per cent hemoglobin, and 3400 white cells. The differential count showed 51 per cent neutrophils, 20 per cent lymphocytes, 2 per cent eosinophils, 26 per cent monocytes, and 1 per cent atypical cells. The platelets were 120,000. Prothrombin time, bleeding time, and coagulation time were all normal. Further treatment with nitrogen mustard was considered inadvisable because of the hemorrhagic tendency, now subsiding.

Case 15. A woman, aged 21, had had a suspected substernal thyroid tumor removed in 1942, prior to admission here. Microscopic examination proved this to be indicative of Hodgkin's disease. She had been given numerous and prolonged courses of x-ray treatment and finally became x-ray resistant. When first seen she had a small mass of matted nodes in the right anterior cervical chain. The blood sugar and Wassermann reaction were negative. The blood examination was normal except for hemoglobin content of 68 per cent. X-ray examination of the chest showed some infiltration in the left lung extending into the upper lobe from the hilar zone and infiltration with slightly thickened pleura in the lower lung field. Following the second injection in the first course of nitrogen mustard therapy, excessive nausea and vomiting required a three-day lapse in treatment, but the remaining two injections were given without ill effect. Six weeks later the appetite had improved, and she had gained 6 pounds in weight. A few coarse crackles were audible at the left base, and the only enlarged gland was a right submental node. X-ray examination of the chest gave findings identical with the initial ones. Blood examination revealed 4,010,000 red cells, 10 Gm. hemoglobin, and 9900 white cells. A second series of nitrogen mustard injections was administered. Onset of vomiting required a one-day lapse in therapy, which was resumed without incident.

NITROGEN MUSTARD THERAPY

Case 16. A woman, aged 53, was found to have arterial hypertension in 1942. In 1945 she was hospitalized elsewhere because of weakness. A diagnosis of leukemia was made and two transfusions given. Eight months prior to admission to the Clinic she had had a severe nasal hemorrhage with subsequent loss of hearing. She had lost 63 pounds in weight in the past five years. Examination revealed a generalized shotty glandular enlargement, a systolic blow over the entire precordium, and an enlarged spleen extending to the pelvic brim and across the midline. The liver was enlarged to the umbilicus. The blood pressure was 130 systolic, 74 diastolic. Urinalysis, blood sugar, and Wassermann test were negative. X-ray examination of the chest revealed only increased bronchovascular markings. Blood study demonstrated 2,150,000 red cells, 36 per cent hemoglobin, and 576,000 white cells. Differential count showed 38 per cent neutrophils, 1 per cent lymphocytes, 4 per cent eosinophils, 4 per cent basophils, 40 per cent metamyelocytes, 1 per cent promyelocytes, 1 per cent reticulo-endothelial cells, 1 per cent atypical cells, 9 per cent myelocytes, and 1 per cent myeloblasts. Examination of the bone marrow gave findings consistent with a diagnosis of chronic myeloid leukemia. The patient was hospitalized and a transfusion of 500 cc. of fresh whole blood was given, followed by a complete series of nitrogen mustard injections. Following the second of the series of four injections there were 2,200,000 red cells, 38 per cent hemoglobin, 351,000 white cells present. The day following the fourth injection there were 2,500,000 red blood cells, 41 per cent hemoglobin, 750,000 white cells present. Five hundred cc. of blood was given on the first and third days following the series of injections, and the patient was then discharged from the hospital. Three weeks later the patient felt considerably improved, the spleen had decreased in size, but the size of the liver remained unchanged to percussion. Blood count then revealed 3,290,000 red blood cells, 7.5 Gm. of hemoglobin, 343,000 white blood cells, 28 per cent neutrophils, 1 per cent lymphocytes, 4 per cent eosinophils, 1 per cent basophils, 33 per cent metamyelocytes, 3 per cent promyelocytes, and 10 per cent myelocytes. She received a second course of therapy, at the end of which time the count was 3,460,000 red blood cells, 7.5 Gm. of hemoglobin, and 206,500 white blood cells.

Discussion

The mode of action of nitrogen mustard is not clearly understood, but it is believed to inhibit mitotic activity. It has been noted that in the laboratory animal the drug apparently has a specific nucleotoxic action, acting directly on the chromosomal structure and not altering other cellular constituents.⁵ Because of the absence of its fewer side reactions and its ease of solubility in saline solution, the clinical application of nitrogen mustard was narrowed to two compounds, the methyl and the tris-amine forms. The effects of many allied compounds remain to be observed, so that results may be even more gratifying than is now evident.

At the same time, we must beware of overenthusiasm in the use of this new approach to therapy of some types of neoplasm. In many types of lymphomata, in leukemia of all types, in polycythemia vera rubra, and in various other types of malignant disease, such as melanotic sarcoma, bronchogenic carcinoma, and reticulum cell sarcoma, nitrogen

mustard has been given a clinical trial. Apparently its greatest value thus far lies in its benefit to patients with Hodgkin's disease.

Because sufficient time has not elapsed for adequate observation, the advantage of nitrogen mustard over radiation therapy has not as yet been evaluated. It has been observed that nitrogen mustard may be effective in x-ray-fast cases, and that cases which have become x-ray resistant may again become x-ray sensitive following a course of this drug. The frequency with which the courses should be repeated or the maximum amount of dosage which can be given has not been definitely established.

In all probability, from among the several hundred related compounds now known, others far superior to the methyl bis-amine or tris-amine compounds will be discovered. Certainly the nitrogen mustards are of definite value. Their exact importance and their relation to x-ray and radioactive substances are not yet fully determined.

Summary

It has been our intention merely to report an additional 16 cases treated with the methyl bis-amine hydrochloride form of nitrogen mustard, a total of 31 series of injections having been completed. Five of our cases were classified as Hodgkin's disease. Of these patients 2 died within six to eight weeks of institution of the first course of treatment, though their disease had previously been treated by irradiation seven and thirteen months, respectively (cases 10 and 12). Cases 3 and 6 have progressed exceedingly well. No follow-up is available in case 1.

Six cases have been classified as lymphoblastoma. Of these, case 5 showed minimal improvement following the initial course of injections but died during the second series. Case 11, 13, and 15 have benefited considerably by treatment. The value of nitrogen mustard in case 4 is somewhat questionable. Case 8 has not responded for follow-up data.

In our miscellaneous group case 7, with a diagnosis of lymphosarcoma with cord metastasis, has been completely relieved of all pain secondary to nerve root pressure. Case 14, diagnosed as metastatic melanosarcoma, has received only questionable benefit. Case 16, having chronic myeloid leukemia, has benefited considerably, and in case 9 the polycythemia appears to be improving. In case 2, relief from mycosis fungoides appeared quite striking at first but of only temporary duration.

It may be said, however, that independently of objective improvement, a feeling of well-being, improvement in appetite, and gain in weight has occurred in practically all cases.

Addenda

Since the completion of this article 2 additional cases of Hodgkin's disease and 1 of chronic myeloid leukemia have been treated with nitrogen mustard. Evaluation of these 3 cases must be deferred until sufficient time has elapsed for observation of the results of therapy.

References

1. Krumbhaar, H. D.: Blood and bone marrow in yellow cross gas (mustard gas) poisoning. *J. M. Research* **40**:497 (Sept.) 1919.
2. Pappenheimer, A. M., and Vance, M.: Effects of intravenous dichloroethylsulfide in rabbits, with special reference to its leucotoxic action. *J. Exper. Med.* **31**:71 (Jan.) 1920.
3. Warthin, A. S., and Weller, C. V.: *Medical Aspects of Mustard Gas Poisoning.* (St. Louis: C. V. Mosby Co., 1919).
4. Rhoads, C. P.: Sword and plough share (mustards). *J. Mt. Sinai Hosp.* **13**:299-309 (Mar.-Apr.) 1947.
5. Gilman, A., and Philips, F. S.: Biological actions and therapeutic applications of beta-chloroethyl amines and sulfides. *Science* **103**:409-415 (April 5) 1946.
6. Goodman, L. S., *et al.*: Nitrogen mustard therapy; use of methylbis (beta-chloroethyl) amine hydrochlorides and tris (beta-chloroethyl) amine hydrochloride for Hodgkin's disease, lymphosarcoma, leukemia and certain allied and miscellaneous disorders. *J.A.M.A.* **132**:126-132 (Sept. 21) 1946.
7. Jacobson, L. O., *et al.*: Nitrogen mustard therapy; studies on effect of methyl-bis (beta chloroethyl) amine hydrochloride on neoplastic diseases and allied disorders of hemopoietic system. *J.A.M.A.* **132**:263-271 (Oct. 5) 1946.
8. Spurr, C. L., *et al.*: Clinical application of nitrogen mustard compound methyl bis (beta-chloroethyl) amine to treatment of neoplastic disorders of hemopoietic system. *Cancer Res.* **7**:51 (Jan.) 1947.