

RETROBULBAR NEURITIS

Report of 3 Cases

ROSCOE J. KENNEDY, M.D.

Department of Ophthalmology

Retrobulbar neuritis is an inflammation affecting the optic nerve behind the eyeball without ophthalmoscopic manifestations in the fundus. It is characterized by a sudden loss of vision occurring over a period of from one to eight days. The condition may be acute or chronic, the latter type usually being referred to as toxic amblyopia. Acute retrobulbar neuritis is usually unilateral, whereas toxic amblyopia is generally bilateral.

Patients with retrobulbar neuritis usually have a history of failing vision which has progressed rapidly and which may proceed to almost complete blindness. Although this blindness may be permanent, it is usually restored with treatment. Occasionally there is some pain on movement of the eyeball.

Examination will ordinarily reveal normal fundi, although there may be some hyperemia of the disk. Duke-Elder¹ states, "In the majority of cases the fundus appears normal and the condition may be defined as a disease in which neither the examiner nor the patient sees anything." The pupillary reflex is usually of significance and, according to Parsons,² a lack of sustained constriction of the pupil to light, if it can be placed beyond dispute, is of the greatest diagnostic significance. Visual fields are an important part of the examination. A central scotoma is the usual finding early in the disease, although if the disease has progressed far enough the loss of vision may be so great that only a small island of vision remains. A cecocentral scotoma may be present and, if bilateral, is almost diagnostic of toxic amblyopia.

Etiologic factors in cases of retrobulbar neuritis may be local, such as inflammation associated with sinusitis, or general, as multiple sclerosis and undulant fever. Duke-Elder³ believes that the majority of cases of the usual type of acute unilateral retrobulbar neuritis are due to a virus infection of the central nervous system.

Case Reports

Case 1. A man, aged 33, was first seen on May 29, 1947, with loss of vision in the right eye. He had turned suddenly two and a half weeks previously, following which vision in the right eye became blurred and remained unchanged. There was no pain or headache. Examination revealed visual acuity O.D., counts fingers at 1 foot, O.S. 6/12.

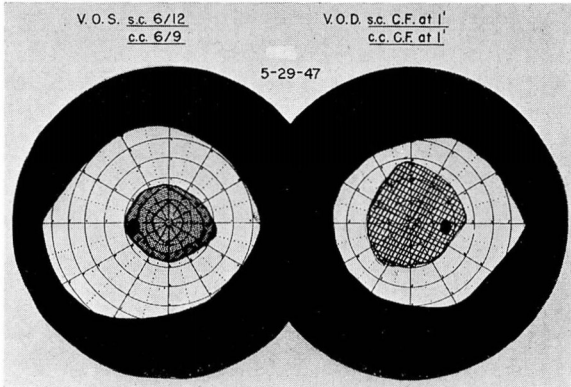


FIG. 1.

Test objects:
O.D.: form 20/330
color none
with 20/330
O.S.: form 2/330
color 3/330
C.P. 10 ft.
Cooperation good
Features normal

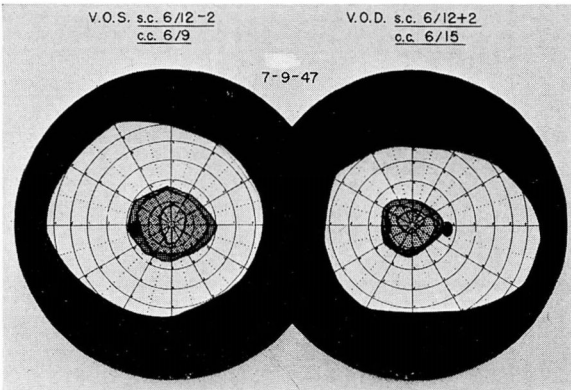


FIG. 2.

Test objects: form 2/330
color 3/330
C.P. 10 ft.
Cooperation good
Features normal

External examination was negative. Pupils were 4 mm. round and equal, and reacted to direct and consensual light and to accommodation. Fundus examination of both eyes was negative except for a few fine vitreous opacities in the right eye. Visual fields showed a central scotoma of the right eye (fig. 1). The diagnosis of retrobulbar neuritis was made, and the patient returned to his referring physician, who was advised to give him a course of intravenous typhoid therapy. This treatment was carried out, and the patient was seen again on July 9, 1947, at which time the visual field examinations were repeated and found to be normal. The visual acuity has returned in the right eye to 6/12 plus 2 (fig. 2). At this time he was examined by Dr. Louis J. Karnosh of the Department of Neuropsychiatry, who did not find enough positive evidence to establish a diagnosis of multiple sclerosis. This case represents an acute retrobulbar neuritis.

Case 2. A man, aged 25, was first seen on November 29, 1945, complaining of loss of most of his vision during the preceding week. Examination revealed a visual acuity O.D. 6/6 minus 3 and O.S. 3/60. External examination was entirely negative. Fundus examination was negative in both eyes. Visual fields showed a central scotoma in the left eye with some contraction of the form field (fig. 3). The patient was admitted to the hospital and given intravenous typhoid therapy and vitamin B intramuscularly. On December 14, 1945, the fields were normal (fig. 4), with a visual acuity of O.D. 6/9

RETROBULBAR NEURITIS

FIG. 3.

O.S. Absolute central scotoma
 Test objects:
 O.D.: form 1/280
 color 3/280
 O.S.: form 1/280
 color 5/280
 C.P. 7 ft.
 Cooperation good
 Features normal

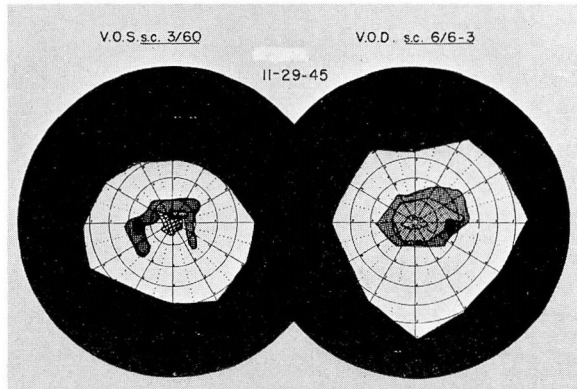
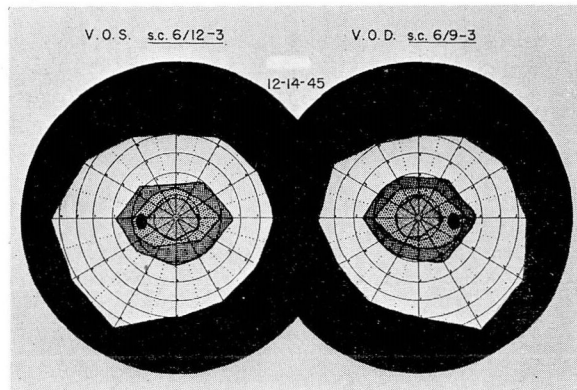


FIG. 4.

Test objects: form 1/280
 color 3/280
 C.P. 10 ft.
 Cooperation good
 Features normal



minus 3 and O.S. 6/12 minus 3. The patient was seen in the Division of Internal Medicine at that time, and no signs of multiple sclerosis were elicited. This case represents an acute retrobulbar neuritis.

Case 3. A woman, aged 46, was first seen in the Clinic on April 29, 1946, with the complaint of sudden loss of vision in the right eye accompanied by some pain one week previously. Examination two years previously had shown normal visual acuity in each eye. The history was negative except that on the night prior to onset the patient had drunk a large quantity of wine and smoked many cigarettes. Examination revealed a visual acuity of O.D. light perception, O.S. 6/9. External examination was negative except for a sluggish pupillary reaction in the right eye. Fundus examination in the right eye showed the media clear, the disk slightly hazy, and some hyperemia of the macula. Examination of the left fundus was negative. Visual fields showed retention of a small field of vision in the nasal field of the right eye. The left eye was normal (fig. 5). Subsequent field studies showed improvement, but there was a central scotoma present. The patient was admitted to the hospital and given a course of intravenous typhoid therapy and vitamin B intramuscularly. On April 10, 1947, there was still a central scotoma of about 5° (fig. 6), and fundus examination showed definite optic atrophy. This case is believed to represent toxic amblyopia or chronic retrobulbar neuritis.

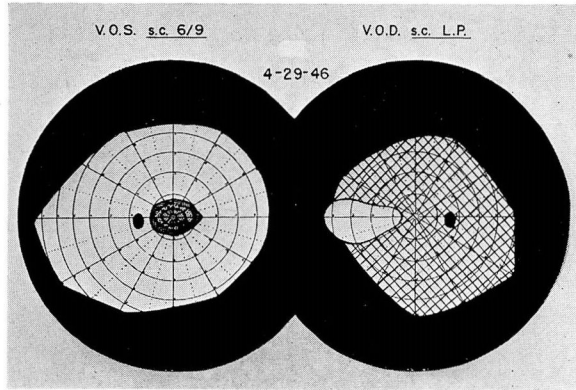


FIG. 5. Test objects:

O.D.: form light
color none
O.S.: form 2/330
color 5/330

C.P. 10 ft.
Cooperation good
Features normal

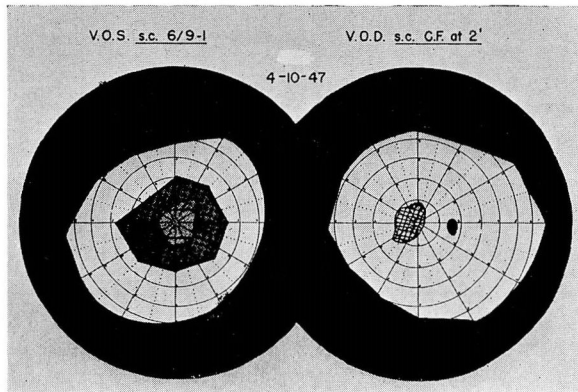


FIG. 6. Test objects:

O.D.: form 10/330
color 10/330
O.S.: form 2/330
color 3/330

C.P. 10 ft.
Cooperation good
Features normal

Differential Diagnosis

Retrobulbar neuritis must always be distinguished from hysteria, although this condition can usually be eliminated by visual field studies. Multiple sclerosis should always be suspected and thorough neurologic study made. In 1934, Lillie⁴ reported 500 cases of multiple sclerosis, stating that 15 per cent of the patients had visual disturbance as a preliminary finding. However, in reviewing the last 25 cases of retrobulbar neuritis here, we were unable to elicit any evidence of multiple sclerosis.

Treatment

Foci of infection should be searched for and removed if found. Immediate treatment should consist of hospitalization and the intravenous injection of typhoid vaccine, and the administration of vitamin B complex, either intramuscularly or orally. The typhoid vaccine is usually begun with an initial dose of 25,000,000 organisms and doubled every other day until 600,000,000 to 800,000,000 is reached. The use of tobacco and alcohol should be limited or completely restricted. Prognosis should be guarded, although recovery of vision is the usual outcome.

Summary

1. Retrobulbar neuritis may be acute or chronic.
2. Retrobulbar neuritis may be an early sign of multiple sclerosis, and all cases therefore should include a complete neurologic examination.
3. A typical case showed normal fundi with central visual defect.
4. Usually the onset is sudden and the condition unilateral.
5. Gradual recovery occurs in most cases with treatment and restoration of vision.
6. Intravenous typhoid therapy is the treatment of choice when no foci of infection are demonstrable.

References

1. Duke-Elder, W. S.: Textbook of Ophthalmology III. Diseases of the Inner Eye (St. Louis: C. V. Mosby Co., 1941) p. 2978.
2. Parsons, J. H.: Diseases of the Eye (London: J. & A. Churchill Ltd., 1944) p. 395.
3. Duke-Elder, W. S.: Textbook of Ophthalmology III. Diseases of the Inner Eye (St. Louis: C. V. Mosby Co., 1941) p. 2983.
4. Lillie, W. I.: Clinical significance of retrobulbar and optic neuritis. *Am. J. Ophth.* 17:110-119 (Feb.) 1934.