

UNUNITED FRACTURES OF THE NECK OF THE FEMUR

Modern Concepts of Treatment

JAMES A. DICKSON, M. D.

Department of Orthopedics

THERE is a widespread assumption on the part of the general public and many medical men that, with the use of internal fixation, the problem of treatment of fractures of the neck of the femur has been completely and successfully solved. This method of management has marked an important milestone, but it has not provided the complete and final solution in such fractures. Before internal nailing was used, union occurred in only about 50 per cent of intracapsular fractures of the femur, whereas now about 80 per cent of such fractures unite. However, appraisal of results merely from the standpoint of bone healing does not tell the whole story. When the results are considered from the standpoint of function they are unsatisfactory in a rather large proportion of cases in which union is obtained. The group in which atrophic changes in the head and arthritic complications result even though union occurs, added to the approximately 20 per cent of cases in which the fracture fails to unite, comprises about 35 to 50 per cent of all fractures of the femoral neck. Thus treatment with internal fixation may be said to be actually successful in only one-half to two-thirds of such cases. These figures indicate that there is room for considerable improvement in the treatment of this type of fracture.

Until very recently it has been generally thought that the outcome of treatment of a fracture at the neck of the femur depended solely on the degree of interruption of the blood supply, and this was regarded as an unpredictable and uncontrollable factor. It was thought that all that could be done was to nail the fragments together and to hope that the circulation remained sufficiently intact to furnish nutrition for bone healing and to prevent aseptic necrosis of the head. Even when there has been convincing roentgenographic evidence of nonunion, the tendency has been to hang on to the blind hope that the efficiency of the circulation would somehow be restored and that the fracture eventually would heal. This hoped-for eventuality almost never happened. The result has been that patients with nonunion following an intracapsular fracture of the femur have been incapacitated for years while avascular changes were progressing to aseptic necrosis and eventual collapse of the head fragment, and they and their surgeons were hoping for the impossible. Finally, when a secondary operation was recognized as imperative, the long delay had often so complicated the situation that a formidable and extensive reconstruction procedure, which could never yield entirely satisfactory results, was required.

In elderly persons, in whom the majority of hip fractures occur, the auxiliary circulation through the ligamentum teres is minimal or lacking. Hence

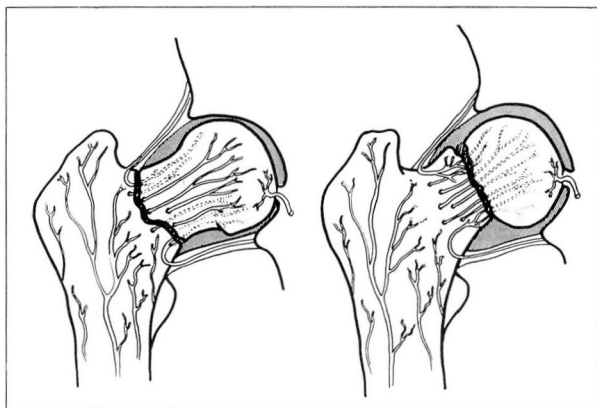


FIG. 1. Circulation to head and neck of femur, indicating relationship of position of fracture to interruption of blood supply.

circulation to the head of the bone is maintained almost entirely by the capsular vessels that enter the base and posterior part of the neck of the femur and extend upward through the medullary vessels. When a fracture of the neck of the femur occurs there is a definite interruption of this blood supply to the head. The degree of circulatory impairment varies with the position of the fracture (fig. 1). When the fracture is near the base some blood supply remains in the head fragment, but in subcapital fractures the head segment is almost devoid of circulation. In the treatment of fractures of the neck of the femur, the earlier this main source of blood supply can be restored through the neck by impaction of the fracture and stimulation of osteogenesis and revascularization, the better the results should be.

Recent studies of cases in which a fracture at the neck of the femur has failed to unite or in which treatment has been unsatisfactory from the functional standpoint have confirmed the fact that the reestablishment of the circulation is of prime importance in determining the outcome of treatment. Whether or not nonunion or aseptic necrosis or both occur depends on the degree of interruption of the blood supply, especially to the amputated head fragment. These studies have shown further that the reestablishment of the circulation is closely related to and partially dependent on a mechanical factor, that is, the shearing strain on the fractured surfaces.

The mechanical factor has been investigated in detail by Pauwels,¹ Linton,² and Eyre-Brook and Pridie.³ They all have found that in fractures at the neck of the femur which have failed to unite, the angle of the fracture tends toward the vertical (when measured in relation to the femoral shaft), the fracture is not impacting, and shearing force tends to pull the fractured surfaces apart, even when they are satisfactorily nailed. These authors all use different methods for measuring the inclination of the fracture plane, but all are estimating the same factor, the degree of shearing strain tending to pull the fragments apart

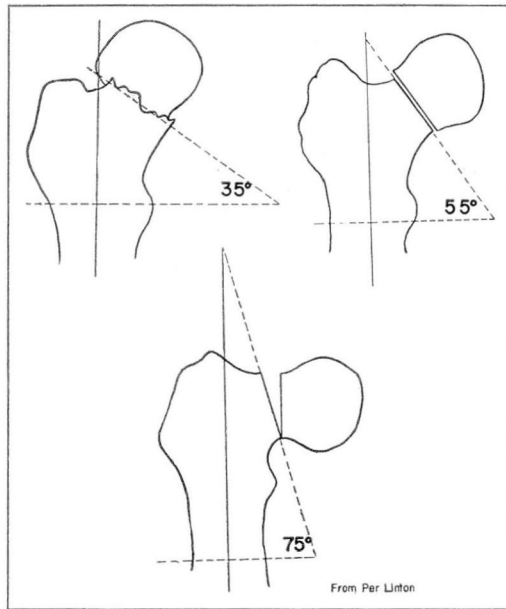


FIG. 2. Mechanical analysis of fractures at neck of femur, according to Linton.

and to prevent bony union and reestablishment of circulation and revascularization. They all agree also that in fractures in which the unfavorable shearing stress is greatest, the incidence of nonunion and other complications is highest. Conversely, when the angle of the fracture is such that the fragments are in an impacting position, treatment usually is satisfactory and complications rarely occur.

To appraise this mechanical factor in the individual case I prefer Linton's method of measuring the angle (fig. 2), since it is simpler than the others and is not affected by adduction or abduction of the leg. The roentgenogram is made with the leg in internal rotation, and the angle measured in relation to the femoral shaft. Linton classifies intracapsular fractures into three groups according to the angle between the line of fracture and the perpendicular to the long axis of the femur. If this angle is less than 35 degrees the fracture is in an impacting position, there is no shearing stress, and it will unite soundly with any type of treatment (group I). It is probably in fractures of this type that the majority of instances of successful healing occurred before the advent of internal nailing. If the angle is between 35 and 60 degrees, there is less impaction and some shearing strain. Fractures of this type (group II) probably will not unite unless this shearing force is overcome by internal fixation. It is probably this group that accounts for most of the additional 30 per cent of cases of femoral neck fractures in which healing occurs since the method of internal fixation was introduced. When the angle of the fracture plane is 60 to 80 degrees, the fracture line is so nearly vertical and the effect of shearing

stress is so great that nonunion or other complications may be anticipated (group III), regardless of whether a Smith-Petersen nail, multiple pins, or the lag screw is used as the method of internal fixation.

Since the principal blood supply to the head of the femur is by way of the medullary vessels which pass through the neck (fig. 1), it is obvious that when the fracture is in an impacting position there will be relatively prompt reestablishment of the blood supply to the head, that bone healing will progress, and that atrophic changes in the head will be prevented. Conversely, it is to be expected that when shearing strain causes pulling apart of the fractured surfaces, reestablishment of circulation through the neck of the femur is delayed or prevented. When the blood supply is thus impaired, fibrotic and atrophic changes ensue, with eventual degeneration and necrosis of bone. Whether or not this bony change occurs depends on the degree of interruption of the blood supply, as determined by the angle of the fracture and its position within the capsule. This demonstrates the importance of the mechanical factor in relation to the circulatory factor in intracapsular fractures of the femur. When shearing force makes impaction impossible and circulation of the head fragment is greatly impaired, union is delayed or prevented. If the process of healing is too slow, it seems reasonable to assume that serious atrophic changes may develop in the head, even though bony union eventually takes place.

The recognition of the fundamental importance and correlation of the mechanical and circulatory factors in intracapsular fractures of the neck of the femur makes possible a reorientation of our conceptions and the formulation of principles leading to modifications in the method of treatment of ununited fractures.

Treatment of Ununited Fractures of Neck of Femur

In the treatment of ununited fractures in other parts of the skeletal system, it has long been recognized that satisfactory results depend on the correction of faulty mechanics and stimulation of osteosynthesis by bone grafting as soon as possible after evidence of nonunion appears. However, in treating ununited fractures of the neck of the femur, when evidence of nonunion appeared, we have tended to wait for months, and even years, in the vain hope that union might eventually occur. This almost never happened, and then, even when secondary intervention was resorted to, we have not made use of the principles of combined surgical treatment that have proved successful in other parts of the body. Instead we have relied either on bone grafting and failed to take into account the mechanical factor largely responsible for the nonunion or on osteotomy, attempting to place the fracture in an impacting position, doing nothing to replace the fibrous tissue which had formed at the fracture site and thus facilitate osteogenesis and revascularization of the head.⁴

Both bone grafting and osteotomy, by themselves, are only partial procedures, in that each fails to consider the problem as a whole. Figure 3, showing the principal bone grafting procedures that have been recommended, and fig. 4, showing the usual types of osteotomy operations, clearly exhibit the disadvantages of each when used separately. One of the principal difficulties encountered with the various osteotomy procedures has been the lack of definite

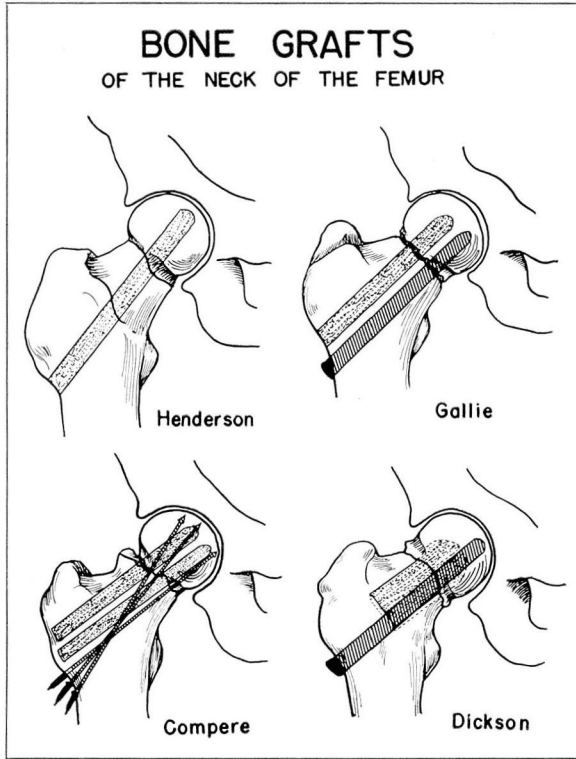


FIG. 3. Various types of bone-grafting procedures used for ununited fracture of the neck of femur.

control over the head of the femur and the upper trochanteric segment and their proper placement when the shaft of the femur is displaced medially. In many instances the head of the femur is not rotated sufficiently and the fragments are not correctly placed to facilitate bony union and repair. Both bone grafting and osteotomy have produced satisfactory results in a certain proportion of cases, and the individual surgeon, on the basis of his own experience, has tended to develop a preference for one or the other. This empirical attitude has undoubtedly been responsible for many failures by both methods, since it has failed to recognize that a certain proportion of cases in which bone grafts are used will result in failure when shearing force on the fracture line remains great, and also that an osteotomy will not be successful when the desired impaction is not obtained because of lack of accurate control of the rotation of the head or when the degenerative fibrous process at the fracture site has progressed so that circulation cannot be reestablished through the neck to stimulate osseous repair.

A critical analysis of my own results with various technics, of both bone grafting and osteotomy, and a review of the literature concerned with various

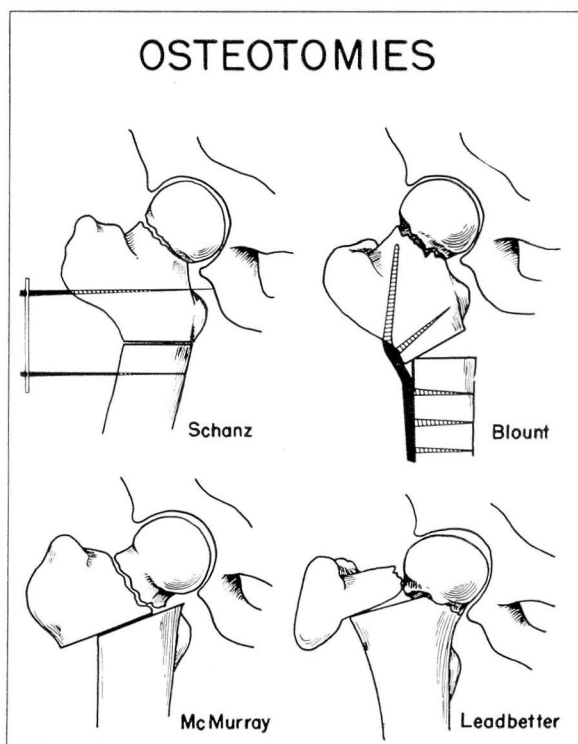


FIG. 4. Various types of osteotomies used for ununited fracture of neck of femur.

methods,² demonstrated that the proportion of failures of operations on ununited fractures of the femoral neck is remarkably similar with all methods, amounting quite generally to 35 to 50 per cent of all cases subjected to secondary procedures. This analysis, together with a study of the basic mechanical and circulatory factors, led to the idea that if the advantages of the various procedures could be combined, with the aim of correcting faulty mechanics and of restoring circulation and stimulating bone formation, in a single operation, perhaps these results might be improved.

Examination of a series of roentgenograms of ununited fractures of the femoral neck showed that in most instances there was a downward rotation of the head of about 60 degrees (figs. 5 and 6). Furthermore, measurement of the angle of the fracture line in relation to the femoral shaft by Linton's method showed that in all instances this was high, that is, over 65 degrees.

After full consideration of all the foregoing data it seemed evident that, in order to rotate the head to its normal anatomic relationship within the acetabulum, to overcome mechanical stress, and to assure impaction of the fractured surfaces, a rotation of 60 degrees of the upper part of the shaft and head of the femur should be accurately and consistently obtained. The fracture would then always be in group I, according to Linton's classification, and

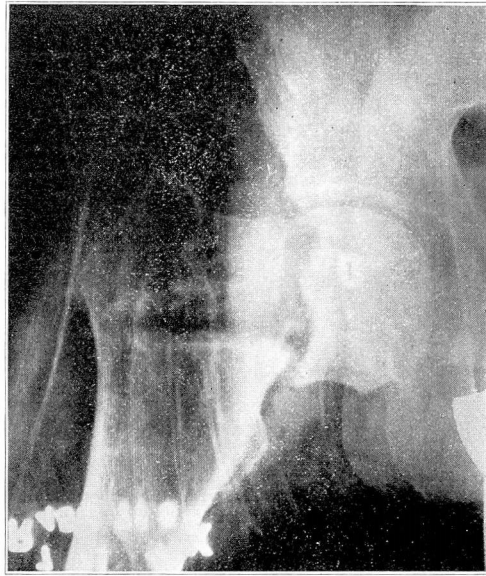


FIG. 5. Roentgenogram of typical ununited fracture of femoral neck.

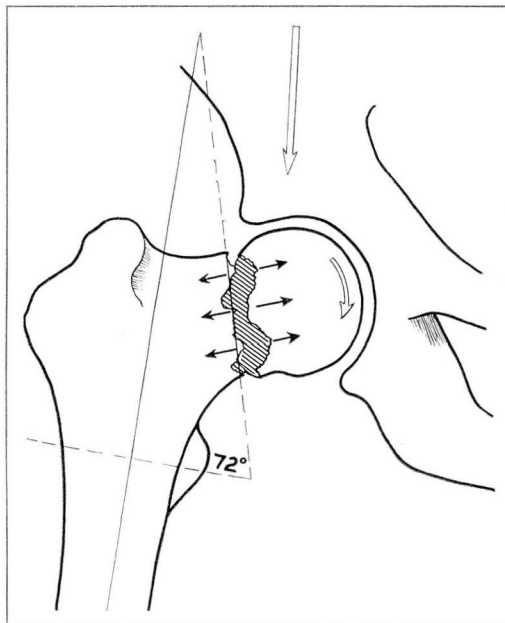


FIG. 6. Mechanical analysis of fracture shown in fig. 5.

satisfactory healing should occur. Since bone grafting stimulates osteogenesis, it also seemed logical and desirable that this 60-degree rotation of the head and trochanteric segment should be combined with bone grafting. With this procedure the old scar and fibrous tissue that had formed at the site of the nonunion could be removed and replaced with new cancellous iliac bone. The graft would give added stability across the fracture, would act as a guide to the formation of granulation tissue, and would aid in revascularization of the head. This would facilitate the restoration of circulation from the trochanteric segment to the head and lead to more rapid healing. The bone graft would also aid in preventing overimpaction.

Technic of Operation

A combined procedure was developed to incorporate all these principles. The technic is shown in figs. 7, 8, 9, 10, and 11.

The trochanteric portion and the head of the femur are transfixed with a blade plate or Smith-Petersen nail with blade attached (Jewett nail), penetrating from the lateral prominence of the trochanter into the lower half of the head to assure accurate control of the head and trochanteric segment. In anticipation of a 60-degree rotation, the shaft of the plate should extend outward at an angle of 60 degrees to the long axis of the femur so that proper placement of the plate may be readily accomplished after the osteotomy and necessary rotation are completed (fig. 7).

If the trochanteric section is considered as a regular hexagon (fig. 8) and rotated by one segment, a 60-degree rotation is accomplished. Hence the osteotomy should be made along two sides of what would be a regular hexagon. To obtain the proper position and shape of the osteotomy it was necessary to devise a hemihexagonal marking chisel in which the long diameter equals the distance from the lateral prominence of the trochanter, where the fixation plate or nail entered, to the upper surface of the lesser trochanter (fig. 7, D). By placing this marker on the anterior surface of the femur with one side parallel to the flare of the trochanter as it extends downward from the entrance of the nailplate, the exact site for the osteotomy is determined (fig. 9). If a marker of proper size is used, the lower medial edge of the marker always comes out just above the lesser trochanter, thus assuring a high osteotomy. The upper transfixed fragments are then rotated so that side A is brought into the position of A' (fig. 9), giving an accurate 60-degree rotation. The plate assumes its proper place along the shaft of the femur, and a stable contact of fragments, with a perfect fit, results (fig. 10).

When the osteotomy and rotation have been completed, a window is made in front of the trochanteric segment just distal to the fracture site (fig. 11). This readily allows removal of sclerotic bone and fibrous tissue and curettage up into the head to facilitate placement of the graft. Numerous chips of cancellous bone are impacted well across the fracture line, and one large graft is then fixed into position to give added stability. The window removed is then replaced. Cancellous bone is used for the graft because it has superior osteogenic power.

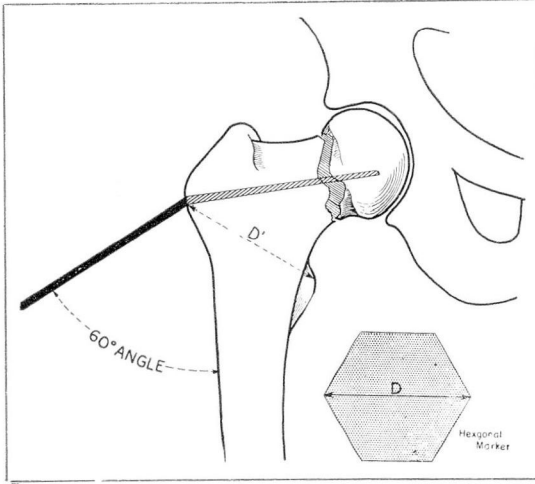


FIG. 7. Transfixion of upper segments with blade at 60 degrees. D' is measured to determine the long diameter of chisel used for marking the site of osteotomy.

FIG. 8. Placement of hexagonal marker to determine site of osteotomy.

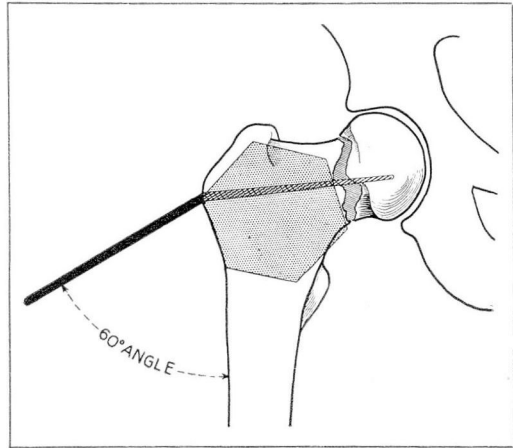
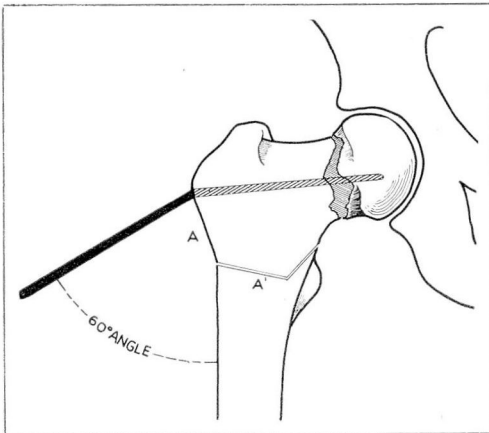


FIG. 9. Site of osteotomy.



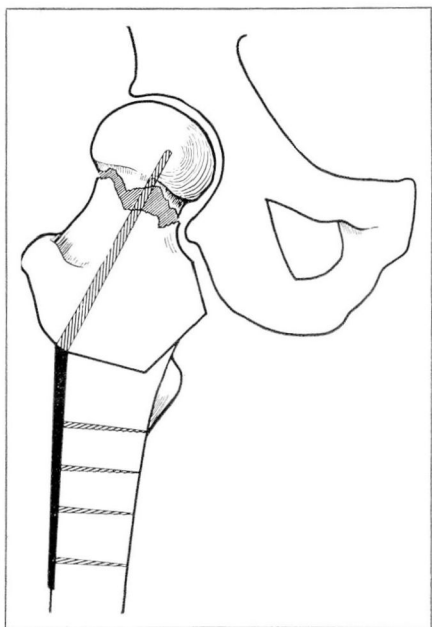


FIG. 10. Rotation of femoral head and trochanteric segment and fixed position of the blade.

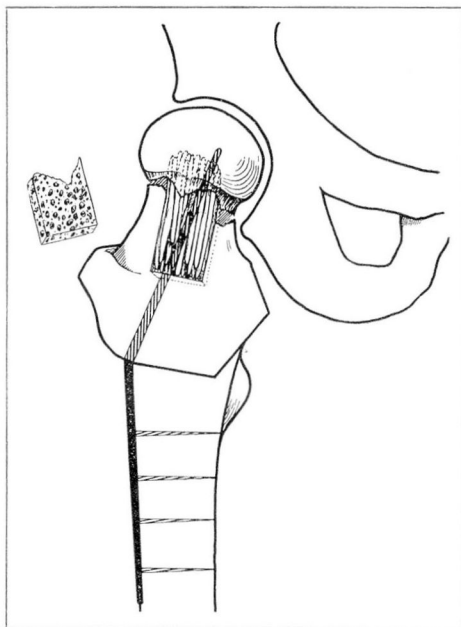


FIG. 11. Window of bone removed to allow curettement of fibrous tissue and placement of bone graft.

A typical case is illustrated in fig. 12. This patient, a man, aged 64, had had a fracture of the neck of the femur ten months previously in which a lag screw had been used for internal fixation; nonunion had resulted.

After the proper preparation and anesthetization (with pentothal and inhalation of nitrous oxide and oxygen), the patient is arranged on the table with the affected hip fixed in internal rotation. It is preferable to have two x-ray units so that both anteroposterior and lateral roentgenograms of the hip can be readily made. This saves much time and facilitates draping of the patient. A preliminary roentgenogram is made so that traction, abduction, and rotation can be adjusted to secure the optimal position.

The region of the fracture is approached by a curved lateral incision between the tensor fascia femoris and the gluteus medius muscles or by an anterior iliofemoral incision. The incision is carried down the outer side of the shaft about 6 or 7 inches to facilitate fixation of the plate. The joint capsule is opened and the incision is carried outward with medial reflection of the muscles on the anterior surface of the femur. This allows adequate exposure with minimum interference with the blood supply.

The Smith-Petersen nail, lag screw, or other type of internal fixation previously used can now be removed readily. The outer surface of the femur is exposed subperiosteally, and a bed is prepared for the reception of the plate after the osteotomy has been completed. A guide pin is then passed from a

point just a little above the prominence of the greater trochanter into the lower half of the head of the femur. This is accomplished with the aid of a special protractor which assures that the pin is placed at a right angle to the long axis of the femur (figs. 13 and 14).

Roentgenograms are made to check the position of the pin and the length of blade that will be required. The blade length varies from $2\frac{1}{4}$ to $2\frac{3}{4}$ inches. A proper-sized Jewett nail with an angle of 150 degrees is then threaded over the wire, and the nail is securely fixed as the fractured surfaces are impacted. The plate of the Jewett nail will then extend from the shaft at an angle of 60 degrees. (If there has been little absorption of the neck and the head is riding high in relation to the prominence of the trochanter, it may be advisable to insert the guide wire at 75 degrees to the long axis of the femur and to use a Jewett nail with an angle of 165 degrees.)

The lesser trochanter is palpated, and the distance from the prominence of the greater trochanter, where the blade enters, to the upper surface of the lesser trochanter is calculated with a caliper (fig. 15). A hemihexagonal chisel, with a diameter of this width, is chosen from the set of five chisels with diameters varying in width by $\frac{1}{8}$ inch from $1\frac{3}{4}$ inches to $2\frac{1}{4}$ inches (fig. 16). The chisel selected is then used to mark the site of the osteotomy. When the proper-sized marking chisel is used and placed vertically on the anterior surface of the femur with the diameter extending from the entrance of the blade to the lesser trochanter, one side of the marker extends beyond the flare of the trochanter (fig. 17). If the chisel is now rotated slightly so that one side runs

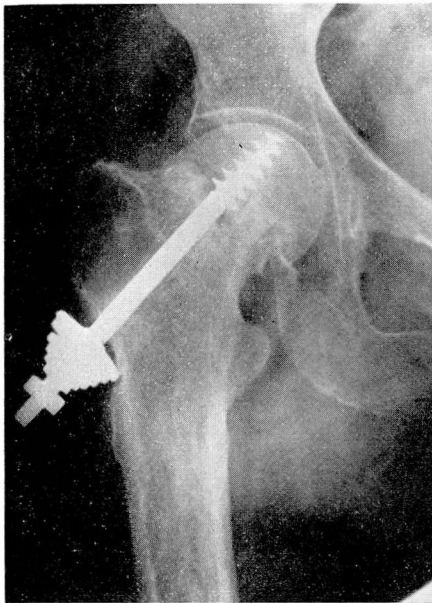


FIG. 12. Preoperative roentgenogram showing nonunion.

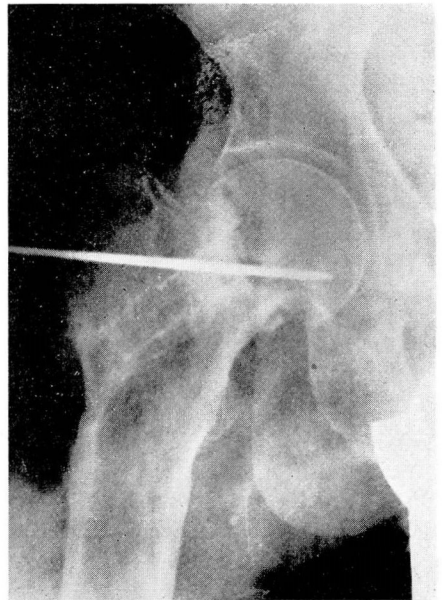


FIG. 13. Roentgenogram showing placement of guide wire.

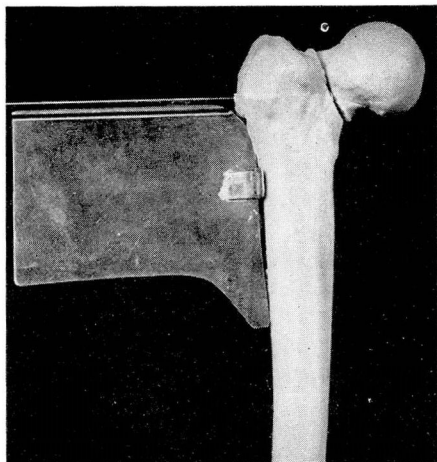


FIG. 14. Special protractor used to assure a 60-degree projection of plate.

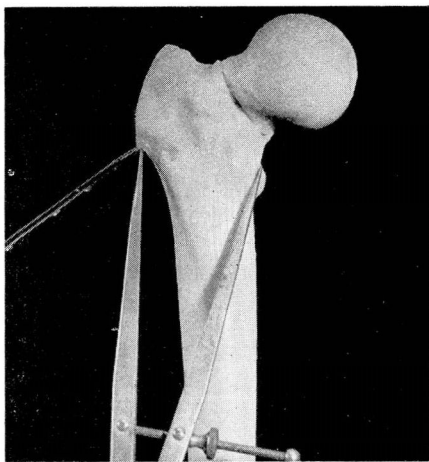


FIG. 15. Method of measuring diameters of special chisels.

parallel to the flare of the trochanter, extending downward from the entrance of the blade, the site of the osteotomy can be marked along the other two blades. This brings the inner blade out just above the lesser trochanter, thus assuring a high osteotomy (fig. 18). If too small a marker is chosen, the osteotomy will extend into the femoral neck (fig. 19) and much of the support of the head segment will be lost. If too large a chisel is used, the osteotomy will come out below the lesser trochanter (fig. 20), and the impacting force of the psoas will not be procured. The measurement determining the choice of the proper marking chisel is extremely important if optimal results are to be obtained from the osteotomy.

The osteotomy is carefully completed with a sharp, thin osteotome. A little traction is applied at this stage, and the osteotomy site is thoroughly mobilized. The shaft of the femur below the osteotomy is then lifted forward so that the upper segment can rotate freely beneath it. Additional traction is applied, and the leg is brought into slight abduction. The two segments are then manipulated slightly forward, and the bone is placed in its new position. The manipulation must be gentle to guard against any fracture of the trochanteric segment. Traction is then released and the blade plate securely fixed to the shaft of the femur (fig. 21).

When the osteotomy and rotation have been completed, a window is made in the anterior surface of the trochanteric segment, just distal to the fracture site. This readily allows removal of sclerotic bone and fibrous tissue and curettage up into the head to facilitate placement of the graft. Numerous chips of cancellous bone from the ilium are impacted well across the fracture line, and one large graft is then fixed into position to give added stability. The removed window is then replaced. Cancellous bone is used because it has superior osteogenetic power.

SET OF SEMI-HEXAGONAL CHISELS SHOWING MOST FREQUENTLY USED DIAMETERS

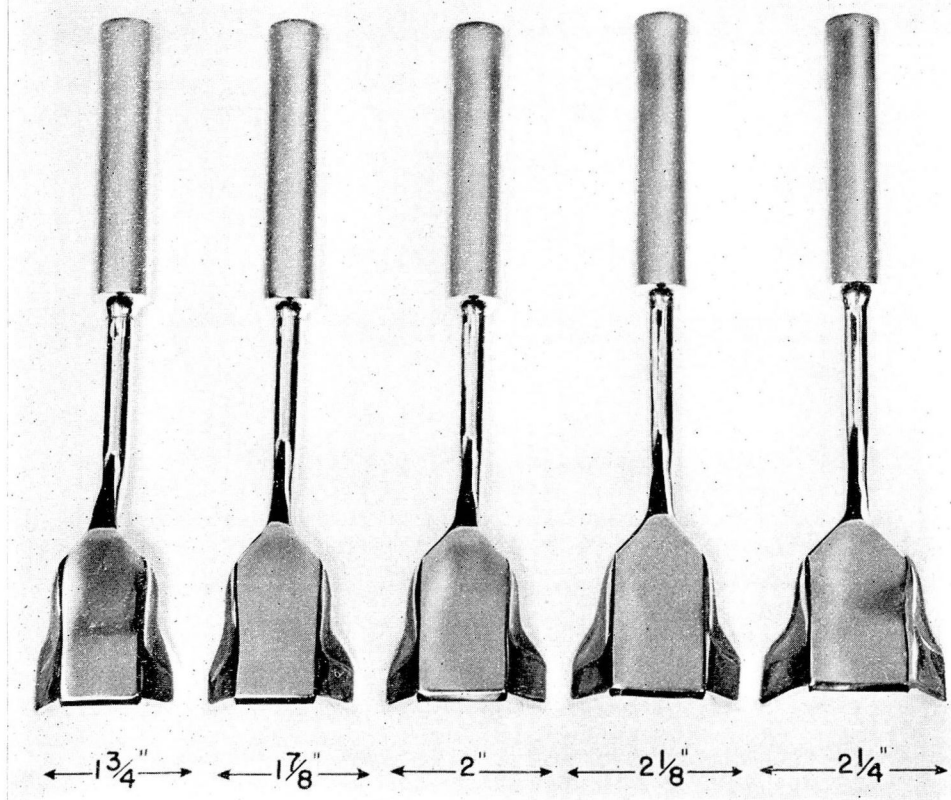


FIG. 16. Set of five hemihexagonal chisels for marking the site of osteotomy.

After operation, internal rotation is maintained in balanced traction or with a plaster boot and bar for six to eight weeks. On the first postoperative day, the prothrombin time is determined and 300 mg. of dicumarol is administered. The prothrombin time of the blood is repeatedly determined, and supplementary doses of dicumarol are given as indicated to keep the prothrombin level at 30 to 50 per cent of normal. This check is continued for a ten-day period. At the end of six weeks the patient is allowed to be out of bed and on crutches. Roentgenograms are made as progress studies from time to time, and protection from weight-bearing is continued until there is evidence that the head is thoroughly revascularized.

Fortunately this type of rotation osteotomy equalizes leg length; the greater the varus deformity before operation, the greater the length procured. In an adult of average size, the increase in leg length after the rotation osteotomy

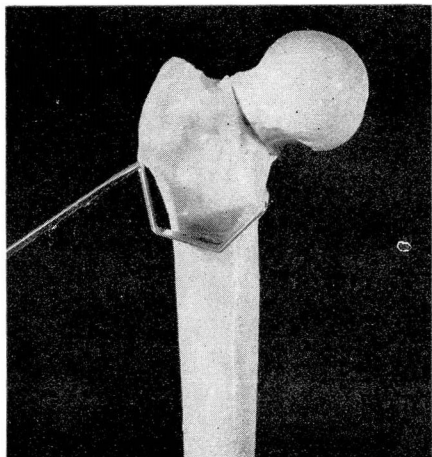


FIG. 17. Preliminary placement of chisel with correct diameter.

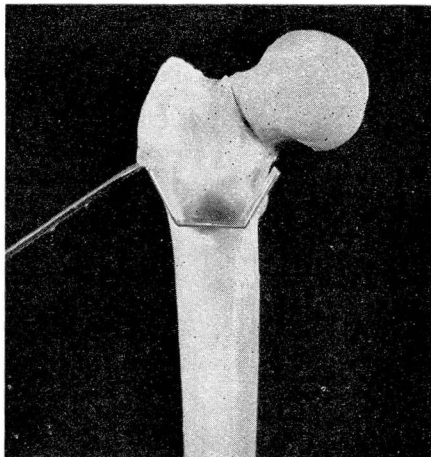


FIG. 18. Placement of chisel to mark osteotomy site.

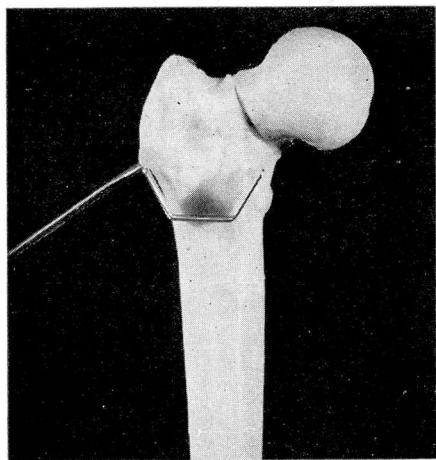


FIG. 19. Effect of using too small a chisel.

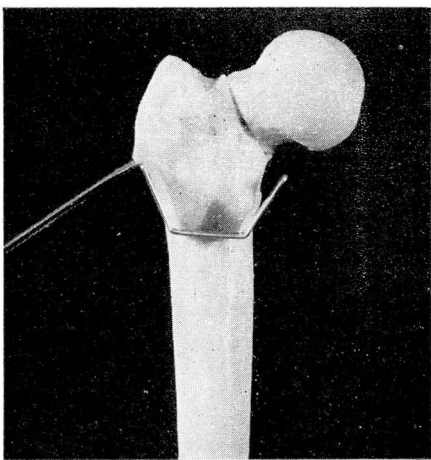


FIG. 20. Effect of using too large a chisel.

amounts to $\frac{3}{4}$ to $1\frac{1}{2}$ inches (figs. 22 and 23). The elimination of the disadvantage of leg shortening, which has been usual with other types of osteotomy, is a feature of this type of operation that appeals strongly to the patients.

Results

This approach to the treatment of ununited fractures of the neck of the femur has produced most encouraging results, of which the following case is typical. A man, aged 42, had fractured his right hip in July, 1944. Primary treatment consisted of supracondylar traction with a Steinmann pin for three months;

he was then placed in a plaster spica for six months. When he first consulted me a year and nine months after his injury, there was an ununited fracture of the neck of the right femur, with $1\frac{1}{2}$ inches of shortening of the leg (fig. 24). Operation was performed on May 15, 1946, and balanced traction was applied until June 22. He was walking on crutches in July.

The patient's lower extremities were of equal length. Protection with the use of crutches was continued for one year. Full range of motion was procured, and the roentgenogram taken eighteen months after operation (fig. 25) showed excellent union with revascularization of the head of the femur.

In some of the cases dealt with so far the nonunion has been of long standing, and in several, roentgenograms showed increased density in the head

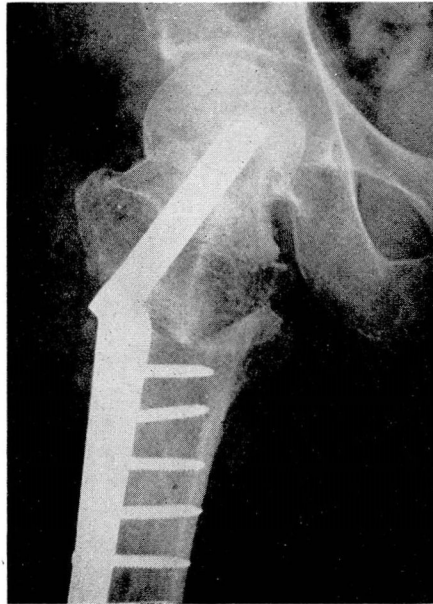

FIG. 21. Roentgenogram showing position obtained by the osteotomy and rotation in case shown in fig. 12.

fragment, indicating a considerable degree of aseptic necrosis. Later there has been roentgenographic evidence of the formation of healthy bone, indicating that circulation to the head has been reestablished through the medullary vessels of the neck as a result of the combined operation.

The restoration of circulation to the head in these cases, and also in some cases reported by others after bone grafting or osteotomy procedures, naturally suggests that perhaps we should question the concepts previously taught regarding necrotic heads after femoral neck fractures. Although no definite dictum can be offered on the basis of present knowledge, it seems desirable at this point to question the practice of sacrificing all so-called dead heads and resorting to reconstructive operations, as some authorities recommend. It

would seem wiser to assume a cautious and conservative attitude toward the removal of dead heads, since according to the facts cited, there is possibility for regeneration of bone in a large proportion of these cases. Nevertheless, we must not lose sight of the fact that although there may be some question as to the degree of vascular damage, there is no question that the nutrition of heads which show increased density on the roentgenogram has been impaired. If the head is not protected during the period while new bone is forming, atrophic and arthritic changes are almost certain to occur.

Plea for Earlier Treatment

Since the combined osteotomy and bone-grafting operation has resulted in evidence of bone regeneration and revascularization in roentgenologically dead heads in cases of two and three years' duration, it seems logical to assume that the treatment might be expedited and the results more certainly favorable in earlier cases of nonunion. When it is recognized that nonunion is developing, this fact should be accepted immediately and an appropriate operation for correction carried out then. Elsewhere in the body, when it is recognized that a fracture is not uniting, bone grafting is resorted to, usually with successful results and much saving of time and disability for the patients. However, when a hip fracture is not uniting, the tendency is to "wait and see" while the condition goes from bad to worse. The longer operation is delayed the greater the degree of atrophic changes in the head and the more problematic the results of secondary treatment. The earlier the operation is performed after nonunion is recognized the better the results should be.

Slipping of the fractured surfaces is usually discerned on the roentgenogram within the first few weeks, and in the vast majority of cases in which this occurs the situation progresses steadily, and there is eventual nonunion. If

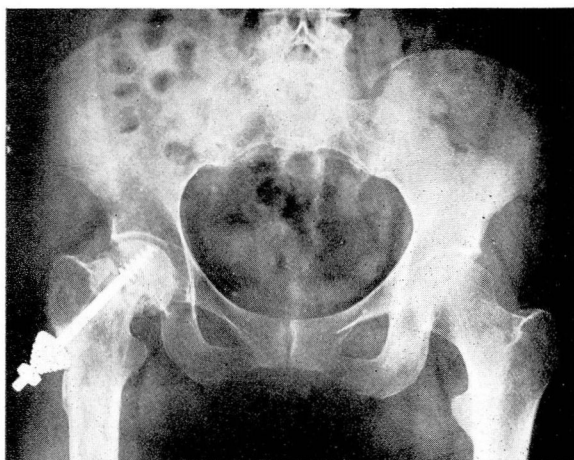

FIG. 22. Roentgenogram showing degree of leg shortening before operation in case shown in fig. 12.

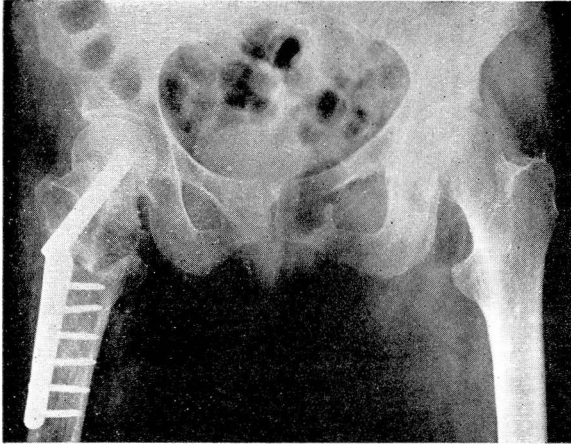


FIG. 23. Roentgenogram showing equalization of leg length after operation in case shown in fig. 12.

FIG. 24. Preoperative anteroposterior roentgenogram, showing nonunion of femoral neck fracture one year and nine months after injury.

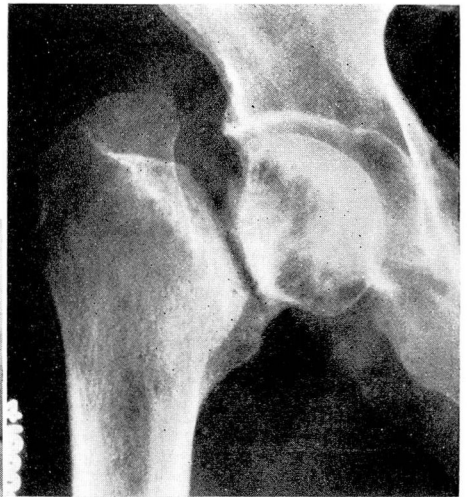
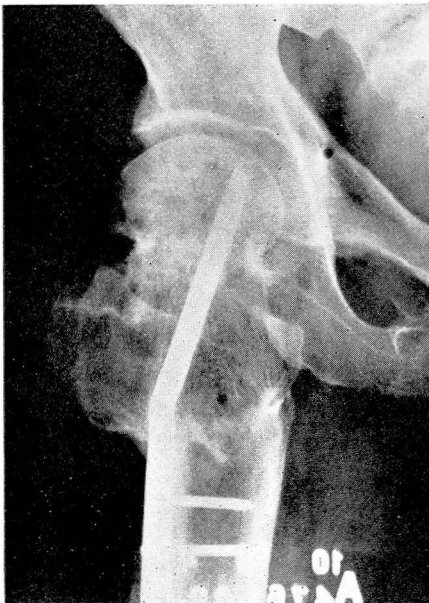
FIG. 25. Anteroposterior roentgenogram eighteen months after operation in case shown in fig. 24, showing union and revascularization of the head.

union does finally occur in such cases, it is long delayed and is usually accompanied by severe atrophic changes. In these cases, instead of waiting and hoping blindly for a favorable outcome, which almost never happens, the secondary operation should be performed immediately, assuming that the patient's general condition warrants it. This would establish impaction and revascularization and regeneration of bone before all the troublesome fibrosis and atrophic changes have occurred to complicate the situation. If early recognition and early treatment of nonunion were systematically and generally carried out, the necessity for the more formidable reconstructive operations should be reduced to a minimum.

Several of the illustrations used in this article have been supplied through the courtesy of The Journal of Bone and Joint Surgery. October, 1947.

References

1. Pauwels, F.: Der Schenkelhalsbruch ein mechanisches Problem. Grundlagen d. Heilungsvorganges, Prognose und kausale Therapie. (Stuttgart: Ferdinand Enke, 1935.)
2. Linton, P.: On different types of intracapsular fractures of femoral neck; surgical investigation of origin, prognosis and complications in 365 cases. Acta chir. Scandinav. **90**:1-122, 1944.
3. Eyre-Brook, A. L., and Pridie, K. H.: Intracapsular fractures of neck of femur; final results of 75 consecutive cases treated by closed method of pinning. Brit. J. Surg. **29**:115-138 (July) 1941.
4. Dickson, J. A.: High geometric osteotomy, with rotation and bone graft, for ununited fractures of neck of femur. J. Bone and Joint Surg. **29**:1005-1018 (Oct.) 1947.