

TREATMENT OF GASTRIC ULCER

The Difficulty of Differentiating Peptic Ulcer from Carcinoma of the Stomach

GEORGE CRILE, JR., M.D., and WILLIAM S. DEMPSEY, M.D.

Division of Surgery

PRIOR to Dragstedt's popularization of vagotomy, gastric ulcer usually was treated by gastric resection. The results of gastric resection for gastric ulcer were good, and the operation afforded maximum protection against the presence or development of carcinoma.

Recently the good results that have been obtained by vagotomy in the treatment of duodenal ulcer and marginal ulcer have led to its use also in cases of gastric ulcer. Our experience with vagotomy in a small series of selected cases of gastric ulcer has been disappointing and has shown the danger inherent in assuming that any ulcerating lesion of the stomach is benign. Two cases are presented in tabular form to emphasize the difficulty of distinguishing between benign and malignant ulcers of the stomach and to point out the importance of removing the ulcer whenever it is possible to do so.

In one case a shallow ulcer, 0.5 cm. in diameter, appeared to be healing and was not demonstrable either by roentgenogram or by gastroscopy. Both the surgeon and the pathologist considered it to be benign until permanent pathologic sections proved it malignant. One side of this lesion was a benign ulcer showing no evidence of carcinoma, and it was from this area that the biopsy specimen was taken. However, permanent sections showed the other side to be an infiltrating carcinoma. In a second case a huge deep ulcer measuring 6 cm. by 4.5 cm., which the roentgenologist and the surgeon had assumed to be carcinoma, proved to be benign.

The Nature of Gastric Ulcer

Gastric ulcer and duodenal ulcer have different consequences and require different treatments. The treatment of gastric ulcer is primarily surgical, involving excision of a potential cancer, whereas the treatment of duodenal ulcer is essentially medical and requires operation only when the symptoms are rendered intractable by complications. Moreover, we must not assume that because vagus resection with gastroenterostomy or pyloroplasty is the preferred surgical treatment for duodenal ulcer that the same treatment is equally applicable to gastric ulcer.

In patients with gastric ulcer the acidity of the gastric juice tends to be normal or even low. After a gastroenterostomy for gastric ulcer there is little or no tendency for ulceration to recur in the jejunum. Gastric ulcer is less common than duodenal ulcer, attacks people of an older age group, and affects women more often than does duodenal ulcer.

The results of gastric resection for gastric ulcer are excellent. The mortality rate is low because there is no problem of closing the duodenal stump. Marginal ulcer is exceedingly rare. The resections need not be so radical as in duodenal ulcer unless the lesion is located very high.

Final diagnosis:	Carcinoma of stomach.	Peptic ulcer, benign.
Patient:	Woman, aged 41.	Man, aged 60.
History:	Peptic ulcer five years, occasional tarry stools, one large hematemesis in January, 1945.	Peptic ulcer two years. Excision of gastric ulcer elsewhere in February, 1947. Symptoms recurred in three months.
Roentgenologic Examination:	Stomach normal.	Annular defect in pars media with large ulcer crater along lesser curvature. 30 per cent gastric retention in six hours. Impression: gastric neoplasm.
Gastroscopic Examination:	Stomach normal.	None.
Laboratory Examination:	Gastric analysis: <div style="text-align: right;">Free 24</div> <div style="text-align: right;">Total 40</div> Hemoglobin 8 Gm. (Recent hemorrhage)	Gastric analysis: <div style="text-align: right;">Free 48</div> <div style="text-align: right;">Total 60</div> Hemoglobin 13 Gm.
Preoperative Diagnosis:	Peptic ulcer.	Carcinoma of stomach.
Operation and Pathologic Examination:	<p>Sept. 22, 1947. Excision shallow ulcer 0.5 cm. in diameter approximately 2.5 cm. below cardioesophageal junction on lesser curvature. Ulcer apparently healing. Impression of surgeon: healing peptic ulcer.</p> <p>Frozen section: no evidence of malignancy. Bilateral vagus resection and gastroenterostomy. Permanent section from another portion of ulcer; adenocarcinoma, poorly differentiated, arising in chronic peptic ulcer (fig. 1).</p> <p>Sept. 29, 1947: Wide resection of area of previous excision of gastric ulcer.</p>	<p>Nov. 17, 1947. Subtotal gastric resection. Impression of surgeon: carcinoma of stomach.</p> <p>Gross specimen: ulcer 6 x 4.5 cm. with crater 1.5 cm. deep, dumbbell-shaped and annular 6.5 cm. above pylorus. Chronic peptic ulcer with no evidence of malignancy. Frozen section and permanent sections confirmed benign nature of lesion (fig. 2).</p>

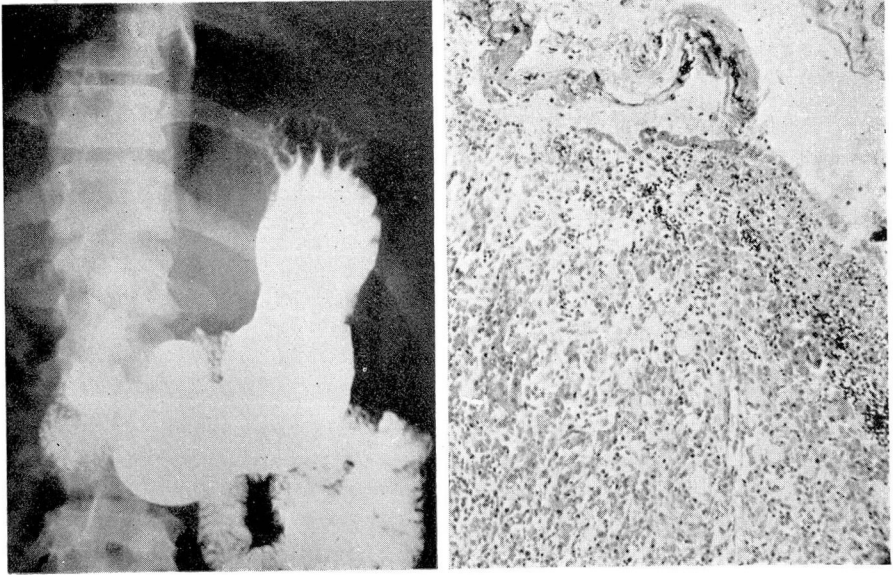


FIG. 1. Adenocarcinoma of the stomach apparently arising in a chronic peptic ulcer.

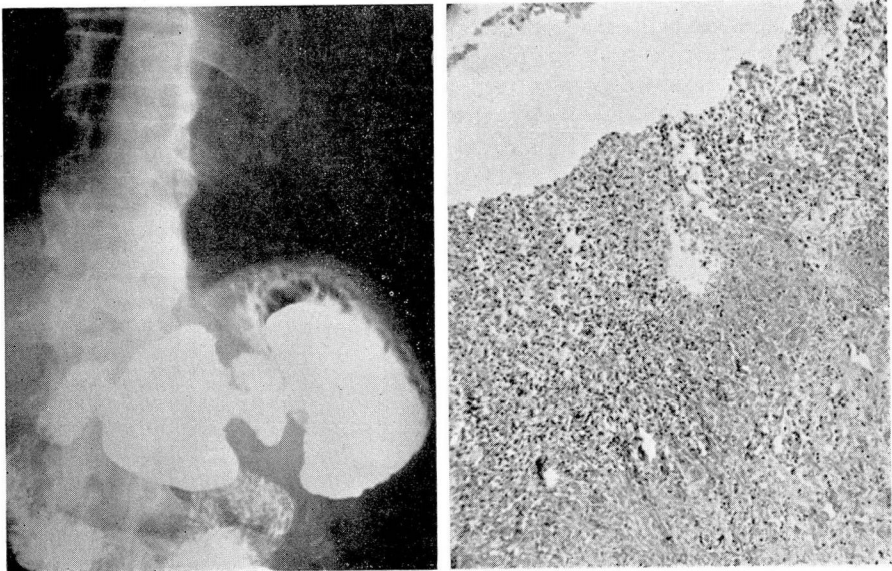


FIG. 2. Chronic peptic ulcer of stomach showing no evidence of malignancy.

Indications for Operation for Gastric Ulcer

Since gastric ulcer cannot be certainly differentiated from gastric carcinoma either by roentgenologic examination, by gastroscopy, or by analysis of clinical data, its treatment is primarily a surgical problem. By this it is not implied that all gastric ulcers should be resected as soon as the diagnosis is made and without a trial on medical therapy. But large gastric ulcers, recurrent gastric ulcers, and gastric ulcers which persist in spite of an adequate trial of a month of medical treatment should be resected unless strong contraindications are present. The criteria of healing are failure of the roentgenologic or gastroscopic examination to demonstrate an ulcer, complete subsidence of symptoms, and disappearance of blood from the stool.

Because gastric resection gives maximum protection against the development of carcinoma or against its recurrence in the event that the lesion is malignant, gastric resection is the preferred treatment for most cases of gastric ulcer. In a small series of patients with gastric ulcer who were subjected to vagotomy without excision of the ulcer the results have been only fair. Two of the 14 patients have had persistence or recurrence of symptoms, and in these cases the possibility of malignancy cannot be excluded. Vagotomy is not recommended unless the ulcer is excised and examined microscopically.

If the ulcer is on the lesser curvature it cannot be excised without disturbing the motility of the stomach. The shortening of the lesser curvature or the disturbance of the peristaltic wave or a combination of these factors may interfere with the emptying of the stomach and cause retention. Vagotomy increases this tendency. Therefore, if an ulcer on the lesser curvature is treated by excision and vagotomy, a gastroenterostomy also should be made. But the combination of vagotomy, excision of the ulcer, and gastroenterostomy is about as formidable a procedure as gastric resection and is attended by no better results. For this reason gastric resection is preferable.

If the ulcer is small and is located on either the anterior or posterior wall, it can be treated by excision and vagotomy without gastroenterostomy. The results in these cases are good, but the number of ulcers adaptable to this treatment is small.

If the ulcer is so high on the lesser curvature that nothing short of a total or subtotal gastrectomy could effectively remove it, or in cases in which the technical difficulties of resection are so great that the danger of resection outweighs the danger that the lesion may be a carcinoma, vagotomy alone, preferably accompanied by a biopsy, may be preferable to the risk of resection. Again these cases are not common and afford only an occasional indication for the treatment of gastric ulcer by vagotomy.

Biopsy of gastric ulcers is not a satisfactory method of excluding the possibility of carcinoma. Excision is much more certain but is not always practicable. In those cases in which technical difficulties render resection or excision undesirable, a biopsy can be taken with a biopsy forceps introduced through a small gastrotomy or, in the event that a gastroenterostomy is made, through the stoma. Specimens may be obtained even from the highest lesions in this man-

ner. Two or three specimens from different parts of the margin of the ulcer should be taken because it is not always possible for the pathologist to determine the presence of malignancy on the basis of a single biopsy. Furthermore, as in the case reported, one part of the ulcer may be benign and another part malignant. Since these difficulties are avoided by gastric resection and since the results of resection are so good, it should be employed as the preferred treatment except in special cases.

Summary

1. It is not always possible to distinguish between peptic ulcer and carcinoma of the stomach.
2. Most cases of gastric ulcer requiring operation should be treated by gastric resection rather than by vagotomy.
3. Vagotomy for gastric ulcer is not recommended unless (a) the ulcer is excised and examined microscopically or (b) the ulcer is so high that it cannot be resected without performing a total gastrectomy or incurring undue risk.