

GLAUCOMA

ROSCOE J. KENNEDY, M.D.

Department of Ophthalmology

GLAUCOMA which involves an increase in the intraocular pressure is one of the most serious problems in ophthalmology. This increase in pressure is generally due to a disturbance between the production and the absorption of the aqueous humor, although many factors enter into this. Since the normal pressure varies from 15 to 30 mm. of mercury anything higher is considered abnormal.

For convenience glaucoma is usually divided into several types:

1. Primary including (a) acute congestive, (b) chronic simple, and (c) absolute.
2. Secondary.
3. Congenital (buphthalmos and hydrophthalmos).

Sudden loss of sight, severe and excruciating pain, and possibly associated vomiting are characteristic for acute congestive glaucoma. Usually the patient is not aware of any prodromal signs, although these may be present, such as halos about lights and transient attacks of mild pain. One eye only is commonly involved although there is a tendency for the other eye to become affected later. Examination may reveal some edema of the eyelid and there is usually congestion of the bulbar conjunctiva. The cornea is steamy and the anterior chamber is almost obliterated. The pupil is mildly dilated and fixed. Usually the fundus cannot be seen. The intraocular pressure is elevated, often measuring as high as 80 to 90 mm. of mercury.

The patient is frequently in such pain that an examination is difficult, but vision may be reduced to light perception. Visual field changes usually cannot be obtained due to the severe pain from which the patient is suffering. Treatment consists of the prompt use of miotics, such as 1 per cent eserine, D.F.P. (0.1 per cent). Morphine should be prescribed for pain as needed. If the attack does not subside within a few hours with the use of miotics, surgical intervention is indicated. It is generally believed that if the pressure is not reduced within forty-eight hours sight is irreparably damaged, and therefore surgery should not be postponed. The operation of choice is basal iridectomy, although there is a growing tendency to prefer iridencleisis if the attack is prolonged more than twelve hours. The prognosis in such cases is good if the intraocular tension is reduced to normal within forty-eight to seventy-two hours.

The following illustrates a typical case of acute congestive glaucoma.

Case 1. A man aged 66 was first seen in May 1945, at which time his visual acuity was 6/30 in each eye. Visual fields were not diagnostic. Intraocular tension at this time was 25 mm. of mercury (Schiotz) in each eye. On June 4, 1945 the patient developed an increased intraocular pressure in the right eye. On June 7, 1945 a basal iridectomy was performed following which the patient made an uneventful recovery. About one and a half years later

a cataract extraction was done, after which the patient developed an increased intraocular pressure, necessitating enucleation of the right eye on January 29, 1946. He made an uneventful recovery. In February 1947, the visual acuity in the left eye was 6/30 correctable by lenses to 6/6 minus 3. The intraocular pressure was 30 mm. of mercury (Schiotz). The patient was not observed again until December 1947. His left eye had then become blurred after he had attended a movie six days previously, and he complained of pain, nausea and inability to get around by himself. Examination revealed the visual acuity to be reduced to counting fingers at 3 inches. The intraocular tension was 89 mm. of mercury (Schiotz). The diameter of the pupil was 4 to 5 mm. slightly irregular and fixed. The cornea was steamy. A diagnosis of acute congestive glaucoma was made. The intraocular tension could not be brought down by the use of miotics. The patient was admitted to the hospital and a basal iridectomy was performed. The tension has continued to remain normal since that time and when last seen in January 1949, the intraocular tension was 23 mm. of mercury (Schiotz). The visual field had returned to satisfactory proportions as shown in the accompanying diagram (fig. 1).

Chronic simple glaucoma is the most common type of glaucoma observed by the ophthalmologist. It is one of the most insidious of diseases and for that reason is often not detected until late in its course. Although it is said to occur more commonly in the Jewish and Negro races, none is immune. It is slightly more prevalent among women than men and occurs generally after the fourth decade of life. It differs from acute congestive glaucoma in that there is no pain, one reason why it is so often overlooked. The cause of this condition is not known although there are many theories. It is usually bilateral, and one eye may be affected before the other eye. One of the early signs is seeing halos

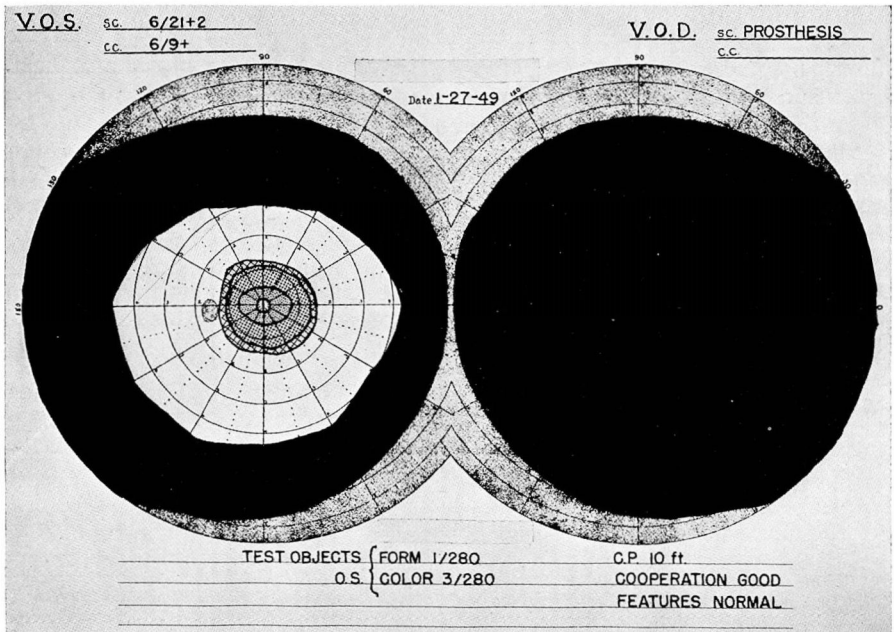


FIG. 1

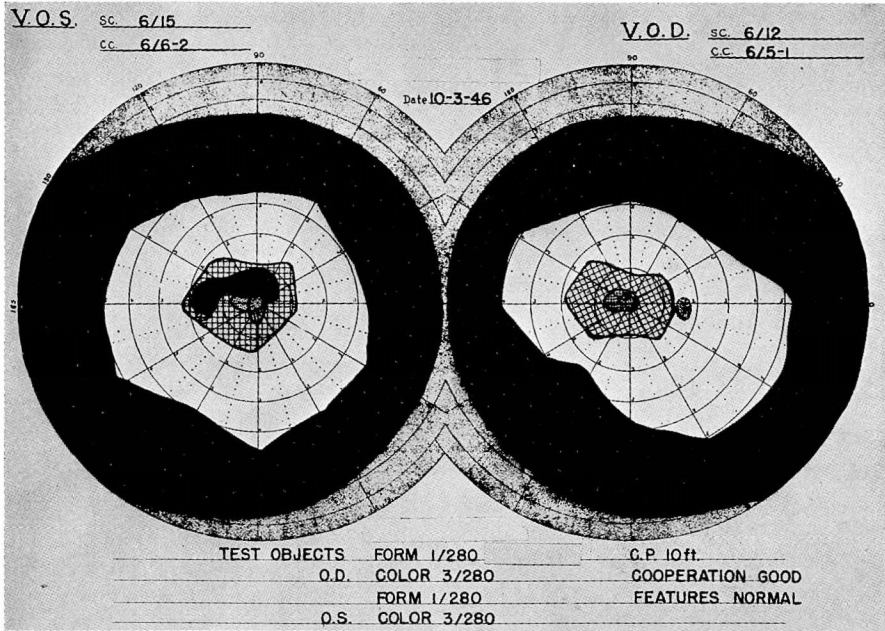


FIG. 2

around lights, but this is often overlooked by the patient. If he is asked concerning "halos," however, he will reply in the affirmative.

Clinically the eye appears relatively normal as far as inflammation is concerned. The cornea and sclera are clear. There is usually a shallow anterior chamber although it may be normal. The pupil may be mildly dilated. The common fundus picture in an early case is that of a clear vitreous and a relatively normal disk. In the later stages, there is cupping of the disk and associated optic atrophy. The vessels can be seen to dip down into the cup as they pass over the edge of the disk, giving them a fish-hook, kinking appearance. The degree of the cupping and the optic atrophy depend upon the time the disease has been present.

The intraocular pressure is elevated, usually somewhere around 40 mm. of mercury, but it may run as high as 60 to 70 mm. of mercury. Central vision is usually maintained extremely late in the disease. Visual fields show characteristic field changes, often the first change being an enlarged blind spot. The enlargement of the blind spot above and below is called Seidel's sign. A continued enlargement of this leads to the Bjerrum scotoma, which increases both above and below the raphe in unequal portions to form the Ronne nasal step. Figs. 2, 3 and 4 show typical visual field changes.

The pressure can often be controlled early in the course of the disease by the use of miotics. Many patients will go for years without loss of vision by their aid and constant use. If the tension cannot be adequately controlled with

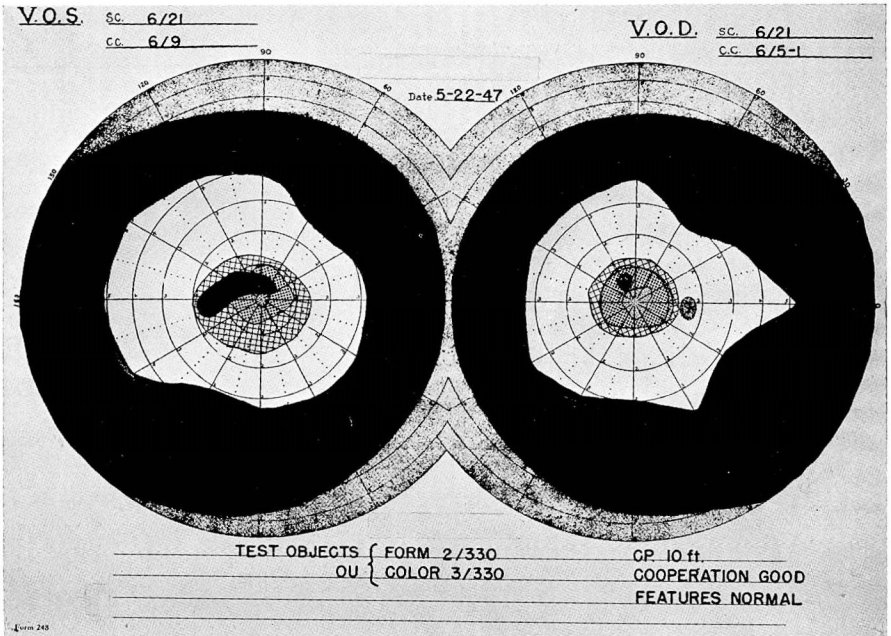


FIG. 3

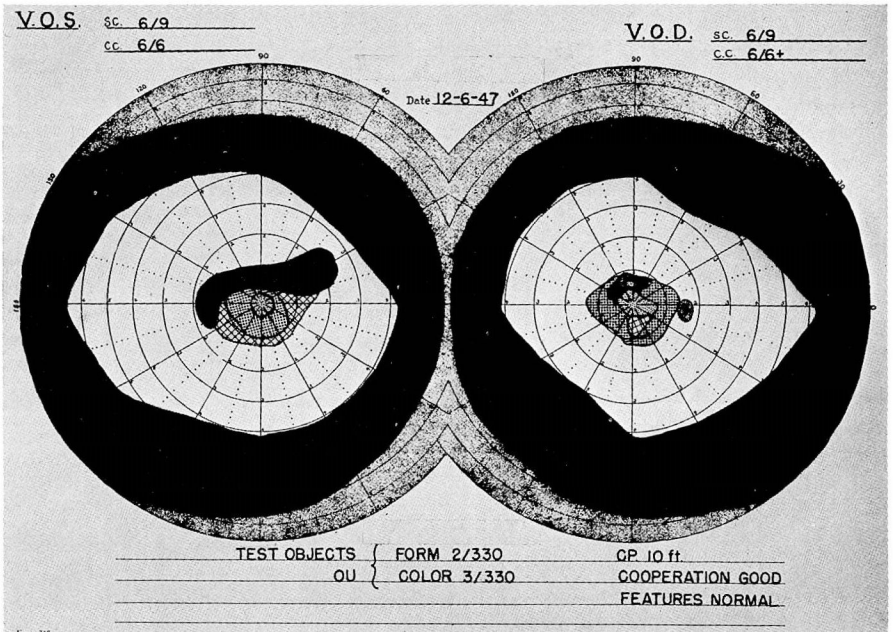


FIG. 4

miotics or there is a loss of visual field even with normal tension readings surgery is indicated. Some form of fistulizing operation such as an Elliott trephine, is the one of choice. These patients should be seen frequently and repeated visual field tests must be made in order to evaluate the therapy that is in use.

Case 2. A 62 year old woman was first observed in 1928. There was no increase in intraocular pressure until October 1946, at which time there was some slight glaucomatous cupping noted. Intraocular tension measured 30 mm. of mercury in each eye. The patient was placed on 1 per cent pilocarpine three times a day and the tension was adequately controlled. The patient was next seen in May 1947. At this time the intraocular pressure measured 35 mm. of mercury in the right eye and 41 mm. of mercury in the left eye. She was advised to resume the use of 1 per cent pilocarpine which she had discontinued. The drops were to be used in the morning and evening and were later increased to three times a day. When last seen in January 1948, the intraocular pressure was 27 mm. of mercury in the right eye and 30 to 35 mm. of mercury in the left eye. The patient has not been examined since that time. The visual fields shown in figs. 2, 3 and 4 demonstrate the typical changes that are seen in chronic simple glaucoma.

Case 3. A 42 year old man was first examined in February 1949. The patient stated that he first saw colored halos around lights six years previously. A diagnosis of glaucoma had been made two months before examination here at which time the patient was placed on 2 per cent pilocarpine by the referring physician. When seen at the Cleveland Clinic his visual acuity was 6/9 in the right eye and 6/12 plus 3 in the left. The intraocular tension measured 89 mm. of mercury each eye (Schiotz) after the patient had refrained from using eye drops for nine hours. He was instructed to use the drops every three hours and return the following morning, at which time the intraocular pressure was reduced to 23 mm. of mercury each eye. Fundus examination did not reveal cupping although there was slight pallor to each optic disk. Visual field findings were not significant except for enlarged blind spots in each eye (fig. 5).

Absolute glaucoma represents the final phase of primary glaucoma which either had been untreated or treated unsuccessfully. The eye is blind and the tension remains constantly elevated. There is pain and the eye is tender to touch. The cornea is usually cloudy, often showing a bullous keratitis. The entire globe is engorged. Generally the fundus cannot be seen. These patients frequently complain of a constant nagging type of pain, and the feeling of a foreign-body sensation in the eye. Enucleation is the only treatment which can be advised. If the patient refuses, one of several procedures may be tried such as basal iridectomy, Elliott trephine or cyclodiathermy.¹

Secondary glaucoma represents an increase in intraocular pressure in which the cause is recognized. Some of the causes which may produce this condition are iridocyclitis, uveitis, dislocated lens, swelling of the lens due to rapidly forming cataract, traumatic cataract, intraocular tumors in late stages, retinal detachment, and thrombosis of the central retinal vein. The clinical picture depends on the exciting cause and, for that reason, any patient with an inflammatory lesion of the eye should have the intraocular pressure measured. As many of these inflammatory lesions are treated with mydriatics, it is always important to constantly check the intraocular pressure. If the pressure rises in these cases, one may have to change to miotics in order to control the pressure. In others surgery is indicated. Paracentesis is often sufficient to control the tension and this procedure may be repeated as often as necessary. If paracentesis does not control the pressure then a basal iridectomy should be

done. In the case of a traumatic cataract, the simple washing out of the lens will often suffice to reduce the tension. The following case is typical.

Case 4. A 38 year old man was first seen at the Cleveland Clinic on February 1, 1949. Two weeks previously a wire had punctured his right eye. The roentgenogram was normal for intraocular foreign body. The patient had been referred to the Clinic because of severe pain in the affected eye. Examination of the right eye revealed an intraocular tension of 89 mm. of mercury (Schiotz). The lens was opaque and the anterior chamber was obliterated. The cornea was steamy. The patient had been given miotics for approximately twelve hours. A linear extraction was performed on February 2, after which the intraocular tension dropped to within normal limits. The pupil was kept dilated with atropine. At the time of discharge from the hospital one week following the removal of the lens, the intraocular pressure measured 14 mm. of mercury (Schiotz). The cornea was clear except for a small scar at the point of injury. This case represents a typical secondary glaucoma due to traumatic cataract.

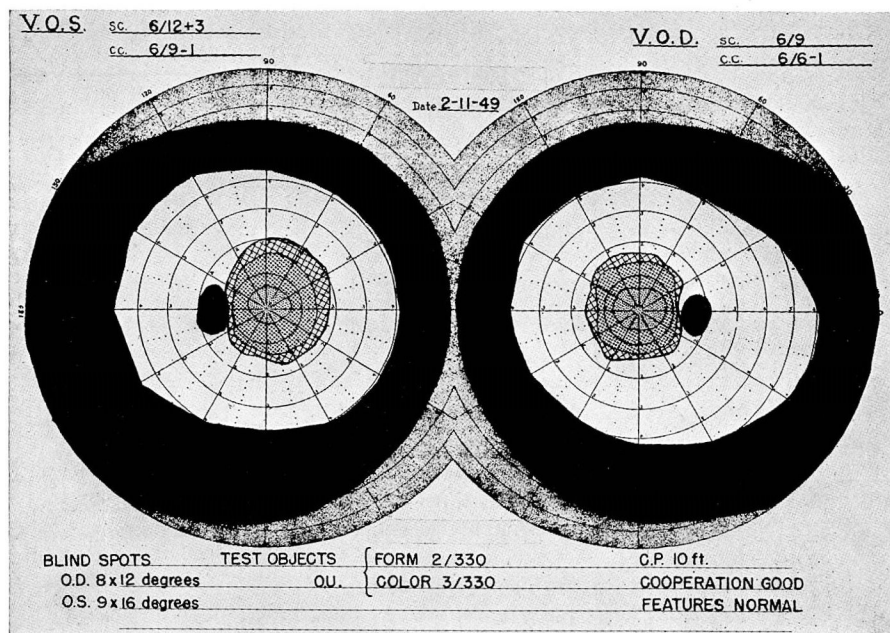


FIG. 5

Congenital glaucoma (buphthalmos, hydrophthalmos) is a condition occurring in infancy in which there is a rise in intraocular pressure. The cornea is larger than normal and as a rule the entire globe is enlarged. The anterior chamber is deep. One can often spot these cases at a glance because of the unusually enlarged appearance of the eye. Pain is uncommon. The condition may be unilateral or bilateral. Cupping of the optic disk may or may not be present, although usually by the time the patient has been seen, there is severe optic atrophy. The tension is elevated often as high as 70 mm. of mercury. In the treatment of these cases, medical therapy is usually of little avail and surgery is required. In the past, trephines and basal iridectomies have been the operation of choice although they have not been too successful. Goniotomy

as described by Barkan² seems to offer new hope. The prognosis in these cases is poor, and the end result is usually blindness; however, every attempt should be made to save as much sight as possible and for as long as possible in order that the child may be educated before becoming blind.

Provocative tests in glaucoma are usually not necessary, but there are times when they seem to be indicated, such as when the pressure is not elevated consistently and one is not sure whether or not he is dealing with glaucoma. The following are three of the commonly used tests:

(1) The dark room test can be carried out in the physician's office. The tension is first measured following which the patient is placed in a dark room for one to two hours. Following this, the tension is again rechecked in as subdued light as possible. If there is glaucoma present, the tension will usually rise anywhere from 5 to 15 mm. of mercury.

(2) The use of fluids may be tried, such as large amounts of coffee or water and the tension measured within one hour following the ingestion of these fluids.

(3) The use of mydriatics has been advocated but has been found to carry a definite risk as one may precipitate an acute attack of glaucoma necessitating immediate surgery.

Miotics when indicated should be used in the weakest strength possible to control the tension. One should start with a weak solution such as 1 per cent pilocarpine, and use it every three to four hours. The stronger miotics such as eserine should not be used in the early cases of glaucoma, and for prolonged cases pilocarpine is preferable to eserine because of the severe pulling sensation that the eserine causes. Some of the newer miotics such as 10 per cent furmethide and D.F.P. (0.1 per cent) may be tried.

Summary

Glaucoma always should be suspected and its presence or absence determined by examination. This is particularly important for the chronic simple type, which is too often overlooked. If a patient reports seeing halos around lights, if there is a history of frequent changes of glasses, or if there is a scratchy sensation in the eye for which no cause can be found, a careful study of visual fields and the measurement of the intraocular tension of the eye by means of a tonometer is essential.

Treatment of glaucoma may be either medical or surgical. All patients should have a complete physical examination and laboratory studies to eliminate any possible associated cause. Once the diagnosis of glaucoma has been established the patient should be informed of his condition and warned that it will require constant attention for the rest of his life. He should be encouraged to use his eyes normally but not to the point of fatigue. When diagnosis is made early and appropriate treatment started promptly most patients with glaucoma can retain reasonably satisfactory use of their eyes for many years.

References

1. Albaugh, C. H., and Dunphy, E. B.: Cyclodiathermy; operation for treatment of glaucoma. *Arch. Ophth.* 27:543-557 (March) 1942.
2. Barkan, O.: Operation for congenital glaucoma. *Am. J. Ophth.* 25:552-568 (May) 1942.