

# MEDIASTINAL TUMORS

DONALD B. EFFLER, M.D.

Department of Thoracic Surgery

UNTIL recent years the mediastinum was considered as a "No Man's Land" insofar as elective surgery was concerned. Except for the extirpation of the substernal goiters from the superior mediastinum, little else was attempted in this region. The collection of mediastinal tumors was left almost entirely to the pathologist as most of these entities were discovered at post-mortem examination. As roentgen examination of the chest increased in popularity, however, the tumors were detected more frequently during life and the opportunity for clinical study became a frequent occurrence. With the development of improved surgical technics in the past decade, the third phase of study and treatment of mediastinal tumors has come into being. Early detection by roentgenography and early exploration of the mediastinum have combined to improve the clinical management and the prognosis of the patient with mediastinal neoplasm. The low morbidity and mortality of exploratory thoracotomy make this operation a safe method of diagnosis and treatment. Prolonged clinical observation is no longer a justifiable procedure in the management of these patients.

"The mediastinum is the space left in the median line of the chest by the non-approximation of the two pleurae (Gray's Anatomy)." Classically, this space is subdivided into four compartments, all of which are surgically accessible (fig. 1). An imaginary plane extending anteriorly from the fourth thoracic vertebra to the articulation between the manubrium and the sternum forms the lower border of the superior mediastinum. This corresponds roughly with upper limits of the pericardium. Below this plane and above the diaphragm are the anterior, middle and posterior mediastinal compartments. If the pericardial sac and its contents are considered the middle mediastinum, the anatomic features of the anterior and posterior spaces may be easily recalled. A simple classification of these four compartments and their normal contents follows.

## Superior Mediastinum

1. Aortic Arch and Great Vessels
2. Innominate Veins and Superior Vena Cava
3. Trachea, Esophagus and Thoracic Duct
4. Phrenic N., Vagi, and L. Recurrent Nerve
5. Thymus

## Posterior Mediastinum

1. Descending Aorta
2. Azygos and Hemiazygos V.
3. Esophagus
4. Thoracic Duct
5. Vagi
6. Sympathetic and Splanchnic N.

## Middle Mediastinum

1. Pericardial Sac and Contents
2. Phrenic Nerves

## Anterior Mediastinum

1. Lymph Glands
2. Fat and Areolar Tissue
3. Thymus

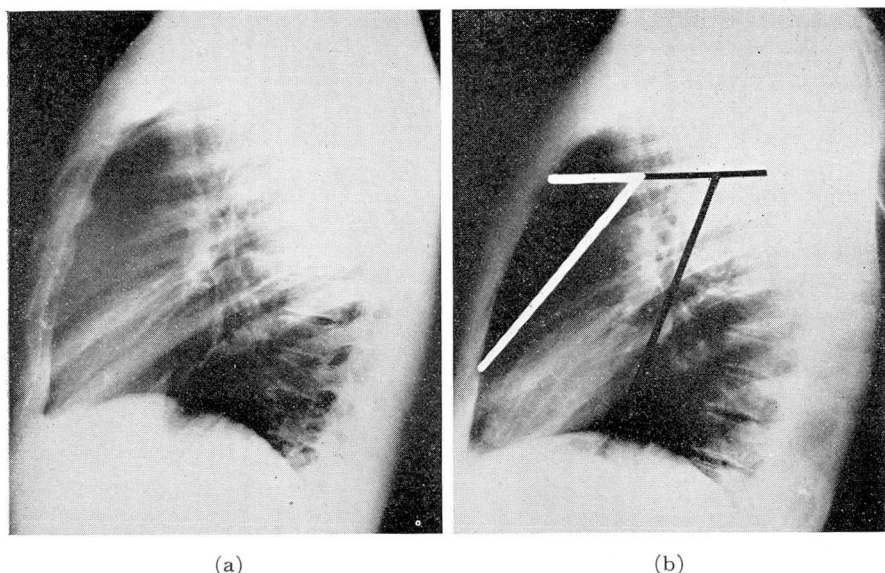


FIG. 1. The mediastinal compartments are best demonstrated radiographically by lateral projection of the chest. (a) Shows a normal adult male thorax; (b) contains the arbitrary boundaries of the mediastinal compartments.

In the study of anatomical charts and in cadaver dissection one may be led to regard the mediastinal space as an inert area whose only importance depends on the structures within its boundaries. Actually this is not true. The motion of the heart plus the ceaseless excursions of respiration contribute to the constant flux in the size and the positions of these compartments. During life the entire mediastinum is subject to numerous vectors of force from the cardiorespiratory mechanism. The importance of these mediastinal mechanics in the dissemination of local infection or malignancy is unknown. Conversely, however, it is not difficult to anticipate the mechanical problems presented by a firm tumor in this area which is encased by the unyielding bony thorax.

Tumors of the mediastinum occur at all ages; however, they are more frequently seen before the sixth decade. There does not seem to be a general pattern of sex incidence. The ratio of benign and malignant features depends on the origin or cell type of the neoplasm and not on its association with the mediastinum. The most striking feature of mediastinal tumors is their tendency to conform to a pattern of location. The recognition of this "geographical" tendency aids in our clinical approach to diagnosis and management. For this reason, many writers have tended to classify these neoplasms by their anatomic site rather than histopathologic type.

**Lymphatic Tumors.** This group includes the lymphomas, lymphosarcoma, Hodgkin's disease, lymphocytoma, etc. These tumors of lymphatic origin occur most commonly in the anterior mediastinum<sup>1</sup> and are probably the most common tumors in this site. They vary considerably in their degree of

malignancy; some are locally invasive and fast-growing whereas occasionally there might be complete encapsulation.<sup>2</sup> In Hodgkin's disease, the mediastinum may be the primary site of the disease although it probably is more often only a part of the general picture.<sup>3</sup> Even Hodgkin's disease may occasionally present an encapsulated mediastinal mass that is amenable to excision; a number of such cases are reported.<sup>4</sup> With the variation manifested by lymphatic neoplasms, one would expect a variation in the symptom complex. Some patients have no subjective symptoms but are discovered on accidental radiologic examination. Others have evidence of weight loss, mediastinal

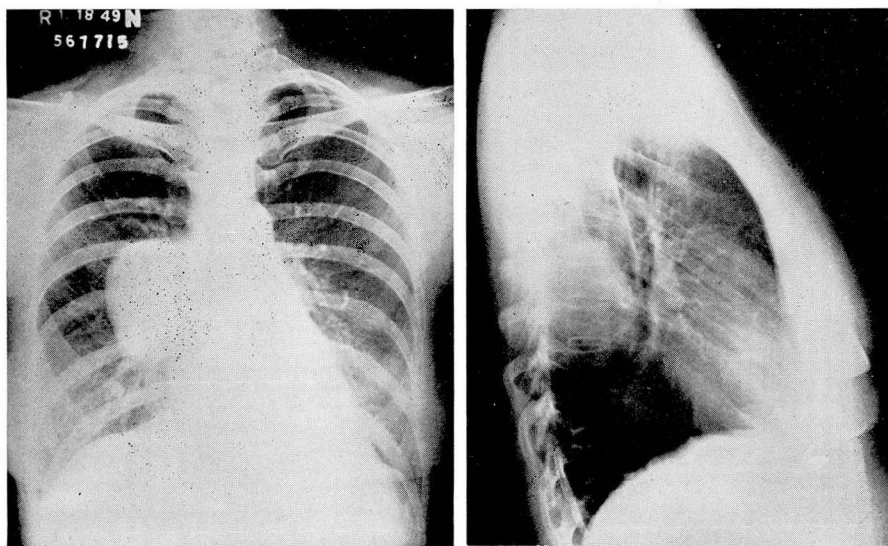


FIG. 2. Case 1. Routine PA and lateral projections demonstrate a well circumscribed mass in the right posterior mediastinum. The patient, a 49 year old white woman, had no symptoms of an intrathoracic tumor. The position and contour of the neoplasm are typical of a neurogenic mediastinal tumor.

compression, hemoptysis and dyspnea. The course of the disease may be rapid or slow; in occasional cases there may be prolonged remissions. The variations in cell type and the tumor characteristics of these lymphatic neoplasms account for the inconsistency of their clinical and roentgenographic appearance.

**Dermoid Cysts and Teratoid Tumors.** These tumors are seen most commonly in the anterior mediastinum and with almost the same incidence as the neoplasms of lymphatic origin.<sup>1</sup> Dermoid cysts are said to have their origin from epidermal tissue whereas the teratomas arise from all three of the germinal layers.<sup>5</sup> Clinically, the teratoma seems to show a much greater incidence of malignancy than the dermoid cyst. The incidence of malignancy in this group of tumors has been variously reported as being between 13 per cent and 40 per cent.<sup>6,7</sup> Whereas there does not appear to be a sex predilection, these tumors

are seen more commonly in youth and rarely after the age of fifty. The treatment of this group of tumors is surgical unless there is malignant invasion of neighboring structures. Roentgen therapy is usually of no value.<sup>6</sup>

**Thymic Tumors.** Tumors of the thymus are almost always found in the anterior mediastinum. These lesions are not common. Interest in thymic neoplasms was stimulated in 1917 by Bell, who reported ten tumors of the thymus in 56 patients who had died of myasthenia gravis.<sup>8</sup> Since that time a number of reports on thymectomy for myasthenia gravis have been published. In the majority of cases hyperplasia of the gland was demonstrated; however, primary

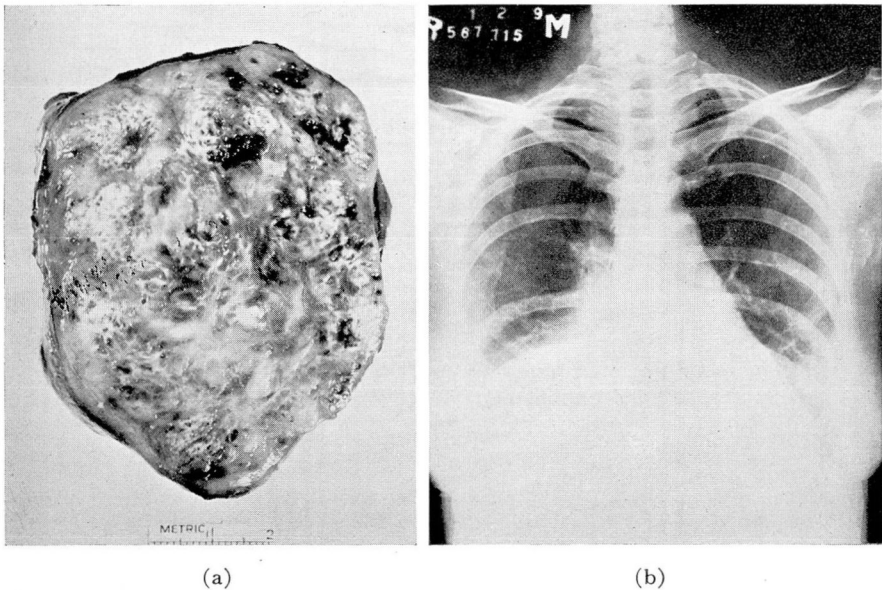


FIG. 3. Case 1. (a) Shows the cut section of tumor demonstrated in figure 2. Microscopic diagnosis is: neurilemmoma, benign; (b) shows a reproduction of the postoperative roentgenogram taken on the sixth postoperative day.

tumors were present in a variable percentage of cases. These tumors are usually benign but a wide variety of malignancy has been described.<sup>9</sup>

Diagnosis of thymic tumors is usually based on the location and roentgen findings. A lateral projection of the chest may be of considerable value in demonstrating the mass.<sup>10</sup>

**Bronchiogenic Cysts.** These cystic masses may be located at any point in relation to the tracheobronchial tree. In the mediastinum, however, the common location appears to be in the superior mediastinum near the tracheal bifurcation. This may appear anteriorly or posteriorly. Bronchiogenic cysts differ greatly in their growth and their microscopic appearance. The tumors, however, are usually round or ovoid in shape and frequently are attached to a bronchus or the trachea by a stalk. The cyst may be solid or may be thin-

walled and contain clear fluid. On microscopic examination the cysts may contain any or all of the tissues normally present in the tracheobronchial tree. Bronchiogenic cysts may produce no symptoms of any kind and may appear to be completely innocuous in character. However, they frequently are subject to secondary infection and produce the clinical picture of a bizarre type of pneumonitis. Blades suggests that so-called carcinoma of the mediastinum may originate in bronchiogenic cysts since these tumors are developmentally and histologically related to the teratoid tumors. The treatment of bronchiogenic cysts is surgical; excision is usually not difficult if no infection is present (figs. 2 and 3).

**Neurogenic Tumors.** The primary nerve tumors arising in the thorax are almost always seen in the posterior mediastinum.<sup>1,11</sup> Their radiographic appearance varies. They may appear to be round or lobulated but the principal characteristic of the tumor is the position in the posterior mediastinum. Usually these neoplasms are asymptomatic; however, they have been reported to produce Horner's syndrome when sympathetic chain involvement is present.<sup>12</sup> Frequently these neoplasms are discovered on an incidental roentgenogram of the chest. Primary nerve tumors may arise from any of the nerve elements found in the mediastinum but most commonly from the sympathetic chain, intercostal nerves and, less commonly, from the vagus or phrenic nerves. Whereas the variety of these primary nerve tumors is great, since they may arise from the various embryonal nerve elements, from the clinical standpoint they may be grouped together under "primary nerve tumors" as their clinical appearance and surgical management are essentially the same regardless of the cell type.

Several large series of primary nerve tumors of the posterior mediastinum have been reported and it is interesting to note that there is a relatively high degree of malignancy seen in these neoplasms. In the series of 105 cases reported by Kent, Blades, Valle and Graham, 37 per cent were found to be malignant in character <sup>11</sup>(figs. 4 and 5).

The suggested treatment of primary nerve tumors of the posterior mediastinum is surgical. In view of the high degree of malignancy in these mediastinal tumors, there seems to be little justification in "watchful waiting" when the patient has not had any localizing symptoms. No benefit can be expected from radiation therapy in the treatment of nerve tumors of the thorax. Unless the nerve tumor has already undergone malignant degeneration, surgical excision is a reasonably safe procedure accompanied by a high rate of cure.

**Pericardial Cysts.** These benign tumors usually arise from the parietal pericardium and appear on roentgen examination to be in the anterior portion of the mediastinum. It is felt that they represent an anomalous development of the pericardium and, as such, are to be classified as "embryonic developmental defects."<sup>13</sup> There does not appear to be any characteristic roentgenologic findings to differentiate them from other types of mediastinal tumors. On gross examination, they usually are thin-walled structures and are adherent to the parietal pericardium. Surgical extirpation appears to be the only manner of establishing the diagnosis of this benign tumor.<sup>4</sup>

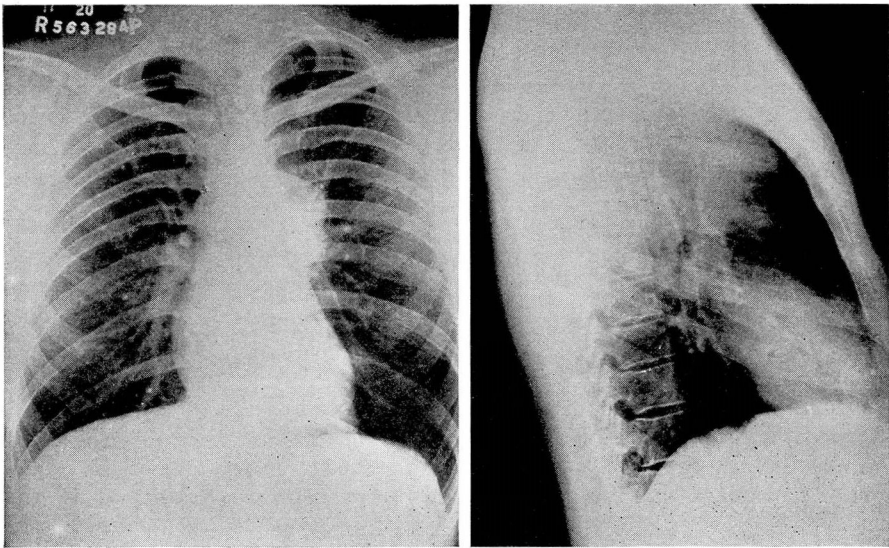


FIG. 4. Routine PA and lateral projections of the thorax demonstrating a mass in the anterior mediastinum in white male patient, aged 30.

**Gastro-enterogenous Cysts.** These cysts represent another of the embryonal defects occurring in the thorax. In such cases the cysts are usually lined with intestinal mucosa that may have the characteristics of stomach or small bowel. It has been suggested that they represent pinching off of buds or diverticula from the foregut<sup>14</sup> and/or intrathoracic vestiges of the omphalomesenteric duct. In addition to appearing characteristically in the posterior mediastinum,<sup>14</sup> they are more frequently seen on the right side than the left. These tumors usually are discovered early in life, frequently in early infancy. Those tumors with gastric mucosa have been reported to contain acid and to produce peptic ulcer.

**Miscellaneous Tumors.** In addition to those neoplasms previously described, there are many types of tumors which have been reported in the mediastinum; however, none of these is common nor are they characteristic in their appearance or position. Such tumors as xanthomas, hemangiomas, lymphangiomas, echinococcal cysts, tuberculomas, parathyroid adenomas and sarcoid occasionally reported as an operative or postmortem finding. Actually, the variety of expected neoplasms which might be present in the mediastinum seems almost unlimited. However, in the broad sense, there appears to be a somewhat orderly pattern in the type and the localization of the mediastinal tumors. Whereas diagnosis cannot be made except by actual tissue biopsy, a fair estimate can be made by the location of the tumor and the roentgen and clinical observations.

### Treatment

Much has been written about the management of various types of mediastinal tumors. There appear to be approximately four major possibilities of treatment: (1) observation; (2) roentgen therapy; (3) chemotherapy; (4) and exploratory thoracotomy.

The dangers of clinical observation of a mediastinal tumor are apparent. Whereas the term "watchful waiting" has been used since the dark ages, there is still a good deal of question as to how long one should wait and just exactly what should be watched. Observation of a mediastinal tumor implies the complete satisfaction of the clinician that he is dealing with a benign lesion. Experience has shown that it is impossible to determine the benignity of a mediastinal tumor on x-ray and clinical observations alone. Hence there seems little reason to delay treatment.

Roentgen therapy in mediastinal tumors has little value except in the tumors of lymphatic origin. There is no question that it is the most beneficial form of therapy in those lymphoid tumors that are bilateral or involve surrounding tissue. Occasionally a lymphatic tumor is well encapsulated and is amenable to resection; this property is usually discovered only at the time of thoracotomy and may be difficult to predict.

The use of roentgen therapy as an aid in diagnosis must also be considered. In good hands, the use of the so-called "test dose irradiation" may be of extreme importance. In those tumors of the anterior mediastinum where lymphatic origin is suspected, a test dose of roentgen therapy may cause the neoplasm to promptly diminish in size. According to Friedman<sup>4</sup> the initial test dose should be approximately 750 r. delivered to the center of the tumor. Approximately one-third of malignant lymphomas will require, however, 1500 r. to affect the tumor. Any decrease in size should be demonstrable within one month's time.

It must be kept in mind by those who would employ radiation therapy without justification that this is not an innocuous form of treatment. The deleterious effects of prolonged, ineffectual radiation therapy cannot be estimated. The length of time involved in a course of roentgen therapy may be sufficient to permit an operable malignant tumor to go beyond the range of operability. The hazards of radiation fibrosis to skin and intrathoracic tissues must also be kept in mind. As a general rule, roentgen therapy in the treatment of mediastinal tumors must be confined to those of suspected lymphatic origin.

The use of chemotherapy in the treatment of mediastinal tumors is of questionable value. The antibiotics have no place except in the unusual cases such as certain types of bronchogenic cysts whose contents undergo secondary infection. Nitrogen mustard is undergoing clinical trial at the present time and, like radiation therapy, its use is being confined to the tumors of lymphatic origin.

It has been stated by Blades<sup>4</sup> that the danger of exploration of the mediastinum is trivial provided qualified anesthetists and surgeons are available and that the patient is in reasonably good general condition. In light of our

present knowledge and technics, it would seem that this statement is easily supported by the present low morbidity and mortality associated with exploration of the thorax. The philosophy of therapy in mediastinal tumors is gradually changing for more frequent use of exploratory thoracotomy following diagnosis of a mediastinal tumor. As the majority of neoplasms in this area are probably benign and asymptomatic, there is still a tendency on the part of many clinicians to procrastinate in the definitive treatment of these tumors. It must be kept in mind, however, that when operation is delayed until the signs and symptoms of chest pain, enlargement of the tumor mass and weight loss have become apparent, the opportunity for successful removal of the lesion will usually have been lost.

That the postoperative morbidity and mortality of exploratory thoracotomy for mediastinal tumors are low is attested by the results of the Army General Hospital as reported by Blades. In a total of 114 exploratory operations to determine the nature of a mediastinal tumor, there were no deaths in the series that could be attributed to the operation. In those patients upon whom only exploration and biopsy were performed, there were no postoperative complications. In the patients who had actual removal of their tumors, there were 3 cases of suppurative pleuritis that healed promptly following adequate drainage. It must be borne in mind that the excellent results were not obtained by one surgeon or a small selected group, but by the combined efforts of five different hospitals with well trained surgeons and anesthetists.

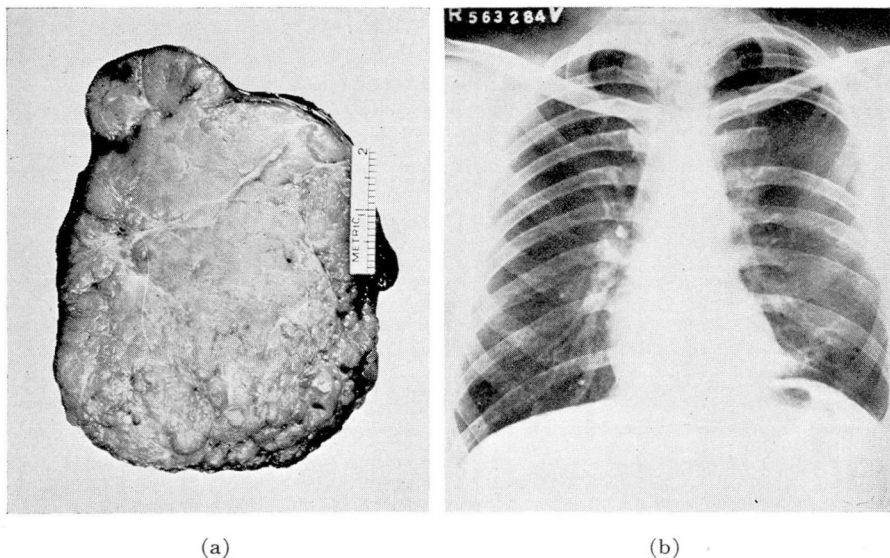


FIG. 5. (a) Cut section of tumor removed surgically. Microscopic examination revealed no evidence of malignancy. Diagnosis: sympathogonioma; (b) postoperative roentgenogram one month after thoracotomy.

### Summary and Conclusions

Undoubtedly, the increased use of roentgen examination of the thorax will uncover an increasing number of cases of mediastinal tumors in the future. The majority of these patients will probably be completely devoid of symptoms, especially in the younger age groups. Whereas the location of the tumor mass will give some clue as to its presumptive diagnosis, exploration of the mediastinum to expose the neoplasm is still the only means available for accurate diagnosis and proper therapy in a large percentage of cases. The hazardous procedure of "watchful waiting" has no place in the clinical management of mediastinal tumors. Surgical intervention in cases of asymptomatic mediastinal tumor before the onset of clinical manifestation is the preferred treatment.

### References

1. Blades, B.: Relative frequency and site of predilection of intrathoracic tumors. *Am J. Surg.* 54:139-148 (Oct.) 1941.
2. Effler, D. B., Blades, B., and Marks, E.: Problem of solitary lung tumors. *Surgery* 24: 917-928 (Dec.) 1948.
3. Heuer, G. J., and Andrus, W. De W.: Surgery of mediastinal tumors. *Am. J. Surg.* 50:146-224 (Oct.) 1940.
4. Blades, B.: Penicillin as adjunct to surgical treatment of acute and chronic empyemas. *Tr. South. S. A. (1944)* 57:288-295, 1945.
5. Hedblom, C. A.: Intrathoracic dermoid cysts and teratomata with report of 6 personal cases and 185 cases collected from literature. *J. Thoracic Surg.* 3:22-49 (Oct.) 1933.
6. Rusby, N. L.: Dermoid cysts and teratomata of mediastinum; review. *J. Thoracic Surg.* 13:169-222 (June) 1944.
7. Harrington, S. W.: Surgical treatment in 16 cases of anterior mediastinal teratoid tumors; one complete report of case. *J. Thoracic Surg.* 7:191-205 (Dec.) 1937.
8. Bell, cited by Thompson, J. V.: Collective review; mediastinal tumors and cysts. *Internat. Abstr. Surg.* 84:195-221, 1947 in *Surg., Gynec. and Obst.* (March) 1947.
9. Andrus, W. De W., and Foot, N. C.: Report of large thymic tumor successfully removed by operation. *J. Thoracic Surg.* 6:648-659 (Aug.) 1937.
10. Blalock, A.: Thymectomy in treatment of myasthenia gravis. *J. Thoracic Surg.* 13:316-339 (Aug.) 1944.
11. Kent, E. M., Blades, B., Valle, A. R., and Graham, E. A.: Intrathoracic neurogenic tumors. *J. Thoracic Surg.* 13:116-161 (April) 1944.
12. Andrus, W. DeW., and Heuer, G. J.: Surgical treatment of tumors of mediastinum. *Surg., Gynec. and Obst.* 63:469-482 (Oct.) 1936.
13. Freedlander, S. O., and Gebauer, P. W.: Disease of aberrant intrathoracic lung tissue. *J. Thoracic Surg.* 8:581-597 (Aug.) 1939.
14. Carlson, H. A.: Congenital cysts of mediastinum; report of 3 cases including gastric cyst. *J. Thoracic Surg.* 12:376-393 (April) 1943.

## APPOINTMENTS

Dr. Eric Bell, Jr., has been appointed to the staff in the Department of Neuropsychiatry. Dr. Bell graduated from Vanderbilt University in 1940. He attended Vanderbilt School of Medicine and received the M.D. degree from that institution in 1943. Following a rotating internship at the City Hospital in Cleveland, Dr. Bell served a Junior Assistant Residency in Neuropsychiatry at the same institution until September, 1944. He then served in the Medical Corp of the U. S. Naval Reserve for two years, returning to the Cleveland Clinic to complete his training.

Dr. Bell has been certified by the American Board of Psychiatry and Neurology in the field of psychiatry and has published several articles in the medical literature. He is a member of the American Psychiatric Association, Cleveland Society of Neurology and Psychiatry, the American Federation for Clinical Research, and several other medical organizations.

---

Mr. Maynard H. Collier has been appointed Administrator of the Cleveland Clinic Hospital. He succeeds Miss Abbie I. Porter, who has retired after 25 years of service. A native of Greater Cleveland, Mr. Collier graduated from Ohio Wesleyan University in 1931. After working in the Credit and Estate Departments of the Cleveland Trust Company, he joined Card, Palmer, and Sibbison, a firm of Cleveland public accountants and tax consultants, and had been associated with the Cleveland Clinic for about a year prior to his appointment as Hospital Administrator.

---

## NOTICE

The camp for diabetic children, Ho-Mita-Koda, situated in a wooded area near Newbury, Ohio, about 25 miles east of Cleveland will be open again this year. This camp, which is operated as a nonprofit institution, is especially designed to serve the needs of both boys and girls between 6 and 16 who have diabetes. A resident physician, nurses, and dietitians are in attendance. Camp activities include swimming, hiking, tennis, archery, and handicrafts. The camp will be open for two periods of one month each, the first period beginning June 26.

The standard fee for the camp is \$150 per period. Inquiries concerning placing diabetic children in this camp may be sent to the Director, Mr. Byron Williams, R. F. D. No. 2, Chagrin Falls, Ohio.