

MEDICAL TREATMENT OF ACUTE TOXIC ULCERATIVE COLITIS

Report of Two Cases

CHARLES H. BROWN, M.D., and JOSEPH H. PERRY, III, M.D.

Department of Gastroenterology

THE treatment of the desperately ill toxic patient with fulminating ulcerative colitis is a medical problem that challenges the ingenuity and knowledge of the practitioner. Not infrequently the patience of the physician is exhausted and he recommends an ileostomy as a "life-saving measure." Bargaen,¹ however, has repeatedly stressed the fact that the surgical mortality in these patients is high, while the medical mortality is relatively low. They are poorly nourished, febrile, in negative nitrogen balance, and are poor surgical risks. Consequently, it would seem that intensive medical treatment would have more to offer these patients than surgery.

At the Cleveland Clinic, surgery is reserved largely for those patients with ulcerative colitis who present complications of the disease. Approximately 13 per cent are operated on here, as compared with 26 per cent at the Lahey Clinic,² and 5.5 per cent at the Mayo Clinic.¹

There is no specific medical treatment for the acutely ill, toxic patient with ulcerative colitis. The principal purpose of treatment is to improve his nutrition and to decrease the inflammation of the colon. The treatment of each patient is different and must be individualized. The results are frequently gratifying with the toxicity of the patient and the inflammation of the colon subsiding, and the nutrition improving. Frequently, the acutely ill, toxic patient improves remarkably and is left with little or no residual.

Recently we had the opportunity of treating 2 patients acutely ill with ulcerative colitis with gratifying results. Several relatively new therapeutic aids employed were apparently beneficial. Because similar treatment may be helpful to other patients seriously ill with the same disease, we present 2 cases.

Case Reports

Case 1. A twelve-year-old boy was admitted to the Cleveland Clinic Hospital on December 26, 1948. He gave a history of having developed lower abdominal colicky pain, diarrhea with purulent serosanguineous stools, low grade fever, and anorexia six weeks prior to admission. *Endamoeba histolytica* had been reported in the stools in an examination performed elsewhere, but the symptoms persisted despite anti-amebic therapy. In addition to these symptoms, two weeks prior to admission the patient had a gradual onset of edema, involving the ankles, buttocks, and scrotum. On admission, he was having twenty serosanguineous purulent stools a day.

On physical examination the patient was too asthenic to be weighed. Moderate pallor was present. Severe edema involved not only the four extremities, but also the scrotum, buttocks, neck, and face. There was a decubitus ulcer 3 cm. in diameter over the sacrum. Temperature ranged up to 100 F.

ULCERATIVE COLITIS

Pertinent laboratory findings are presented in Table 1. The serum albumin of 1.0 Gm. (Tiselius Method) is one of the lowest we have seen and undoubtedly accounted for the pronounced edema. The gamma globulin was 35 per cent above normal, being 1.17 Gm. The differential count on admission: neutrophils—93 per cent, lymphocytes—3 per cent, monocytes—4 per cent. The reticulocyte count was 8.7 per cent. Repeated stool examinations at the Cleveland Clinic were negative for *E. histolytica*.

TABLE 1

Test	Admission	4th hospital day	8th day	15th day
R.B.C.	3.5 million	5.8 million	5.6 million	5.4 million
Hemoglobin	9.0 Gm.	13.4 Gm.	13.4 Gm.	13.5 Gm.
W.B.C.	21,000	38,150	9,000	13,950
Serum albumin (Tiselius)	1.0 Gm.		2.75 Gm.	3.30 Gm.
Serum calcium	8.0 mg.			10.5 mg.

Barium enema examination showed involvement of all portions of the colon with chronic ulcerative colitis, suggesting multiple submucosal ulcerations and surrounding polypoid hyperplasia, and some involvement of the distal 5 to 10 cm. of the terminal ileum (fig. 1).

Proctoscopic examination showed diffuse edema with a slightly granular mucosa and minimal bleeding, but with much blood and pus coming from above.

The clinical progress of the patient was just as dramatic as the remarkable increase in the serum albumin. The temperature subsided to normal so that there was no fever after the seventh hospital day. By the eighth hospital day the generalized edema had completely disappeared. The number of stools decreased from twenty to two per day. The patient was ambulatory and was feeling well when he was discharged from the hospital on the seventeenth day of hospitalization. Five months later, his mother reported that there had been no recurrence of the diarrhea, his appetite was excellent, and he had gained 28 pounds. The treatment employed was as follows:

1. Nutrition. With the generalized edema and remarkably low serum albumin, it was evident that this patient required much food. His diet was increased to the maximum. The average caloric intake the first eight days was 1900 calories, while the second eight days the average intake was 3655 calories daily. Keeton et al³ were able to keep patients in positive nitrogen balance despite surgical procedures that usually resulted in negative nitrogen balance for two weeks by forcing a high protein intake. These patients need a similar high protein intake.

2. Intravenous feedings of 1000 cc. of 6 per cent protein hydrolysate were given daily.

3. Four transfusions of 500 cc. each of whole blood were given the first week.

4. Vitamins. Crude liver extract in 2 cc. doses and 2 cc. of high potency vitamin B complex were given parenterally daily. In addition, he was given large amounts of vitamins A, C, D and K orally.

5. Antispasmodics and sedatives in the form of tincture of belladonna and the barbiturates were prescribed orally in an attempt to relax the colon.

6. Testosterone propionate was given parenterally in a dose of 25 mg. daily. This produced no masculinizing effect in this patient. The purpose of the endocrine therapy was to improve the nitrogen metabolism and to convert him from an obvious negative nitrogen balance to a positive one.

Several investigators⁴ have shown that the administration of testosterone propionate to normal and debilitated persons reduces the urinary nitrogen

excretion and establishes a more positive nitrogen balance. This effect is believed to be one of increased protein anabolism, and was observed in patients with rheumatoid arthritis, nephrosis, uncontrolled diabetes, hyperthyroidism, non-specific ulcerative colitis and regional ileitis, and in normal patients on a starvation diet. The optimal dose appears to be 25 mg. daily from five to twenty-five days. Such a dose if continued for longer than twenty-five days may cause virilism; changes in the voice and hirsutism should be watched for in anyone receiving this therapy. Closure of epiphyses⁵ may also occur, but is an effect of extended treatments (three to nine months or more). Testosterone propionate is an aid in improving the nitrogen metabolism in a desperately ill and debilitated patient.

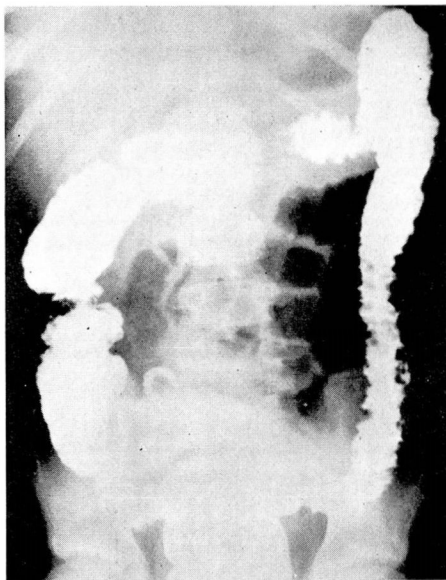


Fig. 1. Barium enema examination in case 1 showing serrations and ulcerations along the descending colon and also involvement of ascending and transverse colon. The terminal ileum is not well shown on the photograph but was thought to be involved fluoroscopically.

7. Antibiotic and Chemotherapy. There is nothing specific about antibiotics in the treatment of these patients. However antibiotics may frequently reduce the secondary invaders and consequently reduce the inflammation of the colon.⁶ From the second to the eighth hospital day, this patient received 0.5 Gm. of streptomycin twice daily, 300,000 units of penicillin twice daily, and 0.5 Gm. of sulfathaladine four times a day. It has been shown that aureomycin is effective against a wider range of bacteria than either streptomycin or penicillin or both together. Consequently, on the eighth hospital day the sulfathaladine, penicillin, and streptomycin were all discontinued, and 1.5 Gm. of aureomycin was given daily. We have been unable to find any reports in

the literature on the effect of aureomycin in ulcerative colitis. While it is difficult to determine the effectiveness of any one drug where so many therapeutic measures are employed, nevertheless with the institution of aureomycin therapy there was a coincidental increase in this patient's appetite and caloric intake.

Case 2. A woman, aged 30, was admitted to the Cleveland Clinic Hospital December 3, 1948. She gave a history of having had diarrhea for five weeks in 1940, a recurrence of the diarrhea with purulent serosanguineous stools in 1942 at which time a resection of the terminal ileum with ileo-transverse-colostomy was performed elsewhere. In July 1948 she had a recurrence of the diarrhea for which she was hospitalized at another hospital and given intensive supportive treatment. However, she failed to respond and an "emergency" ileostomy was performed. Following surgery, the patient continued to fail, having a toxic septic course with daily temperature to 102 F., secondary anemia, and severe loss of weight. She developed undermining of the skin about the ileostomy and a perineal fecal fistula. She was confined to another hospital from July until she was admitted to the Cleveland Clinic Hospital December 3, 1948.

On physical examination, the patient was extremely emaciated and asthenic and was too weak to be weighed. The temperature was 102 F., pulse was 110, weak and thready, and the blood pressure was 80/60. There was a large necrotic area in the abdomen measuring approximately 20 cm. in diameter, its base formed by the external oblique muscle into which emptied a fecal fistula. A left perineal fecal fistula was also present. The patient was placed on the seriously ill list. Her condition was too poor to permit any surgical procedure whatever.

Pertinent laboratory examinations on admission were: Hemoglobin was 9.0 Gm. There were 3,450,000 red blood cells and 6500 white blood cells per cu. mm. Serum albumin (Tislius Method) was 2.44 Gm. Repeated stool examinations were negative for amebae and parasites, but positive for blood and pus.

The progress of this patient after the first week of treatment was striking. She had no further fever, her appetite and caloric intake improved greatly, the anemia was corrected, and the serum proteins became normal. The enormous defect in the abdominal wall gradually granulated in and healed by third intention. The abdominal fecal fistula closed spontaneously on the twenty-fifth day. The perineal fistula also closed spontaneously. The patient was discharged thirty-three days after admission to the hospital. Four months later, she had gained 29 pounds in weight, had only four to five stools a day, and appeared to be in excellent health. The treatment employed was as follows:

1. Nutrition. After the first eight days, this patient had an average caloric intake of 2600 calories per day. A low residue bland diet with over 100 Gm. of protein a day was used.

2. Intravenous feedings of 1,000 cc. of 5 per cent glucose in saline daily for the first three days, and 1,000 cc. of 6 per cent protein hydrolysate daily for the first twenty-one days were given.

3. Five blood transfusions of 500 cc. each were given in the first week of treatment.

4. Vitamins. Crude liver extract (2 cc.) and 2 cc. of high potency vitamin B complex were given parenterally daily, and liberal amounts of A, C, D, and K were given orally.

5. Symptomatic measures to control the diarrhea included antispasmodics (belladonna to tolerance), sedatives (phenobarbital), small amounts of paregoric, and hydrophilic colloids with kaolin and calcium carbonate.

6. Testosterone propionate was given parenterally in a dose of 100 mg. every other day for the first week, and 25 mg. every other day for the next two weeks. No masculinizing effect was observed.

7. Antibiotic and Chemotherapy. The patient was given 2 Gm. of streptomycin, 600,000 units of penicillin daily for the first twelve days. She also received 6 Gm. of sulfathaladine orally each of the thirty-three days she was in the hospital.

8. One of this patient's most difficult problems was the definite undermining of the abdominal wall, extending for a diameter of 20 cm. around the ileostomy. Healing was promoted by two measures. First, a glass cannula was inserted into the ileostomy, and continuous suction was applied, thus diverting the fecal stream away from the defect in the abdominal wall. Second, Pickrell's solution was applied to this area by means of gauze pads every twenty minutes day and night. Stiefel and Kelleher⁷ have already reported on the value of Pickrell's solution in the management of skin excoriations associated with entero-abdominal fistula. Pickrell's solution is a solution of 2.5 per cent sulfadiazine in ethanalamine and distilled water.

Discussion

A brief report is presented of 2 patients critically ill with ulcerative colitis. Both made a dramatic response to intensive treatment. The treatment used in each case is outlined and we feel that all of the measures employed contributed to the recovery of these patients.

Several relatively new therapeutic aids seemed to be of help. Testosterone administered parentally seemed to help the nitrogen metabolism of both patients. Aureomycin appeared to be beneficial in the one patient to whom it was given. The use of a glass cannula to divert the fecal stream and the application of Pickrell's solution was of value in the healing of a large abdominal wall defect in the other patient.

The treatment of a patient seriously ill with acute fulminating ulcerative colitis must be individualized for that patient, and no stereotyped treatment can be set forth for all cases. Other measures, such as oxygen inhalations (Bargen), the use of a Miller-Abbott tube with the tip in the ileum as a "medical ileostomy" as described by Machella and Miller,⁸ the use of sulfasuxidine or sulfathaladine retention enemas,⁹ the continuous intravenous administration of protein hydrolysates, the treatment of allergy and other measures have all proven to be of value in certain cases and are indicated in some patients. These additional measures were unnecessary in the 2 patients presented.

References

1. Bargen, J. A., Lindahl, W. W., Ashburn, F. S. and Pemberton, J. de J.: Ileostomy for chronic ulcerative colitis. *Ann. Int. Med.* 18:43-56 (Jan.) 1943.
2. Cattell, R. B.: Surgical treatment of ulcerative colitis. *Gastroenterology* 10:63-66 (Jan.) 1948.
3. Keeton, R. W. et al: Convalescence: Study in physiological recovery of nitrogen metabolism and liver function. *Ann. Int. Med.* 28:521-552 (March) 1948.

ULCERATIVE COLITIS

4. Kenyon, A. T.: Conferences on bone and wound healing. Josiah Macy, Jr. Foundation. p. 59-69, 18-19, 75-76, 49-53 (Dec.) 1942; p. 128-141, 169-183 (March) 1943; p. 127-137 (June) 1943.
5. McCullagh, E. P. and McGurl, F. J.: Effects of testosterone propionate on epiphyseal closure, sodium and chloride balance and on sperm counts. *Endocrinology* **26**:377-384 (March) 1940.
6. Block, M. and Pollard, H. M.: Chemotherapy and antibiotics in chronic ulcerative colitis. *Gastroenterology* **10**:46-58 (Jan.) 1948.
7. Stiefel, R. A. and Kelleher, G. T.: Pickrell's solution in management of skin excoriations associated with enter-abdominal fistula. *J. Michigan Soc.* **47**:1240 (Nov.) 1948.
8. Machella, T. E. and Miller, T. G.: Treatment of idiopathic ulcerative colitis by means of "medical ileostomy" and orally administered protein hydrolysate-dextri-maltose mixture. *Gastroenterology* **10**:28-45 (Jan.) 1948.
9. Collins, E. N. and Hewlett, J. S.: Succinyl sulfathiazole (sulfasuxidine) in treatment of chronic ulcerative colitis. *Gastroenterology* **7**:549-554 (Nov.) 1946.