

SPINAL EXTRADURAL GRANULOMAS

JOHN R. HANNAN, M.D.* and RICHARD L. MASON, M.D.

Department of Roentgenology

CHRONIC epidural inflammatory tumors are uncommon. Browder and Meyers,¹ in a review of the literature from 1820 to 1937 found 52 cases. In a survey of all epidural compressive lesions at the Hospital of the University of Pennsylvania from 1934 to 1944, Shenkin, Horn and Grant² discovered three lesions of this type. There is no doubt that some cases have been unrecognized or unreported. The literature on epidural granulomas during the past ten years has been sparse and the roentgenologic features have not been stressed. We are reporting observations in two chronic extradural granulomas in order to emphasize the roentgenologic manifestations.

Case Reports

Case 1. A 42-year-old man entered the Cleveland Clinic on May 10, 1945 complaining of rheumatism of two years' duration. His pain began in the left hip and radiated down his left leg to the ankle. Although constant, it was intensified by coughing, sneezing and laughing. Physical examination demonstrated restriction of motion in the back. Routine laboratory studies were normal. A dental examination disclosed no focus of infection. A roentgenographic examination of the lumbar spine indicated moderate osteoarthritis. Fibrositis, rheumatoid arthritis of the spine and disk herniation were tentatively considered as possible diagnoses and thiamin chloride was advised as well as a firm mattress and a course of diathermy and massage. The patient was asked to return in two months if there was no improvement in his condition.

He returned on November 16, 1945 unimproved. A neurologic examination revealed tenderness over L-1. On lumbar puncture between L-2 and L-3 xanthochromic fluid was recovered. Dynamic tests demonstrated partial subarachnoid block. The cerebrospinal fluid contained 200 cells with 90 per cent lymphocytes and the protein was 850 mg. per cent. Progress x-ray films of the lumbar spine showed an area of increased density in the left pedicle and lamina of L-2. A cisternal pantopaque myelogram revealed a partial block at L-2 with a lateral defect in the opaque column, and in addition demonstrated the sclerosis about the pedicle in L-2 (fig. 1). The first preoperative clinical impression was extradural abscess and the second was cord tumor.

On November 21, 1945 a laminectomy was performed under pentothal anesthesia. The lamina of L-2 to the left of the midline was hard and thickened. An extradural grayish hard tumor was found attached to the ligamenta flava. The mass extended along the left side of the spinal canal and compressed underlying nerve roots. The tumor was dissected from the dura with difficulty and the dura was thickened and adherent to cauda equina. When the dura was opened, the operator observed that some of the nerves of the cauda were adherent to each other. The entire mass could not be removed and the dura was left open.

The microscopic examination showed dense, partly hyalinized fibrous connective tissue, in which were present many miliary and larger foci composed of large mononuclear cells. Between these small nodules there was diffuse infiltration with lymphocytes and plasma cells, and occasional polymorphonuclear leukocytes. The diagnosis was, "acute and chronic granulomatous inflammatory tissue, non-specific."

*Now of 10515 Carnegie Avenue.

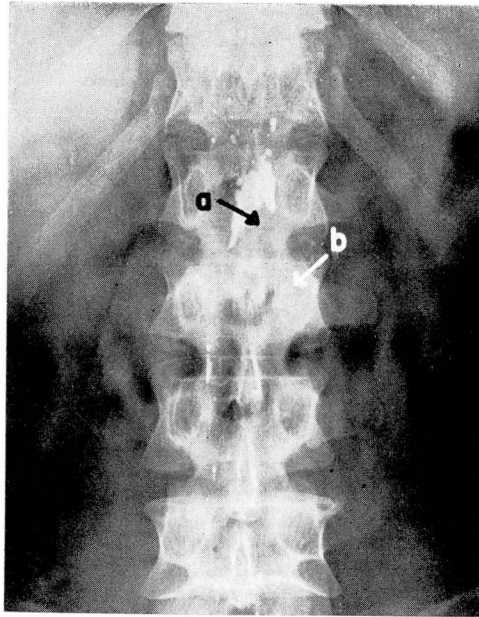


FIG. 1. Case 1. Extradural granuloma. Cisternal myelogram. Partial block opaque media upper border L-2. (a) Lateral defect in opaque column; (b) bone sclerosis in pedicle and lamina of L-2.

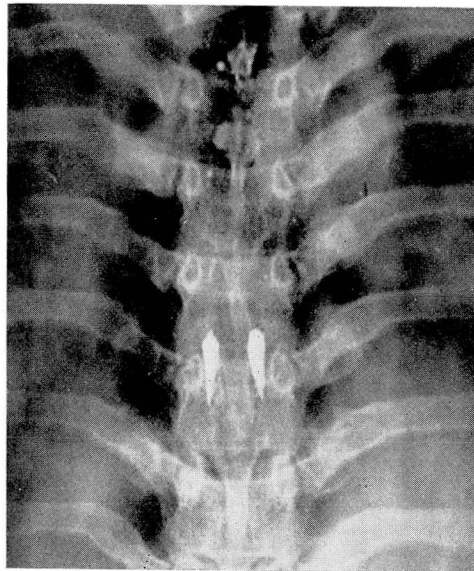


FIG. 2. Case 2. Extradural granuloma. Cisternal myelogram. Partial obstruction upper border of D-7 with central linear defect and lateral displacement of lipiodol.

The patient was given penicillin and his course was uneventful until the twelfth post-operative day when a purulent discharge emitted from the incision and staphylococcus aureus was cultured. This was controlled by irrigations and additional penicillin. From December 15 to 22, 1945, 2200 r. were delivered to the skin over the operative site (200 KV, H.V.L. 1.4 mm. cu., 10 by 20 cm. field, 50 cm. F.S.D.). The patient was discharged on December 15, 1945.

On return visit in January, 1947 he appeared improved, had gained 15 pounds and was working steadily. However, in December, 1947 he returned complaining of a tender, red swelling about 4 cm. in diameter over his right sacroiliac region. Incision and drainage of this abscess were performed on January 3, 1948 and a culture showed staphylococcus albus.

On November 1, 1948 the patient again returned complaining of recurrent pain in the posterior aspect of the left thigh and calf. Another course of roentgen therapy was advised. Between November 2 and November 12, 1948, 2200 r. (200 KV, H.V.L. 1.4 mm. cu. field size 10 by 20 cm., 50 cm. F.S.D.) were delivered to the skin over L-1, L-2 and L-3. The patient was much improved following this course of radiation therapy and has not returned since for observation.

Case 2. On May 12, 1941 a 31-year-old woman came to the Cleveland Clinic stating that she had been conscious of a continuous boring pain in her dorso-lumbar region since November, 1940. The pain radiated, girdle-like, around her chest. Two weeks before admission she first experienced paresthesias in her feet and noted weakness of both legs. There were no sphincter disturbances.

The patient had had syphilis in 1937 which had apparently been adequately treated over a three-year period. Her physical examination was satisfactory except for slight tenderness over D-8, D-9 and D-10. Biceps, triceps, knee and ankle jerks were hyperactive and the abdominal reflexes were absent. The Babinski sign was negative. There was hypesthesia below D-6.

Lumbar puncture between L-4 and L-5 disclosed a partial subarachnoid block. The fluid was clear and no cells were found. Spinal fluid protein was 95 mg. per cent; the Wassermann was negative; the colloidal gold curve was not abnormal. There were no visible cells. Wassermann and Kahn tests on the blood were normal. Roentgenograms of the dorsal spine showed no abnormal changes. Cisternal lipiodol myelogram revealed a partial obstruction at D-7 and a central linear defect with lateral displacement of the oil (fig. 2).

A dorsal laminectomy was done on May 15, 1941 under avertin anesthesia. A sleeve of extremely hard extradural tissue covered the dorsal aspect of the cord. The mass was centered at D-7 and measured 6 cm. in length.

Microscopic examination of the tissue showed chronic granulation tissue and many polymorphonuclear leukocytes and plasma cells. The appearance did not suggest a syphilitic lesion. A culture of the tissue demonstrated staphylococcus albus. Roentgen irradiation was started on May 21 and between May 21 and 23, 425 r. were delivered to the skin over the operative site. (200 KV, H.V.L. 1.4 mm. cu., field size 15 by 20 cm., F.S.D. 50 cm.)

On the ninth postoperative day the wound was reopened because of induration and deep suppuration. Staphylococcus aureus was cultured. Five Gm. of sulfanilamide powder was placed in the wound and a deep pack was inserted. Progress was satisfactory and the patient left the hospital on June 15, 1941. Her hypesthesia had diminished and she had fairly good use of her legs at the time of hospital discharge. She has not returned for examination but on March 14, 1949 her local physician wrote that she has continued in good health.

Discussion

Spinal extradural inflammatory lesions may be either acute epidural abscesses or chronic epidural granulomas. Usually in the acute suppurative lesion the source of infection is readily determined. In many of the chronic granulomas, as in our cases, no source of infection can be detected. It is then most difficult to differentiate clinically a nonspecific granuloma from a cord

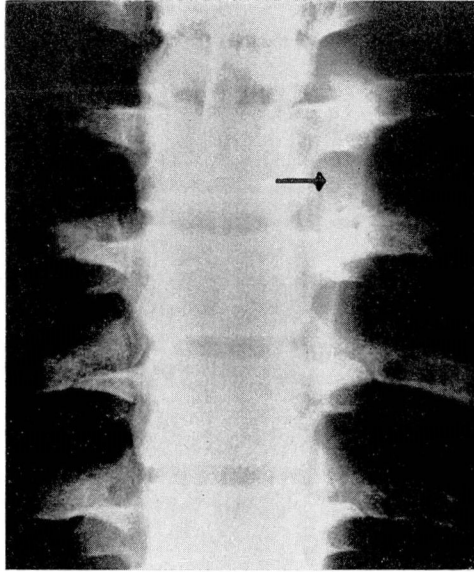


FIG. 3. Nonspecific extradural and paravertebral abscess in boy 16. Developed vague neurologic symptoms three months after acute pharyngitis. Spinal fluid protein 67 mg. per cent. 67 white blood cells in spinal fluid. Arrow indicates localized paravertebral soft tissue bulge.

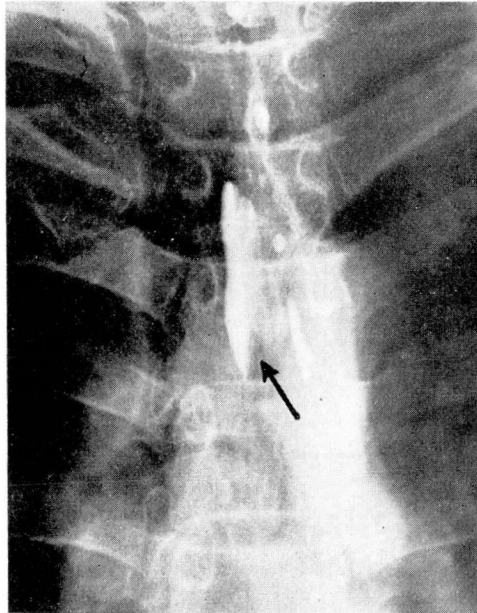


FIG. 4. Extradural Hodgkin's granuloma. Partial block lower border of D-5 with lateral displacement of opaque media. Pattern somewhat similar to myelogram in case 2 (fig. 2).

tumor. All gradations between epidural abscess and granuloma are apt to occur dependent on host resistance and the type and virulence of the organism.

Both specific and nonspecific granulomas have been described. The former are usually tuberculous or syphilitic. Our first patient had a nonspecific lesion. In the case of the second patient there might be a question as to whether the granuloma was syphilitic or nonspecific in character. Because the patient had had adequate antiluetic therapy, because the Wassermann tests on the blood and spinal fluid were negative, and because the microscopic picture did not suggest a syphilitic lesion, we have also classified the granuloma found in the second patient as nonspecific.

Watts and Mixer⁴ claim that extradural inflammatory lesions seldom develop primarily in the epidural space. They frequently develop by hematogenous or lymphogenous extension from a primary focus elsewhere or they may occur through direct extension from infections in contiguous structures. Browder and Meyers¹ believe that in the hematogenous type metastasis is first to a vertebra, producing vertebral osteomyelitis and the infection then extends into the epidural space. Among the reported primary foci are carbuncle, furuncle, cellulitis, dental abscess, pneumonia, osteomyelitis, perirenal abscess, otitis media, pharyngitis, tonsillitis, pyelitis and puerperal sepsis.

Dandy³ and others have emphasized that inflammatory lesions are more frequent in the dorsal spine and that they localize posterolaterally because anteriorly the dura is adherent to the posterior longitudinal spinal ligament.

Pain is nearly always the first symptom of an epidural inflammatory lesion. The time interval from a recognized inflammatory lesion to the first neurologic sign or symptom may be several months to several years. The pain may be limited to a small area along the spine. It is often exaggerated by coughing and sneezing and by jarring movements of the spine. Not infrequently the pain is bilateral and radiates along the spinal nerves. Paralysis is slow to develop and usually incomplete.

The Queckenstedt test usually demonstrates a partial or complete subarachnoid block. The spinal fluid is often xanthochromic and spinal fluid protein is frequently elevated. The elevated spinal fluid lymphocyte count caused by granulomas may be an aid in differentiating these lesions from cord tumors.

The importance of roentgenology in the diagnosis of extradural granulomas has not been stressed. There may be no characteristic changes seen on plain roentgenograms of the spine. However, in our first case there was an area of increased density in the left pedicle and lamina of L-2. This was comparable to the bone sclerosis associated with low grade osteitis elsewhere in the skeletal system. Many would agree that this lends support to the contention of Browder and Meyers¹ that a so-called "metastatic" epidural infection is always a complication of vertebral osteomyelitis. In our case it would be difficult to prove that the vertebral osteitis preceded the epidural granuloma.

Infrequently spinal cord meningiomas produce a somewhat similar hyperostosis in the neural arch or vertebral body. An hemangioma involving a vertebral body and the meninges might be confused with a granuloma clinically,

but an hemangioma produces rather characteristic stippling and parallel striations in the vertebra.

Occasionally an extradural inflammatory lesion causes localized bulging of the paraspinal soft tissues (fig. 3). Neither of our granulomas demonstrated this finding, and we believe that it is more frequent in epidural abscesses.

When there are no localizing neurologic signs and when plain films of the spine are negative, myelography is necessary to establish the level of the lesion. If there is a complete subarachnoid block, the primary object of myelography is to establish the level of obstruction and not necessarily the character of the lesion. Consequently either a cisternal or lumbar subarachnoid injection of 1 or 2 cc. of opaque media will suffice. If there is no block, or if the subarachnoid block is not complete, it is usually better to do a lumbar myelogram using a larger amount (5 cc.) of contrast media to avoid overlooking a small lesion.

Both of our lesions were localized but not specifically diagnosed by cisternal myelograms. In the first case there was a partial block at L-2 with a defect along the left margin of the opaque column. The defect was not unlike that seen in laterally placed subdural neoplasms, but the sclerosis in the pedicle of L-2 suggested that this lesion was probably extradural. In case 2 there was partial obstruction demonstrated at D-7 by myelography. The opaque media was split into two laterally placed columns. We have seen a similar appearance in one extradural Hodgkin's granuloma (fig. 4). Further observation is required before it will be possible to evaluate the importance of a linear defect in the opaque column in the absence of widening of the cord (a sign of intramedullary lesion) in the diagnosis of extradural granulomas.

Summary

Chronic nonspecific epidural granulomas are difficult to diagnose clinically when there is no history of a previous infection. They are easily mistaken for cord tumors. If routine roentgenograms of the spine do not localize the lesion, myelograms should be done to determine the level of the granuloma.

References

1. Browder, J. and Meyers, R.: Infections of spinal epidural space; aspect of vertebral osteomyelitis. *American J. Surg.* 37:4-26 (July) 1937.
2. Shenkin, H. A., Horn R. C. and Grant, F. C.: Lesions of spinal epidural space producing cord compression. *Arch. Surg.* 51:125-146 (Oct.) 1945.
3. Dandy, W. E.: Abscesses and inflammatory tumors in spinal epidural space (so-called pachymeningitis externa). *Arch. Surg.* 13:477-494 (Oct.) 1926.
4. Watts, J., and Mixter, W. J.: Spinal epidural granuloma. *New England J. Med.* 204: 1335-1344 (June) 1931.