

ARTERIAL INFUSION

DONALD E. HALE, M.D.

Department of Anesthesiology

ARTERIAL infusion is the injection of blood, or other fluid, into an artery through a needle or cannula directed toward the heart. The fluid flows in a retrograde direction against the normal arterial current.

Apparently Langendorf,¹ in 1895, was the first to employ this method. He succeeded in re-establishing heart activity in the isolated organ using defibrinated, oxygenated blood. In 1914 Crile² reported the arterial injection of saline solution containing epinephrine together with artificial respiration in the resuscitation of dogs. Seeley³ made the suggestion that the intra-arterial administration of fluids might be preferable to the intravenous route in the treatment of shock. Arterial infusion has been used many times to replace blood after the induction of controlled hypotension.^{4,5,6} It has been employed with success by other workers in this country and abroad.^{7,8,9,10}

The procedure is most clearly indicated for those patients who are in serious cardiovascular collapse as a result of extensive hemorrhage. Such a patient, who, when first seen, is pulseless and who has an extremely low or absent blood

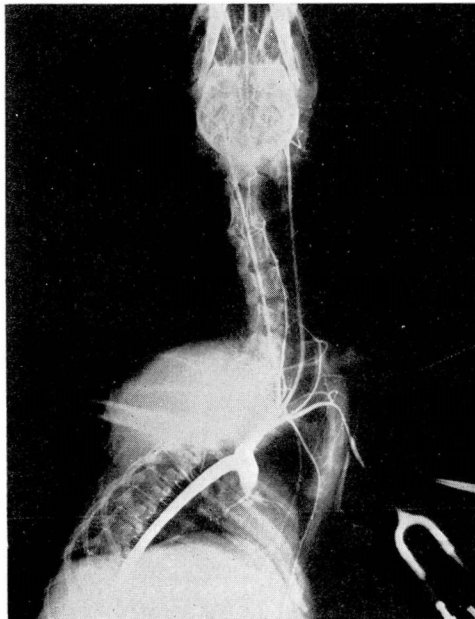


FIG. 1. X-ray of dog showing filling of coronary, carotid and vertebral arteries by injection into brachial artery.

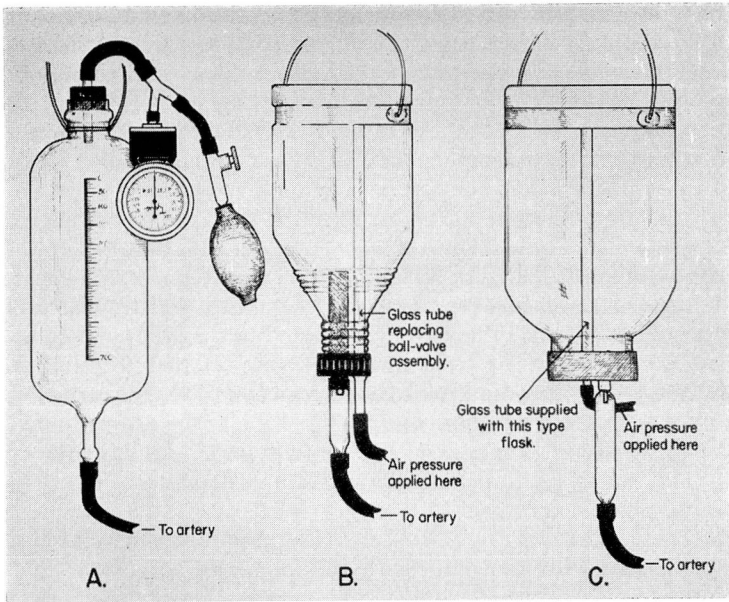


FIG. 2. (a) An open flask for arterial infusion. Measured air pressure is exerted by manometer and bulb. (b) and (c) Adaptations of commercial flasks for giving arterial infusion.

pressure needs a large volume of blood administered intravascularly in order to re-establish circulation. Even more than the need for this large volume of blood, however, is the necessity for an immediate establishment of a reasonable level of pressure in the aorta so that blood may begin to flow at once into the coronary arteries and into the arteries supplying the brain. For this purpose the artery is used simply as a channel to the aorta so that fluid introduced there, added to the fluid already present, builds up a pressure which re-establishes essential circulation. Figure 1 shows graphically that fluid injected intra-arterially can be delivered to the myocardium and brain within a few seconds. The dog shown in the x-ray had been bled until the systolic blood pressure fell to 20 mm. Hg. Thereupon 12 cc. of radio-opaque medium (diodrast 70 per cent) was injected into the left brachial artery. The x-ray taken five seconds later shows satisfactory filling of the coronary, carotid and vertebral arteries.

This represents a quite different use of intravascular injection from the ordinary intravenous administration. In the latter, the vascular system is indeed supplied with fluids, but under circumstances in which the blood stream has become severely slowed or has stopped, intravenous fluid simply dilates the relaxed veins, overfills the right chambers of the heart and pulmonary vessels without actually reaching the aorta, and consequently accomplishes nothing at all. To be sure, in those instances in which the blood stream is still moving, intravenously administered fluids do gain access to the arterial system a few seconds later and this route is therefore satisfactory. Experimental evidence has

shown that cardiac arrest in the absence of ventricular fibrillation may be corrected by the use of intra-arterial infusion of blood alone, which suggests that the method may be of great value used either alone or in conjunction with other methods of cardiac resuscitation.

The apparatus consists of a flask to hold the blood or other fluid, a length of rubber tubing sufficient to reach from the flask to the artery and a cannula or needle to be inserted into the artery. The flask is equipped with a means of supplying measured pressure to the air over the fluid. The apparatus is illustrated in figure 2a. The rubber tubing should be thick-walled and have a fairly small lumen, a satisfactory ratio being 1.5 mm. for the wall and 3.0 mm. for the lumen. The plastic disposable tubings with which the commercial flasks are supplied are not sufficiently well sealed to the adapters on either end to prevent leakage when pressures up to 300 mm. of mercury are employed for forcing the blood into the artery. On this account, it is wise to secure this tubing to the adapters by means of adhesive tape or ligatures, or to replace it with the rubber tubing described. The small mouthed blood bottle commercially available may be adapted to pressure administration of fluids. The ball valve is removed and replaced with a glass tube so that the pressure may be applied or released at will (fig. 2b). The wide mouth commercial bottle may be adapted by inserting a needle with rubber diaphragm (1/16 inch sheet rubber) into the air inlet in the rubber stopper in the neck of the flask (fig. 2c). Air is then pumped into the flask by means of a hand bulb.

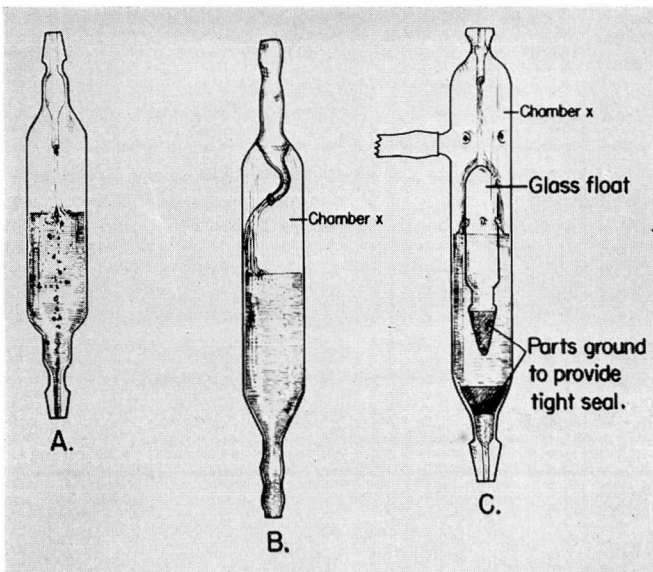


FIG. 3. (a) Murphy drip showing small air bubbles being carried into the fluid by force of stream. (b) A modification with a curved tip to deflect the fluid toward the side, avoiding formation of bubbles. (c) A modification containing glass float which prevents bubble formation and seals lower end of apparatus as last of fluid passes from it.

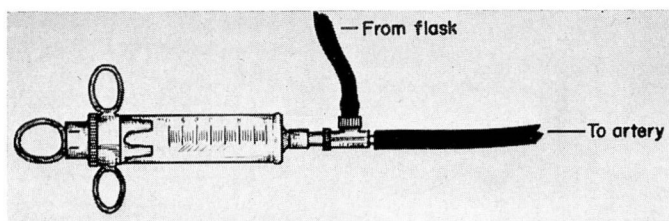


FIG. 4. Ring syringe fitted with two-way valve for giving arterial infusion.

In the earlier apparatus a Murphy drip was placed in the tubing leading from the vessel to the artery so that the movement of fluid could be observed. However, if the fluid is moving at a considerable speed into an artery in which the tension is low, small bubbles of air from the Murphy drip may be picked up by the stream and carried into the artery (fig. 3a). Although small quantities of air are ordinarily well tolerated by the body this is not true if these air emboli are carried to the aorta and gain access to either a coronary artery or a cerebral artery in the presence of extreme hypotension. Because of this the Murphy drip has been discarded or has been replaced with one with a tip bent to the side so that the fluid does not strike against the surface of the meniscus but rather trickles down the side wall (fig. 3b). A most satisfactory modification of the Murphy drip is available in England* and contains a glass float which is ground to fit the bottom of the inside of the device (fig. 3c). Bubbles cannot be carried through as their course is interrupted by the float. Furthermore, when the last of the fluid has passed into the patient's artery a massive air embolism cannot result inasmuch as the float makes a tight seal with the bottom of the Murphy drip. It should be emphasized and reiterated that massive air embolism is a complication which may accompany arterial infusion provided great care is not taken in its prevention.

Another apparatus which affords a safeguard against air embolism following arterial infusion is illustrated in figure 4. It consists of a Lok-control syringe to which is fitted a two-way valve. This allows the syringe to be filled from a reservoir containing blood and to be discharged into the tubing communicating with the artery at a rate which can be determined by the operator. It is a simple matter to replace the syringe with a new one, in the event it becomes sticky, or to place a few drops of citrate solution on the plunger. Another type of syringe may be substituted for the Lok-control, and a three-way stopcock may be used in place of the valve.

The radial artery is the one which is most often used for the injection. Some of the earliest workers used the carotid artery, and the femoral artery has proved serviceable in many cases. In a few instances, in operations during which the thoracic cavity was opened, the needle has been thrust directly into the thoracic aorta and blood under pressure administered by that route.⁸ The radial artery, however, has been found to be most satisfactory because of its ready accessibility, its fairly long, straight, subcutaneous course in the wrist and

*A. Charles King, Ltd., London.

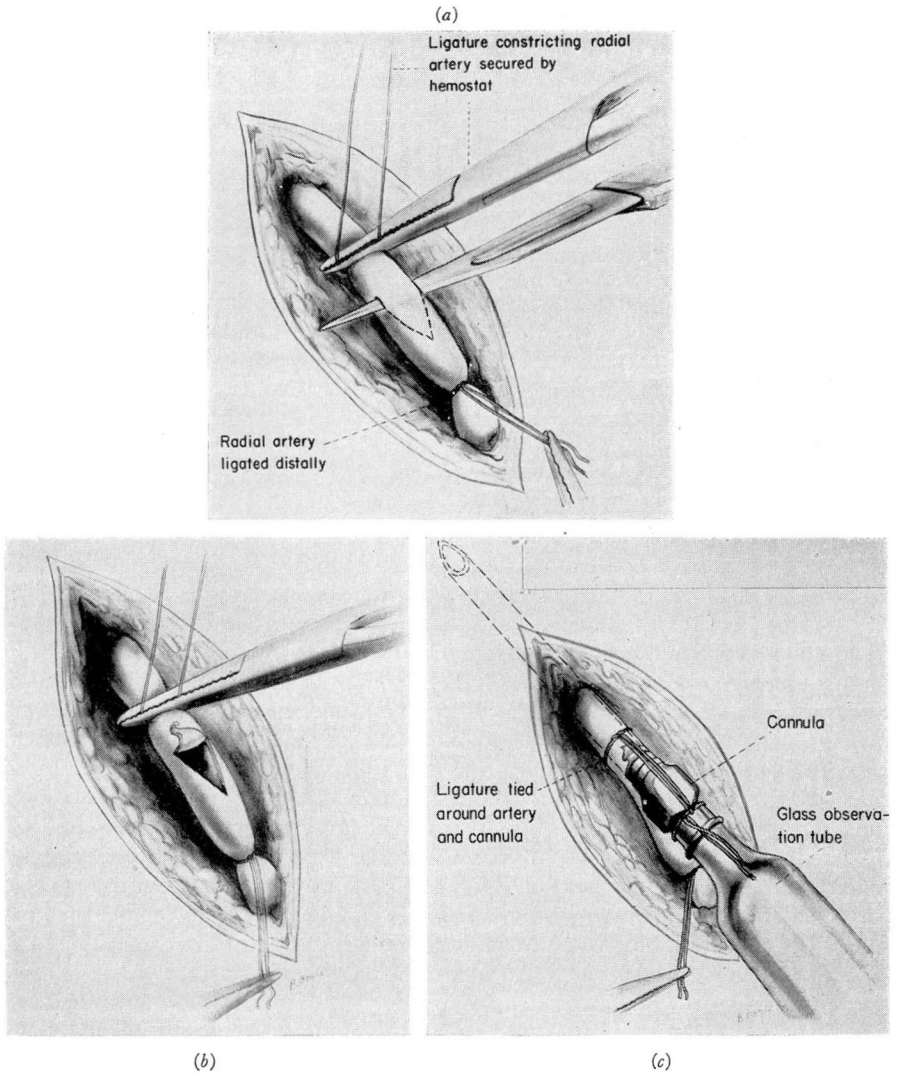


FIG. 5. (a) Artery held between ligatures while being incised. (b) Triangular opening resulting from incision. (c) Cannula secured in artery.

lower forearm, and because its size is sufficient ordinarily to accept a 15 gauge needle or cannula.

Technic

The artery is exposed through a 1.5 cm. longitudinal incision over the radial artery immediately to the ulnar side of the styloid process of the radius. After incising the skin it is necessary to cut the fibers of the fascia before the

artery can be exposed. It is important to free the artery from its associated veins and other tissue. A section of the artery, at least 1 cm. in length, is isolated between two silk ligatures which are secured snugly by means of hemostats without actually tying or clamping the vessel. The artery may then be opened with a scalpel as indicated in figure 5a, by transfixing the artery transversely and withdrawing the scalpel distally and anteriorly thus making a three-cornered opening into which the cannula can be readily inserted (fig. 5b and c). A short, longitudinal incision is also satisfactory but care must be taken not to incise the posterior as well as the anterior wall of the artery. The cannula is inserted and secured in place by tying it with the proximal ligature. Pressure is applied to the fluid in the container. The clamp is removed from the rubber tubing and the blood is allowed to flow into the artery. At the beginning of the procedure the pressure exerted on the fluid may be between 200 and 300 mm. of mercury. The blood pressure is checked at intervals of one minute either by the conventional method on the other arm or by reducing the pressure over the fluid until the flow is arrested as visualized in the Murphy drip. At this point the two pressures, i. e., the pressure registered by the manometer and that in the radial artery, are almost equal provided the level of the fluid in the container is held at the same level as the heart of the patient. When the patient's pressure is found to have reached what is considered a safe level, as for example, 90 mm. of mercury, pressure over the fluid is reduced so that there is a slow, continued flow. Fluid may be given also by the intravenous route during this procedure. It is wise to keep the arterial cannula in place until there is reasonable assurance that the fluid loss has been made up and that the blood pressure has become stabilized. Then the cannula is removed and the artery is either ligated or resutured. Ligation of the artery seldom, if ever, leads to any difficulty because of the rich anastomosis between deep and superficial palmar arterial arches. Indeed, in many subjects it is possible to occlude the radial artery by digital pressure 4 or 5 cm. above the wrist and still to be able to detect a radial pulse in the wrist owing to the presence of this anastomosis. However, it is not a difficult matter to resuture the artery using No. 7-0 silk on a round, atraumatic needle as indicated in figure 6.

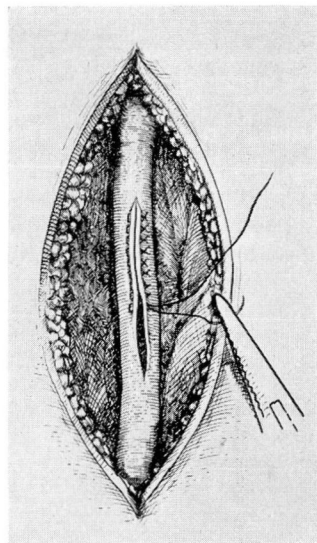


FIG. 6. Suture of artery after removal of cannula, using 7-0 silk on a round atraumatic needle.

If arterial infusion is to be used in the treatment of conditions which most clearly indicate it, namely, severe hemorrhagic hypotension, the equipment must be available on a moment's notice, and the persons who are to apply it must be familiar with the technical details.

Summary

Arterial infusion is a valuable procedure in the treatment of low or absent blood pressure as a result of extensive hemorrhage.

References

1. Langendorf, cited by Birillo, I. A. 7
2. Crile, G. W.: *Anemia and Resuscitation* (New York: D. Appleton and Company, 1914) p. 9.
3. Seeley, S. F., cited by Kohlstaedt, K. G. and Page, I. H.: Hemorrhagic hypotension and its treatment by intra-arterial and intravenous infusion of blood. *Arch. Surg.* **47**:178-191 (Aug.) 1943.
4. Gardner, W. J.: Control of bleeding during operation by induced hypotension. *J.A.M.A.* **132**:572-574 (Nov. 9) 1946.
5. Harris, H. E. and Hale, D. E.: Induced hypotension in control of bleeding during fenestration operation. *Tr. Am. Acad. Ophth.* 90-96 (Nov.-Dec.) 1947.
6. Hale, D. E.: Controlled hypotension by arterial bleeding during operation and anesthesia. *Anesthesiology* **9**:498-505 (Sept.) 1948.
7. Birillo, I. A.: Intra-arterial blood transfusion in shock, agony and cardiac arrest. *Khirurgiya* No. 8, 3-17, 1939.
8. Kay, E. B. and Hacker, V. D.: Treatment of shock by aortic transfusion during thoracic operations. *J.A.M.A.* **134**:604-605 (June 14) 1947.
9. Love, J. G., Courtin, R. F., Anderson, C. D., and Lundy, J. S.: Hypotension induced by arteriotomy, using Page's technic, an aid in surgery; its use in the removal of an epidermoid tumor of the third ventricle: report of case. *Proc. Staff Meet. Mayo Clin.* **23**:153-158 (March 31) 1948.
10. Robertson, R. L., Trinchler, I. H., and Dennis, E. W.: Intra-arterial transfusion. *Surg., Gynec. and Obst.* **87**:695-704 (Dec.) 1948.
11. Glasser, O. and Page, I. H.: Intra-arterial transfusion in treatment of experimental hemorrhagic shock. *Cleveland Clin. Quart.* **14**:121-125 (April) 1947.