

# PRIMARY CLOSURE OF THE POSTERIOR WOUND AFTER COMBINED ABDOMINOPERINEAL RESECTION FOR CARCINOMA OF THE RECTUM

GEORGE CRILE, JR., M.D., and A. H. ROBBETT, M.D.

Department of General Surgery

**D**ESPITE the fact that most carcinomas of the lower sigmoid colon can now be resected safely and effectively with preservation of the rectum, the safest and most effective treatment of cancers located at or below the reflection of the peritoneum remains the combined abdominoperineal resection. This operation includes a wide resection of the rectum, the rectal stalks and part of the levator ani muscles.

Until recently we dealt with the posterior wound by packing it open, following the technic developed by Miles and Jones. Although the patients did well from the standpoint of mortality, early ambulation was hindered by the presence of the large pack. The dressing of the posterior wound required much time, caused considerable discomfort, and often drainage persisted for several months during which the patient required perineal dressings and periodic examinations to insure against the formation of an abscess.

Impressed by reports of others<sup>1,2</sup> who had partially closed the posterior wounds and left them drained only by a Penrose drain, we began in 1947 to close the wounds tightly by the following technic.

## Technic

1. Conventional Miles type of combined abdominoperineal resection following Jones' modifications of technic, but mobilizing as much pelvic peritoneum as possible to help fill the dead space.

2. Complete hemostasis of posterior wound by electrocoagulation or ligation of bleeding points with Number 60 cotton.

3. Partial closure of stumps of levator ani muscles, fascia and fat, under tension if necessary, with 4 interrupted sutures of Number 31 stainless steel wire. This procedure reconstructs the pelvic floor, affords protection against the development of perineal hernias, and helps to obliterate the dead space.

4. Tight closure of the skin with interrupted vertical mattress sutures around a Number 12 soft rubber catheter which is inserted into the dead space and brought out at the most dependent, anterior portion of the wound.

5. Two hundred thousand units of penicillin dissolved in 20 cc. of normal saline is instilled through the catheter and the catheter plugged.

### Postoperative Care

The patients are encouraged to be up and walking on the day of operation and thereafter. Four hundred thousand units of long acting penicillin is administered twice a day for 4 days. The colostomy is opened on the first postoperative day, and diet is increased as tolerated. The urethral catheter is removed on the first postoperative day, and the patient catheterized for urinary residual twice a day until the residual is below 100 cc. on two consecutive occasions.

Three times a day, the catheter in the posterior wound is opened and aspirated of any serum which has collected. A solution of penicillin in saline, 500 units per cc., is then instilled into the catheter, the amount being one half the volume of serum aspirated. Initially 100 to 150 cc. of serum is aspirated, but by the fourth day the residual dead space has so contracted that no more than 20 to 30 cc. of serum can be aspirated. The catheter is then removed and the skin edges about it are pulled together with a suture that was placed at the time of operation. The sutures are not removed until the tenth postoperative day, at which time the wound is well healed and the patient is able to walk and sit with no discomfort.

Most of the patients are able to leave the hospital on the twelfth postoperative day, competent in the care of their colostomies, eating an unrestricted diet, and with their posterior wounds firmly healed and requiring no dressings.

### Results

Since this technic has been adopted, it has been possible to close the posterior wound of all except 2 of 25 consecutive cases of carcinoma of the rectum subjected to combined abdominoperineal resection. One of these patients had an extensive carcinoma of the anal canal with numerous infected fistulous tracts and carcinomatous implants necessitating too wide an excision to permit closure. The other patient, severely diabetic, was operated upon early in the series before we had full confidence in the method of closure, and the posterior wound was packed open.

Of the 23 cases in whom the posterior wound was closed 2 developed serous drainage after the catheter had been withdrawn. A small catheter was replaced, and the patients were discharged with the posterior wound well-healed except for a small sinus tract which healed promptly. A third patient developed a definite infection of the posterior wound 4 days after removal of the catheter, but this was promptly controlled by reinsertion of the catheter and instillation of a solution of penicillin in 10 per cent urethane. The patient was discharged on the twelfth postoperative day with the catheter in place and the cavity holding less than 5 cc. of clear serum. In a fourth case, a patient with hepatic metastases in which a palliative resection had been performed, the posterior wound closure disrupted and was treated in a method similar to cases in which the wound had been packed open from the onset. In a fifth case a superficial stitch abscess occurred but there was no infection of the main cavity. Eighteen of the 23 patients had firm, well-healed, wounds on

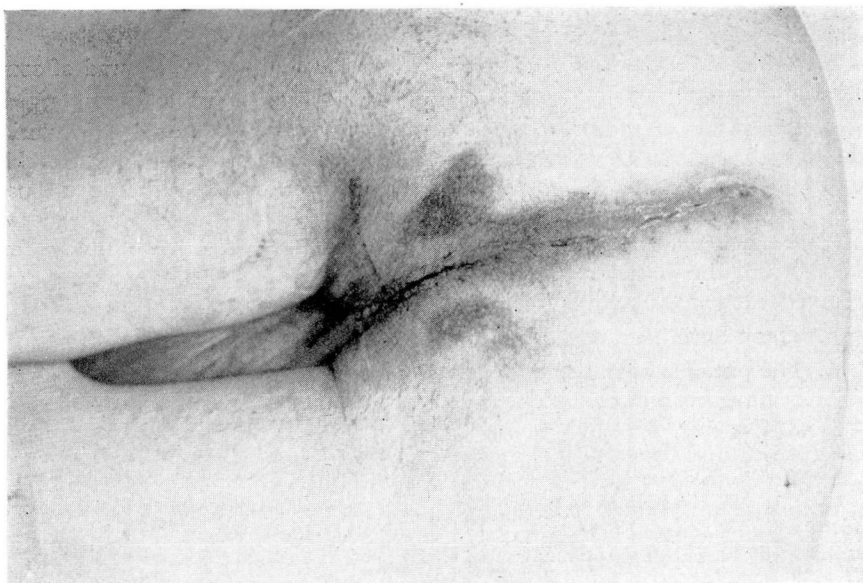


FIGURE. Posterior wound in male patient on tenth postoperative day.

the tenth postoperative day and developed no subsequent complications (figure).

No perineal hernias, weakness, or complications other than those discussed have occurred. There have been no deaths. The average postoperative hospital stay in uncomplicated cases has been twelve days.

**Advantages:**

1. Nursing care is facilitated by early ambulation and reduced necessity for posterior wound dressings.
2. A closed wound free of infection is comfortable and avoids danger of secondary infection, collection of loculi of pus in upper portion of wound, and irritation of pelvic peritoneum by a pack.
3. Convalescence is shortened and care after discharge from the hospital is greatly simplified.
4. Physiologic bowel and bladder function are re-established earlier, as a result of ambulation.
5. Anticoagulants are rarely necessary because patients are ambulatory from the time of operation.
6. Economic rehabilitation is not delayed by a gaping posterior wound.

**Disadvantages:**

Careful hemostasis and closure of the posterior wound increases the operative time by about 30 minutes. The average operating time from initial incision to final sutures is 1 hour and 45 minutes.

### Summary

1. A technic for primary complete closure of the posterior wound of combined abdominoperineal resection of the rectum is presented.

2. In a series of 25 consecutive cases, it was possible to close the posterior wound in 23. (a) In 18 cases the posterior wounds were completely healed in 10 days. (b) In 2 cases, the posterior wound was well healed except for a small sinus which healed promptly. (c) In 1 case the posterior wound disrupted and was allowed to heal by granulation. (d) In 1 case the posterior wound became infected and the catheter was reinserted. (e) In 1 a superficial stitch abscess occurred.

3. There have been no deaths in this series.

4. The patients have been ambulatory from the day of operation, and the majority have been discharged on or before the twelfth postoperative day.

### References

1. Cattell, R. B.: Technic of one-stage abdominoperineal resection (Miles). *S. Clin. North America* p. 801 (June) 1942.
2. Cattell, R. B.: Personal communication.