

## CYSTINURIA AND CYSTINE CALCULI

ARTHUR G. MICHELS, M.D. and WILLIAM J. ENGEL, M.D.

Department of Urology

**C**YSTINURIA, or the presence of abnormally large and consistent amounts of cystine in the urine, is a result of permanent physiologic upset of protein and sulfur metabolism. Cystine is a sulfur-containing amino acid present in protein foods which, in normal metabolism is oxidized principally to sulfate with a smaller amount converted to taurine. In the patient with cystinuria, however, there is failure of intermediary enzyme oxidation of cystine into sulfate and cystine is excreted in the urine in amounts which may be as high as 1 Gm. per liter of urine in a 24 hour period. Normal urine contains only a few mg. (0.8-80 mg. daily) cystine per liter.

This incurable metabolic defect has been recognized for nearly 100 years, but has escaped widespread attention of the medical profession because of the rarity of cystine lithiasis and hence of clinical manifestations. Many patients pass through life without knowledge of their metabolic abnormality. It has been estimated by Eppinger<sup>1</sup> that approximately 2.7 per cent of those with cystinuria develop calculi and subsequent clinical symptoms. An indication of the relative incidence of cystinuria can be gleaned from the findings of Lewis<sup>2</sup> who reported 29 positive cystine urine tests in 11,000 healthy young men and women.

Cystine lithiasis is a rapidly progressive variety of urinary calculosis with a high tendency to recurrence. A few patients, unaccountably, are prone to form calculi in the urinary tract while the majority escape this complication. Experimental clinical and pathologic studies suggest that some lesion of the tubular epithelium of the kidneys initiates calculosis with cystine deposition on a damaged renal tubular epithelium. This occurs in a manner similar to the calculus formation in phosphaturia, oxaluria, and hyperparathyroidism.

The biochemistry of cystine metabolism is confusing, but salient investigations indicate that the amount of cystine excreted by a cystinuric patient is proportional to protein intake. Cystinuria cannot be eliminated completely as small amounts will continue to be excreted even in a state of starvation. The oral administration of cystine does not increase the excretion of cystine which oxidizes to sulfate, as would cystine recovered from the urine if fed to a cystinuric patient. However, methionine and cystine feedings do augment cystine excretion and most experimental studies indicate that cystine in the urine is probably derived from sulfur containing proteins and not from exogenous injection of cystine itself.

An increase in cystine content of urine has been observed<sup>3</sup> in specimens

stored from 12 to 24 hours, due, presumably, to gradual decomposition of an unstable cystine complex which liberates free cystine.

### Familial Occurrence

Cystinuria has a definite hereditary tendency which has been established by numerous investigators. Inasmuch as this tendency is transmitted as a mendelian recessive, it is unusual for all members of a family to show cystinuria. Of those who do show positive cystine urine tests only a few form stones; however; potentiality exists in all people with elevated cystine excretion. Cases 1 and 2 of our series exhibit this familial tendency.

### Age Incidence

Men seem to be affected more frequently than women (a ratio of 65 to 27)<sup>4</sup> with no predilection for any particular age group. Cystine calculosis has been described in an infant of 2 months and in a man of 80 years. Most cases are recognized in younger persons only when the first attack of renal colic appears. All of our patients had their first clinical manifestations during childhood or adolescence.

### Diagnosis of Cystinuria

Cystinuria can be established by either of two simple laboratory procedures. The first consists of examining the concentrated urinary sediment of a cystinuric suspect. The characteristic flat, colorless hexagonal cystine crystals (fig. 1) in the urinary sediment are diagnostic of cystinuria. If the urine is alkaline at the time the specimen is collected, further crystal formation may be observed after acidifying the urine and allowing it to stand several hours before re-examining the concentrated sediment.

The diagnosis may be confirmed accurately and easily by the use of the qualitative cyanide-nitroprusside test of Brand, Harris and Biloon.<sup>5</sup> A modification of this test is used at the Cleveland Clinic. Most standard texts on *clinical laboratory methods or biochemistry include this test or a variation*<sup>6</sup>.

### Clinical Manifestations

The clinical manifestations of cystine lithiasis are similar to those produced by stones of other chemical composition. Recurrent periodic renal or ureteral colic was present in all of our patients having either multiple or single stones. Two of 6 developed unilateral staghorn calculi, a type of renal stone reported both as frequent<sup>7</sup> and unusual.<sup>8</sup> As demonstrated in the 6 case histories, the most serious feature in cystinuria is the almost inevitable recurrence of cystine lithiasis. The patients are disturbed by periodic colic, the passing of stones, and re-formation of calculi after removal.

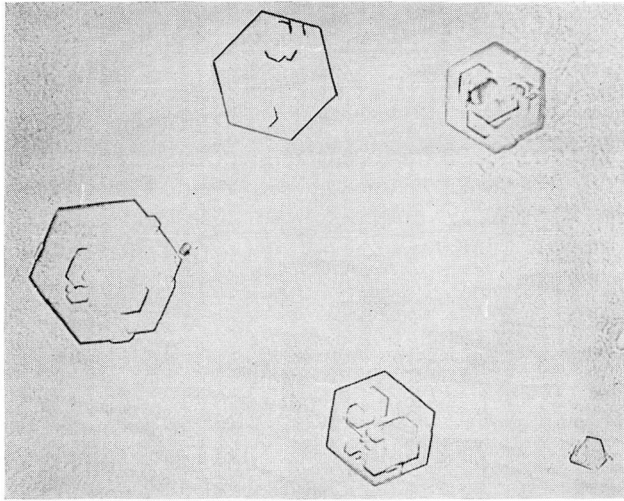


Fig. 1. Characteristic hexagonal cystine crystals present in urinary sediment.

### Roentgenologic Observations

Roentgen examination of the genitourinary tract will show localization of cystine stones if they contain inorganic substances. Pure cystine appears nonopaque,<sup>8</sup> and cystine capsules given orally cannot be visualized. If a stone does not cast a shadow in preliminary films of the abdomen, then stones of cystine, uric acid, or xanthine composition should be suspected.

### Cystine Lithiasis

Cystine lithiasis usually is unilateral and often recurs at the same site. Cystine stones comprise approximately 2 to 4 per cent of all renal calculi. Prien and Frondel<sup>9</sup> found 3.8 per cent cystine in a series of about 700 calculi. Cystine stones usually are found in acid urine and characteristically are oval, smooth, polished, chalky white or light yellow in color, with a soapy appearance. They can be cut like hard yellow soap and may become yellow-green with exposure to air. Microscopically they are composed of multiple hexagonal (fig. 1) crystals within an organic framework colored by yellow pigment.

Cawker<sup>7</sup> believes hemisection of the stone and examination of the nucleus, as well as the outer layer of the stone, may indicate the initiating factor.

### Case Reports

**Case 1.** A youth of 18 came to the Cleveland Clinic with a complaint of intermittent attacks of colicky right flank pain which lasted from 1 to 3 days. One year previously he first experienced severe sharp costovertebral pain radiating around the right flank into the groin and upper right thigh. The pain was accompanied by nausea and vomiting which gradually subsided after hypodermic injections.

He had incurred a second attack 6 months later and subsequent routine urinalysis demonstrated persistent pyuria. An intravenous urogram performed several days before admittance to the Clinic indicated impaired function of the right kidney. There was no history of hematuria or passing of stones.

Physical examination disclosed a well developed, well nourished youth in no apparent distress. No costovertebral tenderness or palpable abdominal masses were evident. Urinalysis disclosed 4 plus albuminuria and 10 to 15 white cells and occasional red blood cells. The blood urea was normal.

A repeat urogram failed to show any right kidney function. A cystoscopy and bilateral retrograde pyelograms demonstrated considerable right hydronephrosis with apparent ureteropelvic obstruction. No opaque calculi were identified. Operation disclosed no ureteropelvic obstruction. The right upper ureter was dilated and when it was followed downwards a sizeable stone was palpated approximately 10 cm. below the ureteropelvic junction obstructing the ureter. A ureterolithotomy was performed and a 10 by 7 by 2 mm. calculus removed which, on laboratory analysis, proved to be composed of cystine.

The postoperative course was uneventful and the patient subsequently was placed on an alkaline ash diet and potassium citrate. The residual dilatation of the right kidney pelvis gradually disappeared and the patient remained asymptomatic. Urine pH has been consistently maintained at 7.5 or higher by the urinary alkalization regime.

**Case 2.** A youth, aged 18, brother of the patient in case 1 was admitted to the Cleveland Clinic Hospital with severe left costovertebral pain of 2 hours' duration. During the previous 6 months he had suffered from recurrent bouts of severe left flank pain which generally began in the left costovertebral angle. Gross hematuria usually followed the onset of the attacks.

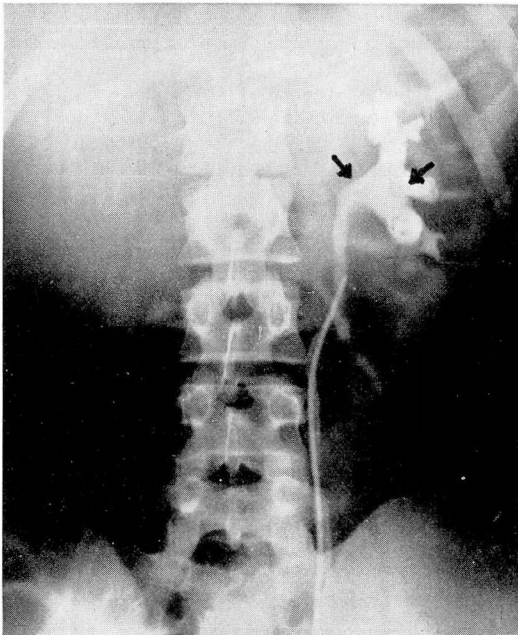


Fig. 2. Arrows indicate multiple filling defects in left kidney pelvis produced by cystine stones, Case 2.

The patient was in acute pain and a generalized abdominal tenderness existed, most pronounced in the left upper quadrant and left costovertebral angle. A flat film of the abdomen and intravenous urogram demonstrated multiple faint shadows in the lower pole of the left kidney and in the region of the left renal pelvis (fig. 2). Two additional shadows in the course of the lower left ureter suggested calculi. The right kidney and ureter were apparently normal.

A contralateral stellate block completely relieved the pain for approximately 2 hours, a method of amelioration as effective as that usually obtained with morphine and atropine. At cystoscopy a catheter passed up the left ureter met resistance near the kidney pelvis, and it was believed ureteral stones had been dislocated by the passage of the catheter. A subsequent pyelogram indicated early hydronephrosis and multiple filling defects in the pelvis and inferior calyx of the left kidney. No shadows were seen in the ureter at this time in contrast to the previous roentgen examination. Urinalysis for cystine was strongly positive.

The patient was placed on a urinary alkalization program with the administration of 2 Gm. of sodium bicarbonate and potassium citrate 4 times a day; in addition, a moderately low cystine and methionine diet replaced his regular diet.

During the following 8 months the urine pH was maintained at 8.0 or above and the patient passed 13 cystine stones (fig. 3) with occasional brief bouts of renal colic. Serial flat films demonstrated a diminishing number of left renal calculi with no evidence of the formation of new stones.

**Case 3.** A white youth, aged 16, came to the Clinic complaining of pain on micturition and passing stones in the urine. A review of his history revealed that he had passed stones in the urine at the age of 2 but had remained asymptomatic until the age of 7 when he developed severe left flank and back pain. A subsequent left nephrectomy was performed for nephrolithiasis; no disease was demonstrated in the right kidney. This youth had experienced 2 attacks of dysuria and gross hematuria during the 3 weeks previous to his first examination, and on one occasion had passed a small stone. Physical examination was essentially negative. Cystine crystals were prevalent in the urine and the cystine test was strongly positive. Initial roentgenogram of the abdomen and intravenous urogram revealed calcification in the course of the lower right ureter, manipulation of which resulted in the removal of two small stones which had been lodged in the midportion. Analysis identified these calculi as cystine stones. The patient was instructed on hospital discharge to maintain an alkaline ash diet and to drink an abundance of water.

During the following 2 years the patient had no recurrence of symptoms and discarded his dietary regime. A few months after returning to an unlimited diet the right costovertebral pain and soreness returned. Roentgen examination at that time demonstrated 3 small calcifications in the course of the right ureter. Inasmuch as no ureteral obstruction was present and kidney function was satisfactory, no operative procedure was considered. The patient was advised once again to follow a low purine alkaline ash diet, maintain a high fluid intake, and alkalize the urine by the use of potassium citrate 2 Gm. 4 times a day.

**Case 4.** A boy, 2½ years of age, was first brought to the Clinic in 1927 having experienced intermittent poorly defined abdominal pain for several months. Roentgen examination disclosed several large calcifications in the bladder region and intravenous urogram confirmed the suspicion of bladder calculi. A suprapubic cystolithotomy was performed and 2 large calculi removed. Two years later a large stone in the left kidney pelvis was removed shortly after its appearance and in 1934 additional new calculi were removed from the right kidney. In 1938 2 calculi, cystine in composition, were removed from the bladder. The patient was then placed on an alkaline ash diet with no recurrence of lithiasis for 5 years.

In 1943 another calculus in the left kidney gradually became smaller on resuming a strict dietary regime. During the following years the patient was unable to follow his diet and developed consequently a staghorn calculus (fig. 4) in the left kidney pelvis with

resultant nonfunction of the left kidney and persistent pyuria. Despite the presence of an urea splitting infection, the stone in the left kidney gradually diminished in size and the urinary infection was controlled with difficulty with prolonged use of sulfanilamides, penicillin, and streptomycin. The patient has been asymptomatic during the past 2 years and the urine is consistently positive for cystine. Urine alkalization has been maintained between pH 7.5 and 8.0 on an alkaline ash diet supplemented at times with alkalizing drugs.

**Case 5.** A married woman, aged 30, was admitted to the Clinic Hospital with severe right flank colic. At the age of 6 she was known to have passed a small stone at micturition and 2 years later a stone was removed from the left renal pelvis. At the age of 21 she had a left nephrectomy for recurrent calculus and nonfunctioning left kidney.

A flat film and intravenous urogram demonstrated an opaque stone in the inferior calyx of the remaining right kidney. The renal colic quickly subsided with symptomatic treatment and since no residual kidney damage was evident the patient was discharged. She returned in 3 weeks with the stone displaced into the kidney pelvis and recurrent renal colic. This calculus was removed surgically and the patient had an uneventful convalescence. The patient's family history revealed that an uncle had bilateral renal calculi, and a nephew renal lithiasis. She was placed immediately on urinary alkalization and an alkaline ash diet.

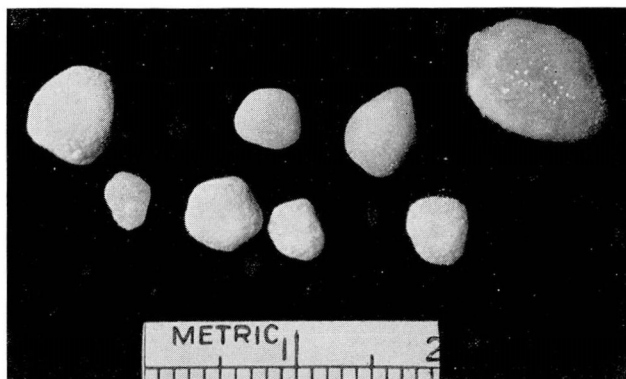


Fig. 3. Smooth cystine stones, Case 2.

The patient remained well for approximately 2 years when she developed recurrent right flank colic. A retrograde pyelogram disclosed a small stone in the lower right ureter with slight right hydronephrosis and hydroureter. This and several other small stones passed easily after a right ureteral meatotomy. The patient returned to an alkaline ash diet and for the past 18 months has been free of urinary complaints.

**Case 6.** A young man, aged 19, was admitted to the Clinic in 1923 complaining of recurrent bouts of left flank pain. Intravenous urogram and flat film of the abdomen revealed a calculus in the right kidney pelvis. A right pelviolithotomy and nephrostomy were performed and a large calculus was removed.

The patient returned to the Clinic in 1926 with recurrent right kidney calculus and a small stone in the left ureter. After left ureteral dilatation the small stone was passed without difficulty. During the next 5 years the right kidney stone became a staghorn calculus filling the pelvis and calices. When he returned to the Clinic a colon bacilli infection was present which could not be controlled medically. A right nephrectomy was performed for calculus pyonephrosis but a stone analysis was not reported.

During the next 15 years the patient passed occasional gravel in the urine but had no

severe pain or colic. In 1946 he experienced severe left lower quadrant pain with radiation into the left groin. Shortly thereafter he passed a stone the size of a pin head from the lower left ureter. After left ureteral dilatation several small stones passed and a renal calculus was removed by pelviolithotomy; a nephrostomy tube was used for drainage for approximately 1 month. Stone analysis was positive for cystine and consequently the patient was placed on an alkaline ash diet and urinary alkalinization. Repeated roentgen examinations of the genito-urinary tract during the last few years have not demonstrated new calculi. The patient has felt well and has been able to follow the outlined diet without difficulty.

### Treatment

Surgery of cystine lithiasis, such as ureterotomy, pelviolithotomy, and cystotomy, is similar to that used in the treatment of any other type of stone. In the absence of surgical indications the treatment should be directed toward prevention of recurrent stone formation. Klemperer and Jacobi<sup>10</sup> were first, in 1914, to advise alkalinization of the urine with 6 to 10 Gm. sodium bicarbonate daily. Subsequently it has been learned that the alkaline urine resulting from this medication merely keeps cystine in solution and does not effect the underlying metabolic disturbance. Crowell<sup>11</sup> first demonstrated disintegration of cystine stones by alkalinization of the urine and repeated alkaline lavage of renal pelves in a case with bilateral renal cystine calculi. Adequate fluid intake is recommended for all patients with this disease, as for any patient with stones, in order to maintain sufficient urinary output to keep the urinary constituents in complete solution.

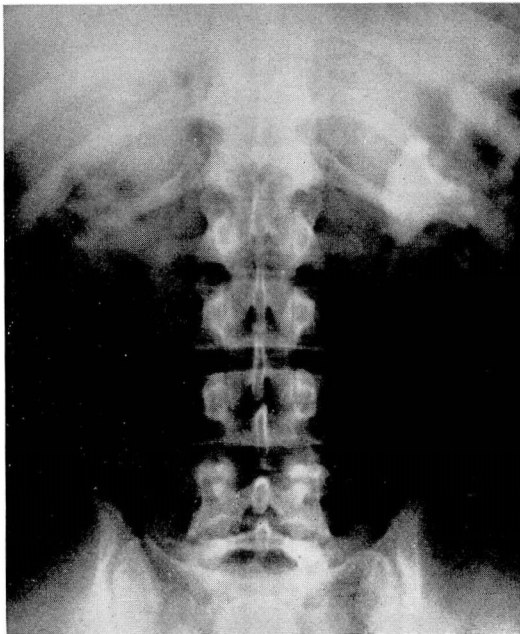


Fig. 4. Staghorn calculus in left kidney pelvis, Case 4.

Alkalinization of the urine can be maintained best by the administration of sodium bicarbonate or potassium citrate in 1 or 2 Gm. doses 4 times a day. As a check on efficiency of alkalinization, the patient should be taught to test the urine by the use of indicator paper such as methyl red or nitrazine in an attempt to maintain a urine pH of 7.0 or higher. Any concomitant urinary disease should be corrected and special attention directed toward the prevention of any form of urinary tract obstruction.

An alkaline ash diet low in sulfur protein is valuable in maintaining alkaline urine as well as in diminishing the concentration of cystine urinary output per unit volume. Some patients can be treated successfully on the diet without recurrence of stones.

Case 4 is an example in which the patient's inability to follow the prescribed alkaline diet may have precipitated the formation of recurrent calculi. Previously on a strict dietary and alkalinization regime, a staghorn renal calculus had decreased in size as indicated by roentgen examination. Serial urograms in case 2 demonstrated an apparent decrease in size of pelvic stones. The patient passed numerous stones (fig. 3) without apparent ureteral obstruction while on urinary alkalinization. There is no evidence that new calculi have been formed subsequently.

None of the 6 patients in this group have shown ill effects from long urinary alkalinization. When a patient was maintained on a strict alkaline ash diet and adequate urinary alkalinization, the formation of new cystine calculi was absorbed and a high urine pH (7.5+) sustained. Progress roentgen examinations demonstrated objective evidence of diminishing stone size.

Periodic ureteral dilatation and renal pelvis lavage with weak alkali calculi after operative removal; repeated instrumentation is often undesirable. Solutions have been used successfully<sup>11</sup> to increase stone dissolution. We have preferred to rely upon adequate alkalinization to prevent recurrent calculi.

### Summary

Cystinuria is a rare, incurable metabolic defect in which abnormally large amounts of cystine are excreted in the urine. Diagnosis is established by the discovery of characteristic flat hexagonal crystals in the urinary sediment or by a positive cystine urine test.

Clinical attention usually is prompted by symptoms of urinary calculi. This variety of urinary calculosis has a high tendency to recurrence. A program of urinary alkalinization and an alkaline ash diet low in sulfur proteins has been effective in reducing the incidence of stone recurrence in the 6 cases studied.

### References

1. Eppinger, H.: Arch f. exp. Path. u Pharm. **97-98:51**, 1923.
2. Lewis, H. B.: Cystinuria, review of some recent investigations. Yale J. Biol. and Med. **4:437** (March) 1932.



3. Andrews, J. C., and Randall, A.: Sulfur metabolism in cystinuria. *J. Clin. Investigation* 14:517 (Sept.) 1935.
4. Kretschmer, H. L.: Cystinuria and cystine stones; further observation of this condition with report of 3 new cases. *J. Urol.* 30:403 (Oct.) 1933.
5. Brand, E., Harris, M. M., and Biloon, S.: Cystinuria; excretion of cystine complex which decomposes in urine with liberation of free cystine. *J. Biol. Chem.* 86:315 (March) 1930.
6. Todd, J. C., Sanford, A. H., and Stilwell, G. G.: *Clinical Diagnosis by Laboratory Methods; A Working Manual of Clinical Pathology*, ed. 11. Philadelphia, W. B. Saunders Company, 1948.
7. Cawker, C. A.: Treatment of cystine calculi. *Canad. M. A. J.* 55:19 (July) 1946.
8. Keyser, L. D., and Smith, C. D.: Clinical management of cystine lithiasis. *J. Urol.* 62:807 (Dec.) 1949.
9. Prien, E. L., and Frondel, C.: Studies in urolithiasis; composition of urinary calculi. *J. Urol.* 57:949 (June) 1947.
10. Klemperer and Jacobi: Cited by Cawker.<sup>7</sup>
11. Crowell, A. J.: Cystin nephrolithiasis. *Surg., Gynec. and Obst.* 38:87 (Jan.) 1924.