

SKIN GRAFTS IN MASTOID CAVITIES

HAROLD E. HARRIS, M.D. and F. C. MEADOWS, M.D.*

Department of Otolaryngology

ALTHOUGH skin grafting of mastoid cavities is not a new procedure, it is only in recent years that improvement in technic and the advent of antibiotics have made it practical and widely accepted. Previously, failures were numerous and the end result disappointing. This paper is presented (1) to demonstrate a relatively simple technic which gives uniformly good results, (2) to illustrate the reduction in postoperative care, and (3) to determine the ultimate effect of skin grafts placed inside the mastoid cavity.

Skin grafting in mastoid defects was first advocated in this country by Mosher¹ in 1911 (although it had been used as early as 1889 in Germany, where the procedure was both praised and condemned). Mosher's original technic advocated dissection of a crescent-shaped piece of skin from the posterior surface of the auricle, leaving it attached at the upper border of the postauricular sulcus. This pedicle flap, about $\frac{1}{8}$ inch wide, was laid into the defect and the postauricular incision closed with drains inserted through the wound. In 1917 he revised this technic, using a free skin transplant applied to a paraffin basket mold made at the time of surgery. The mold and paraffin basket were removed on the fourth postoperative day through the external meatus.

In 1918, Kahn² recommended Thiersch grafts which he applied through the meatus after closure of the postauricular wound. He created an ingenious instrument for this purpose. Later,³ he advocated a pedicle flap which he dissected from the posterior border of the postauricular incision.

Many variations of Mosher's original paraffin basket mold have been used. De River⁴ and Israel⁵ advocated the use of dental compound molded to fit the cavity. The graft was placed on the mold and fixed in the cavity. The incision was left open until the fourth postoperative day, at which time the mold was removed and the incision closed under local anesthesia. Daggett and Bateman⁶ and Cuning⁷ advocated secondary grafting on the fourteenth day, after granulation tissue had formed, believing that the graft was more likely to "take". Ziegleman⁸ utilized the periosteum from the mastoid area, superimposed a graft thereon, and placed these within the defect. Shambaugh⁹ advocated the paraffin mold in modified as well as radical mastoidectomy.

With the advent of endaural mastoid surgery, the problem of grafting was simplified because of better exposure of the mastoid cavity, and because this approach permits easy removal of the packing postoperatively. In addition, the use of the dental bur is considered to facilitate greatly the number of "takes"

*Former Fellow. Now located in Danville, Pennsylvania.

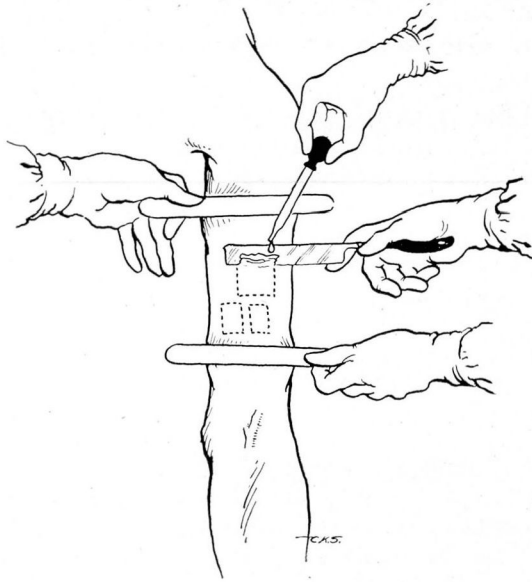


FIG. 1. Technic employed in removal of skin; saline projected onto razor blade to float grafts.

in grafting; this is probably due to the fact that the bur, revolving at a fast rate, gradually erodes the bone, leaving the extremely small vessels patent. On the other hand, the relatively slow moving, blunt chisel compresses the bone, thereby occluding the vessels.

Since 1946 we have employed skin grafts in more than 150 cases, including both radical mastoid and fenestration operations. In none of these has a graft failed to survive and the tendency to extensive granulation has been greatly reduced. Postoperative care has been shortened to an average of 4 to 6 weeks, as contrasted with 2 to 4 months prior to the use of this method. The shortened convalescence, and the decrease in the number of dressings needed during hospitalization, have saved many hours' work.

The following technic is now employed routinely. Ear cultures are made and, in the case of chronic otitis media, appropriate antibiotic therapy is begun prior to surgery. Patients about to undergo a radical mastoidectomy receive penicillin and dihydrostreptomycin or aureomycin. Fenestration cases are treated with penicillin, which is begun 24 hours prior to surgery. Antibiotic therapy is continued throughout the period of hospitalization.

At surgery, a split-thickness graft is taken from the anterior surface of the arm. Split-thickness is used for two reasons: (1) the most active reproduction of cells in the skin, as evidenced by the many mitotic figures, occurs in the lowest part of the prickle cell layer, and (2) the nourishment of the meager blood supply beneath the graft would not reach this layer in sufficient amount if full-thickness grafts were used.¹⁰ The arm most frequently chosen is the

one corresponding to the ear to be operated upon because the opposite arm is used by the anesthesiologist for the blood pressure cuff and intravenous medication. The skin of the arm is cleansed with ether and alcohol. Strict aseptic technic is followed throughout.

An assistant holds the skin taut above and below the donor area with sterile tongue depressors, thereby affording a flat surface from which the skin is obtained with a sharp straight razor. A stream of saline is projected from above onto the razor blade to float the graft (fig. 1). The razor is used in preference to a dermatome because no glue-like substances are necessary which might interfere with growth of the graft, because thinner skin can be obtained, because the method is more rapid, and grafts of accurate and uniform thickness can be secured. The removed skin is placed in normal saline at room temperature and saved for grafting. The donor site is covered with fine mesh gauze impregnated with scarlet red ointment and a pressure dressing is applied. This dressing is left undisturbed for 6 days, then is replaced by vaseline gauze for 2 to 3 days; no further dressing is needed. No scar is formed if these rules are adhered to. Caution should be exercised in the depth of the graft. Deep grafts will cause scarring and keloid formation on the arm.

After the skin is removed, a radical endaural mastoidectomy is performed and, in the case of fenestrations, the fenestrum is created and the skin flap from the external canal thinned with iridectomy scissors. The mastoid cavity should be prepared without ridges and depressions if possible, and the bone roughened with the dental bur. (This will have been accomplished if burs are used for the endaural surgery.)

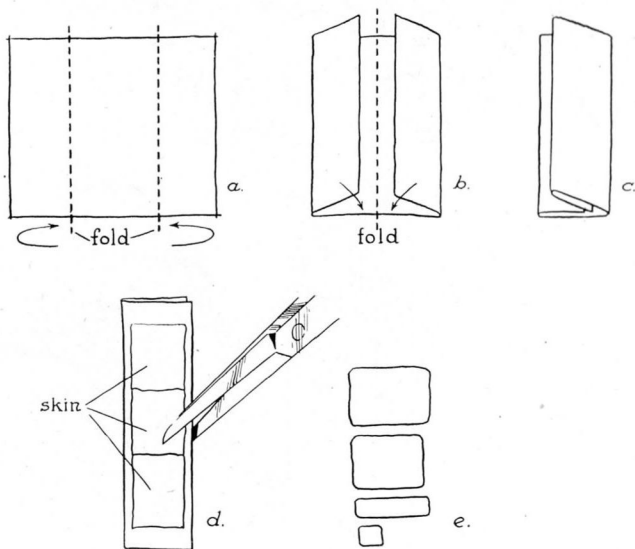


FIG. 2. Method of preparing parresinized gauze and skin grafts for application.

The Application and Placement of the Grafts

The previously obtained skin is placed, raw surface outward, on parresinized gauze mesh which has been folded so that no cut edges are visible. Both skin and gauze are cut into strips which will fit the cavity. They are flooded with saline with a medicine dropper to prevent curling and contraction of the skin (fig. 2). These pieces of skin, with the gauze approximated, are placed in the cavity so that their edges are as close together as possible without overlapping (fig. 3a). A small flat instrument such as a periosteal elevator is used to work the grafts into apposition where they are secured by placing small pieces of vaseline-impregnated gauze (rolled in sulfathiazole crystals) tightly against the graft-bearing mesh. The entire cavity is grafted in this manner, 5 to 6 pieces of skin approximately 1 by 2 cm. being used. It is then firmly packed with the grafts in proper position, the vaseline gauze pledgets of varying sizes fitting the contour of the cavity (fig. 3b). This prevents over-pressure on some areas. A pressure dressing is applied externally.

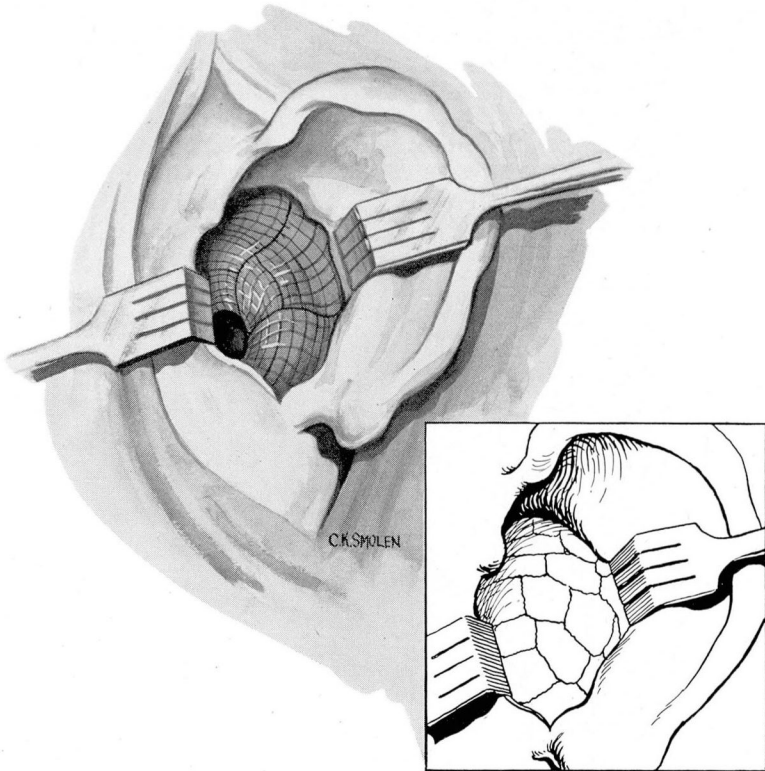


FIG. 3. (a) Schema of endaural mastoid cavity showing grafts in place. (b) Cavity packed with vaseline gauze pledgets.

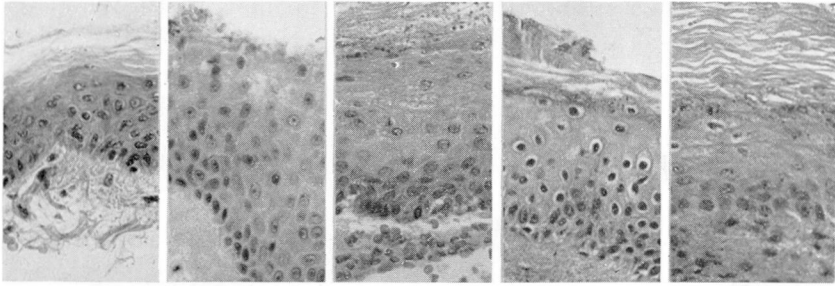


Fig. 4. Photomicrographs of epidermis at surgery and at 2, 4, 6 and 8 weeks.

The packing inside the cavity is not disturbed until the sixth postoperative day, although the outer dressing is changed every second day to prevent pressure necrosis of the external ear. Care should be taken to pad the external ear sufficiently.

When the packing is removed from the mastoid cavity, the grafts have become adherent and the cavity is almost completely epithelialized. The packing must be removed with care else the not-too-firmly-attached, more external grafts may be loosened. The center pledgets are always removed first and the peripheral supporting pledgets and parresinized gauze last. Subsequent postoperative care consists of cleaning out small amounts of serous drainage every 2 days for 1 week. The cavities are completely healed in 3 to 4 weeks and no further treatment is needed. It is rarely necessary to pack the cavity postoperatively. In no case has there been uncontrollable granulation, or failure to obtain a dry ear. It is exceedingly important that the patient obtain a dry ear whether a radical mastoidectomy or a fenestration has been performed.

Since the inception of skin grafting there has been discussion as to the ultimate effect of split-thickness skin transplants in mastoid cavities. Most observers believe that the skin actually remains viable and grows, while a minority feels that the graft acts merely as a depressor of granulation tissue and that the epithelialization occurs from the flap and sides by extension.

In an effort to clarify this point, biopsies were taken from the center of known graft areas at 2, 4, 6, and 8 weeks and the tissue analyzed by the Department of Pathology. In every case the report was "viable skin" (fig. 4), as evidenced by the normal staining reaction, mitoses in the prickle cell layer, and the presence of all layers of epidermis. Therefore, we must conclude that there is ample evidence to prove that the grafts do remain viable and do grow.

It is interesting to note that sensation returned to the skin at the end of 4 weeks. The first biopsy at 2 weeks was absolutely painless, at 4 weeks slightly painful, at 6 weeks moderately painful, and at 8 weeks the pain was fairly severe. This is in accordance with the findings of McCarroll¹¹ on the return of sensation in transplanted skin.

Another interesting observation was that at 2 weeks the biopsy was relatively bloodless, but with each succeeding biopsy more blood was encoun-

tered.¹² Such evidence indicates that the sympathetic regeneration occurs along the vessels, since bleeding in each case was controlled by adrenalin pack.

Summary

1. A practical method of grafting mastoid cavities is outlined.
2. Convalescent time and postoperative care have been greatly reduced.
3. Evidence is presented which substantiates the belief that split-thickness grafts survive and grow when transplanted into mastoid cavities.
4. A dry ear can be obtained with a greater degree of certainty than by any previous method we have attempted.

References

1. Mosher, H. P.: Method of filling excavated mastoid with flap from back of ear. *Laryngoscope* 21:1158, 1911.
2. Kahn, A.: Outlines of a new instrument to be used in skin grafting in radical mastoid cavity. *Laryngoscope* 28:875, 1918.
3. Idem: New method for skin grafting mastoid cavity, new method for closing off eustachian tube at its tympanic end in radical mastoid operation. *Laryngoscope* 37:889 (Dec.) 1927.
4. De River, J. P.: Use of dental stent in skin grafts of middle ear and mastoid cavities. *M. J. and Rec.* 122:63, 1927.
5. Israel, J.: Application of dental molding compound for maintenance of skin grafts in middle ear and mastoid cavities. *Illinois M. J.* 67:175 (Feb.) 1935.
6. Daggett, W. I. and Bateman, G. H.: Secondary Thiersch grafting of radical mastoid cavity through meatus. *J. Laryng. and Otol.* 49:169 (March) 1934.
7. Cuning, D. S.: Series of cases of radical mastoidectomy with skin graft. *Laryngoscope* 45:776 (Oct.) 1935.
8. Ziegleman, E. F.: Use of periosteal flap with skin graft in radical mastoid surgery. *Laryngoscope* 42:170 (March) 1932.
9. Shambaugh, G. E., Jr.: Primary skin graft in modified (Bondy) radical mastoidectomy for preservation of hearing in cases of genuine cholesteatoma, *Arch. Otolaryng.* 23:222. (Feb.) 1936.
10. Grace, E. J.: Importance of prickly cell layer in skin grafting. *Am. J. Surgery* 32:498 (June) 1936.
11. McCarroll, H. R.: Regeneration of sensation in transplanted skin. *Ann. Surg.* 108:309 (Aug.) 1938.
12. Kredel, F. E. and Phemister, D. B.: Recovery of sympathetic nerve function in skin transplants. *Arch. Neurol. and Psychiat.* 42:403 (Sept.) 1939.