

HAMARTOMA OF PERICARDIUM — LYMPHATIC TYPE

Case Report

EDWIN R. FISHER, M.D.,
Department of Pathology

CHARLES S. BALLINGER, M.D. and DONALD B. EFFLER, M.D.
Department of Thoracic Surgery

PRIMARY neoplasms of the pericardium are rare. Yater¹ in a comprehensive review of tumors of the heart and pericardium in 1931 mentioned lipoma, sarcoma and mesothelial tumors as the types encountered. He also presented a cyst “probably of a lymphatic vessel” in the pericardial fat at the apex of the heart. Histologic evidence, however, was lacking in his report. Keller and Callender² have described a large neurofibroma attached to the pericardium apparently originating from the phrenic nerve. A teratoma lying within the pericardial cavity and adherent to the pulmonary artery was noted by Joel³ in 1890. More recently Greenberg and Angrist⁴ have reported 2 cases demonstrating hemangiomas of the pericardium. One of these was of the benign cavernous type; the other a progressive, invasive angio-endothelioma.

Although lymphangiomas of the mediastinum are considered rare, reports of their occurrence have appeared occasionally in the literature. Stout,⁵ in commenting upon N. C. Foot’s discussion of mediastinal tumors, emphasizes the occurrences of such lesions. Although many of the cases of mediastinal lymphangiomas reported have demonstrated attachment to the pericardium as well as to other thoracic structures, their exact origin has not been established and histologic descriptions have been lacking in some instances. In the foreign literature in 1929, Eliaschewitsch⁶ reported an example of cystic lymphangioma arising on the posterior surface of the pericardium. Lenkeit,⁷ a year previously, observed a cyst on the anterior surface of the heart but its true nature was not discussed.

Analogous cases of cystic lymphangioma arising anatomically from the pericardium and proved by histologic examination to have been of lymphatic origin have not been recorded in the American literature which we have reviewed. The symptoms produced by this lesion, in addition to its fundamental rarity, suggest the individuality of the subsequent report.

Case Report

A 38-year-old white woman was referred to the Cleveland Clinic Hospital for treatment with a roentgenographic diagnosis of tumor of the lower lobe of the left lung. The

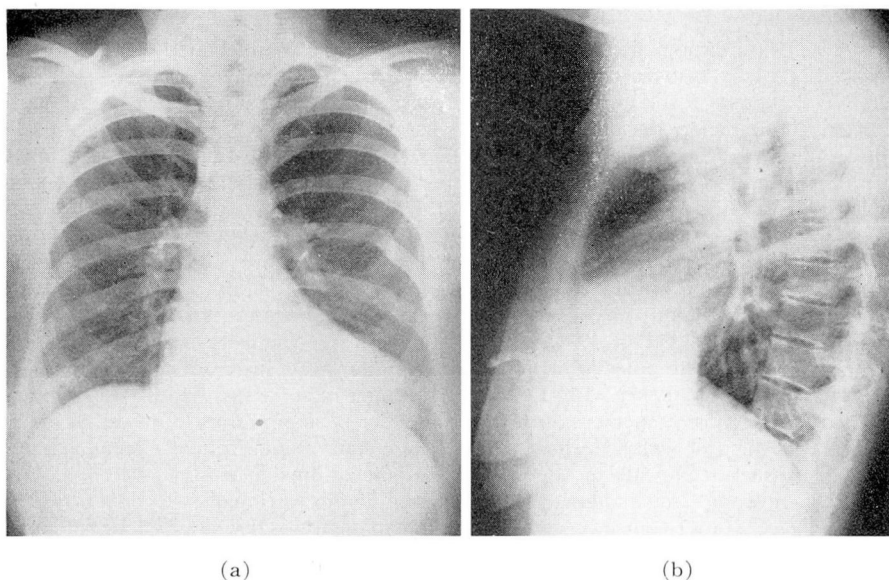


FIG. 1. (a and b) Anteroposterior and lateral roentgenograms of chest demonstrating mediastinal lesion.

patient however, denied all symptoms referable to the respiratory system. Her only complaint was that, on change of position, she experienced a sensation of "something flopping about in the left chest." This condition had been present for approximately 10 years.

The past medical history revealed extensive rib fractures of the left thorax which had been experienced 17 years previously.

The patient was well nourished and appeared neither acutely nor chronically ill. Examination of the heart and lungs was negative. The blood pressure was 130/90. The pulse rate was 80 per minute and regular. No mediastinal shift was demonstrable. Examination was otherwise normal.

A laboratory examination revealed 4,210,000 red blood cells, 11.0 Gm. hemoglobin and 6150 white cells with a normal differential count. The urinalysis and blood chemistry determinations disclosed no abnormalities.

Roentgenologic studies of the chest (fig. 1 a and b) revealed an area of increased density approximately 10 cm. in diameter just above the left diaphragm, posterior to the sternum and adjacent to the left cardiac border. Healed fractures of the fifth, sixth, seventh and eighth ribs on the left side were evident.

Because of the previous history of trauma a hernia through the morgagnian foramen was considered as the most likely diagnosis, although the incidence of bronchiogenic or pericardial cyst could not be excluded.

A left exploratory thoracotomy was performed. A cystic structure was encountered adjacent to the left border of the pericardium; at one point, however, in direct contact with the pericardial sac. The cyst was somewhat mobile due to this pedicle. After sharp and blunt dissection the pedicle was ligated and divided and the cyst easily removed *in toto*.

Pathology

Gross examination (fig. 2). The specimen consisted of a trilobulated cystic structure measuring 12 by 12 by 6 cm. A thin, glistening, richly vascular capsule was evident. Several tags of fat tissue were noted on the outer surface. The largest section measured 6.0 cm. in diameter, the others 5 and 3 cm. On rupturing, a clear, watery, slightly amber fluid was released from the compartments. The wall at its thickest part measured 3 mm. In the wall of the largest locule were three flat, dense, white areas. The lining of each compartment was finely nodular and reddish-yellow in color.

Microscopic examination (fig. 3 a and b). Sections revealed the cystic structures to be lined by endothelial cells. Smooth muscle, as well as dense collagenous connective tissue, was apparent within the walls. Beneath the endothelium were collections of lymphocytes which, in some areas, formed nodular aggregates. An occasional endothelial-lined blood-filled space was detected in the wall. Small spaces with peripheral lymphocytes were also noted. The outer surface of the cystic structure consisted of loose areolar and adipose tissues with a moderate number of congested capillaries. Sections stained by the Masson method verified the presence of smooth muscle as well as dense collagen in the cyst walls. Verhoeff elastic tissue stain demonstrated a scant amount of elastic tissue in the walls of a few of the endothelial-lined spaces.

A diagnosis of vascular hamartoma, lymphatic type, was made.

The postoperative course was uneventful. The patient was discharged 1 week following operation and has remained asymptomatic and in good health for the 2 subsequent months.

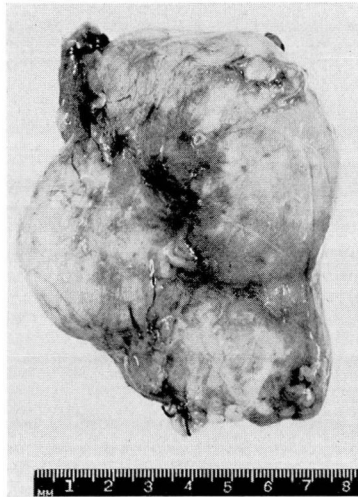


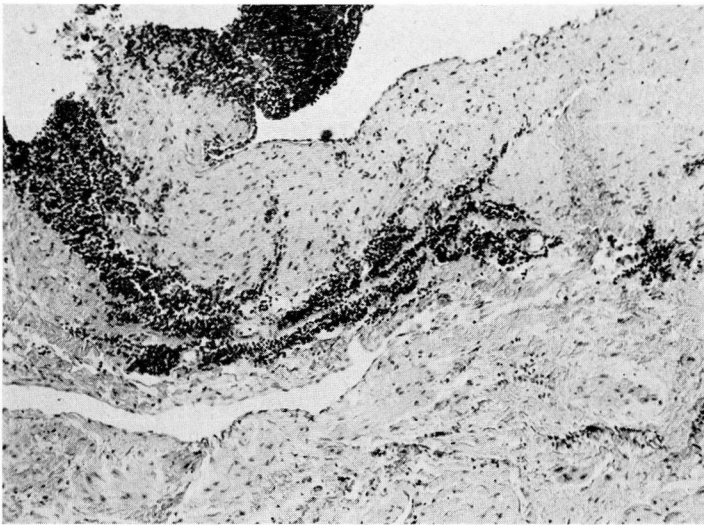
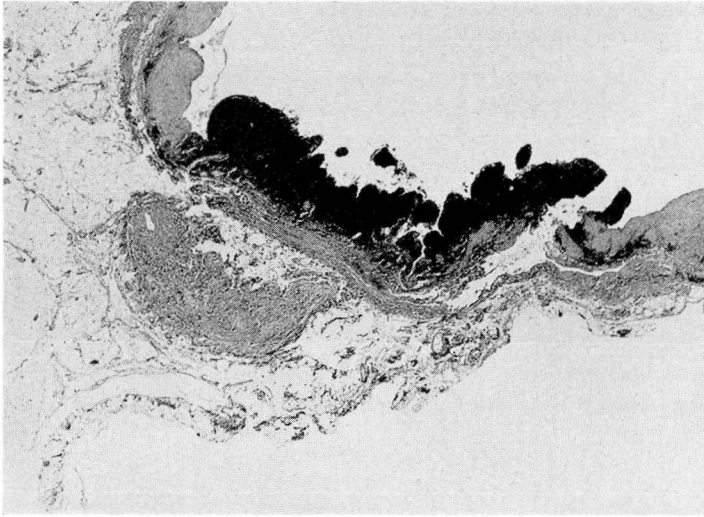
FIG. 2. Gross specimen. Note suture about pedicle.

Comment

Yater¹ has outlined the symptomatology of pericardial tumors. Many of the cases which he has reviewed do not present symptoms attributable to a mediastinal or pericardial lesion, their diagnosis usually resulting from an accidental finding following roentgen examination of the chest. The most out-

HAMARTOMA OF PERICARDIUM

(a)



(b)

FIG. 3. (a and b) Low and high power photomicrographs of cyst wall. Note lymphocytes; collagen and smooth muscle, endothelial lined spaces.

standing symptoms of pericardial tumors have been those due to cardiac tamponade. In none of the reported cases of mediastinal cystic lymphangiomas by Skinner and Hobbs,⁸ Michaelis,⁹ Swift¹⁰ and Sanes et al¹¹ have the symptoms described by our patient been indicated. This lesion is unusual in that it offered none of the technical difficulties so often encountered in the resection

of cysts of lymphatic origin; doubtless the result of their adherence to surrounding structures.

There can be little question that the thoracic cyst encountered in this instance originated in the pericardium and that it was predominantly lymphatic in type. Its histologic structure, with accompanying lymphocytic aggregates designates, as Willis¹² emphasizes, its lymphatic derivation. The inclusion of smooth muscle in the cyst wall suggests the hamartomatous nature of the lesion. The presence of small blood-containing spaces in the wall is a frequent observation in lymphatic cysts.

Conclusion

1. A case of pericardial hamartoma, lymphatic in type, has been reported with a brief review of the pertinent literature.

2. The symptom produced by the lesion suggestive of "something flopping about in the chest" is an unusual manifestation of mediastinal cyst.

The authors are grateful to Dr. John B. Hazard for his assistance in the presentation of this case.

References

1. Yater, W. M.: Tumors of heart and pericardium. Arch. Int. Med. **48**:627 (Oct. 31) 1931.
2. Keller, W. L. and Callender, G. R.: Neurofibroma arising on pericardial pleura. Ann. Surg. **92**:666 (Oct.) 1930.
3. Joel, J., cited by Yater.¹
4. Greenberg, M. and Angrist, A.: Primary vascular tumors of pericardium. Am. Heart J. **35**:623 (April) 1948.
5. Stout, A. P.: Discussion of N. C. Foot's article, Tumors of mediastinum. New York State J. Med. **39**:999 (May 15) 1939.
6. Eliaschewitsch, P. A.: Ein Fall von Perikardcyste. Virchows Arch. f. path. Anat. **270**:868, 1929.
7. Lenkeit, W.: Zysten des Epi- und Perikards. Zentralbl. f. allg. Path. u. path. Anat. **44**:97 (Dec. 10) 1928.
8. Skinner, G. F. and Hobbs, M. E.: Intrathoracic cystic lymphangioma. J. Thoracic Surg. **6**:98 (Oct.) 1936.
9. Michaelis, O.: Die intrathorakalen cystischen Lymphangioma. Deutsche Ztschr. f. Chir. **242**:250, 1934.
10. Swift, E. A. and Neuhoof, H.: Cervicomediastinal lymphangioma with chylothorax. J. Thoracic Surg. **15**:173 (June) 1946.
11. Sanes, S., Macmanus, J. E. and Scatchard, G. N.: Cystic lymphangioma of mediastinum. J. Thoracic Surg. **14**:253 (June) 1945.
12. Willis, R. A.: Pathology of Tumours. St. Louis, C. V. Mosby Company, 1948, p. 710-713.