

# CORRECTION OF SADDLE NOSE DEFORMITIES

FRED R. TINGWALD, M.D.

Department of Otolaryngology

**S**ADDLE NOSE occurs second in frequency to the hump nose deformity among the malformations observed in rhinoplastic practice.

On an etiologic basis saddle nose deformities may be grouped in three broad categories: congenital—a relatively uncommon occurrence; infectious—generally associated with syphilis but often a sequela of pyogenic septal abscess; traumatic—resultant from a direct external blow or the consequence of extensive septal resection.

Despite the etiologic factor involved, these deformities have certain points in common:

1. On the profile projection there is a scapha involving all or a portion of the cephalad two-thirds of the nasal dorsum.
2. On full face observation a real or apparent widening of the nasal dorsum is demonstrated.
3. A decrease of function results due to a decrease in the anteroposterior diameter of the airway.

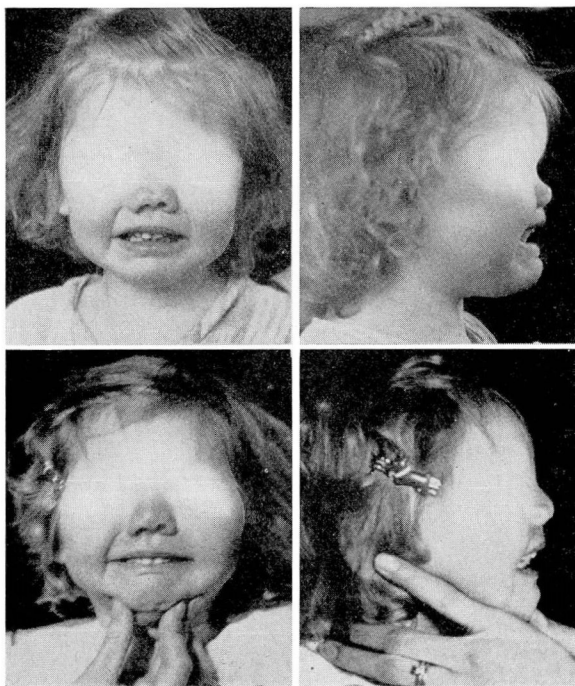


FIG. 1. Case 1.

Except for the minor deformities which can be corrected by a rearrangement of the existent nasal structures, all corrective procedures are based on the premise of camouflaging the defect by means of some type of implant.

Over the years many substances have been recommended for building up tissue defects. Most of these were incapable of becoming an integral part of the tissues and sooner or later either shifted or provoked sufficient inflammatory reaction to necessitate their removal. The materials that have best withstood the test of time are autogenous cancellous bone, usually obtained from the iliac crest, autogenous rib cartilage, and isografts of rib cartilage preserved

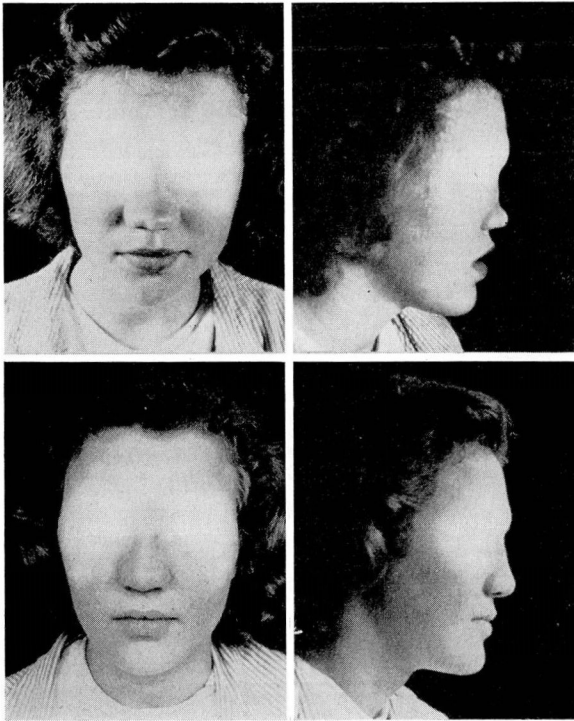


FIG. 2. Case 2.

according to the technic of Pierce and O'Connor. In Case 1, preserved rib cartilage was utilized as the graft material. In Cases 2 and 3 autogenous cancellous bone was the substance of choice.

The bed for the graft in the present series was created through bilateral circumferential vestibular incisions along the caudal margins of the lower lateral cartilages. This type of incision is preferred for several reasons: (1) it has been found adequate for insertion of a graft as large as required to camouflage even the major defects; (2) when a strut is essential for support of the nasal tip, it may be inserted into the columella without recourse to additional incisions;

(3) any necessary modeling of the lower lateral cartilages can be accomplished easily, and (4) there is no externally visible scar.

In constructing the bed for the graft the soft tissues were separated over the nasal dorsum by sharp dissection, thereby preserving a thick layer of skin and subcutaneous tissue which covered the implant and minimized the minor irregularities of its surface.

The 3 cases presented were selected as representative of the three etiologic categories:

Case 1 — Congenital cleft nose with associated saddle deformity (fig. 1).

Case 2 — Saddle deformity following pyogenic septal abscess (fig. 2).

Case 3 — Saddle deformity due to direct trauma (fig. 3).

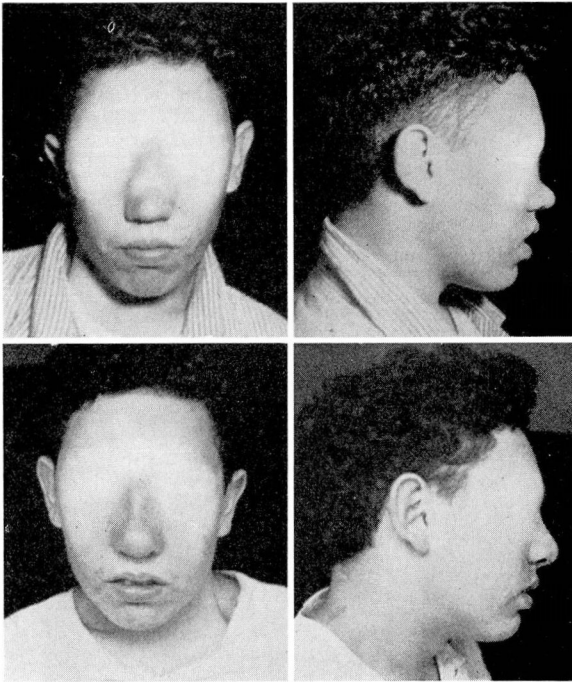

FIG. 3. Case 3.

#### References

1. Fomon, S.: The Surgery of Injury and Plastic Repair. Baltimore, Williams and Wilkins Company, 1939.
2. Fomon, S., Luongo, R. A., Schattner, A. and Turchik, F.: Cancellous bone transplants for correction of saddle nose. *Ann. Otol. Rhin. and Laryng.* 54:518 (Sept.) 1945.
3. Pierce, G. W. and O'Connor, G. B.: Reconstruction surgery of nose. *Ann. Otol., Rhin. and Laryng.* 47:437 (June) 1938.
4. Becker, O. J.: Aids in rhinoplastic procedures. *Ann. Otol., Rhin. and Laryng.* 50:562 (Sept.) 1946.