

SUBLUXATION OF THE CERVICAL SPINE

J. I. KENDRICK, M.D. and ROBERT H. LAMB, M.D.

Department of Orthopedics

SUBLUXATION of the apophyseal articulations of the cervical spine and narrowing of the intervertebral space may follow an injury to an intervertebral cartilage. This abnormal position of the apophyseal articulations is the result of instability in the involved region of the cervical spine.

Hadley¹ has pointed out that apophyseal subluxation in the lumbar region is capable of producing pain in three ways: (1) tension upon the capsular ligaments, (2) encroachment upon the size of the lumen of the intervertebral foramina, and (3) impingement of the ends of the articular processes against the pedicle above and the lamina below, respectively.

Encroachment upon the size of the lumen of the intervertebral foramen is likewise encountered in lower cervical subluxations since the anteroposterior diameter of the intervertebral foramen is smallest at points of maximum lordosis of the spine, namely the lower cervical and lower lumbar regions.

Semmes and Murphy² state that narrowing of the intervertebral disk can allow narrowing of the intervertebral foramina only in the vertical diameter; such narrowing is not sufficient to cause pressure on the nerve root unless the intervertebral space is completely obliterated and there is destruction of the adjacent surfaces of the vertebrae. In some cases, however, we believe that subluxation of the apophyseal joints develops and the narrowing of the intervertebral foramen is manifested in the anteroposterior diameter as well as in the vertical diameter. This abnormal alignment of the neck can be visualized readily in the lateral roentgenograms of the cervical spine. Definite forward migration of the head and cervical spine above the level of the cartilage injury is observed, with maximum angulation at this level. Since the posterior walls of the intervertebral foramina consist of the joints made by the articular processes, any forward displacement of these processes produces encroachment upon the foramen and reduces the clearance for the nerve. Furthermore, since flexion and extension of the neck are made by the vertebrae rocking at the articular facets and since the foramina are anterior to the facets, it is obvious that when the neck is bent forward there is a further reduction in the size of the foramen.³ The oblique roentgenograms will show a narrowing of the intervertebral foramen at the level of the involved disk. Clinically the poker spine which is seen in the cervical and lumbar regions following nerve root pressure is probably an adaptive mechanism to increase the stability of the spine in these regions.

We are presenting 2 almost identical cases in which the abnormal position of the apophyseal articulations was so evident as to present a true subluxation and the patients received relief of pain and paresthesias only after a prolonged period of traction and restoration of the normal alignment of the neck.

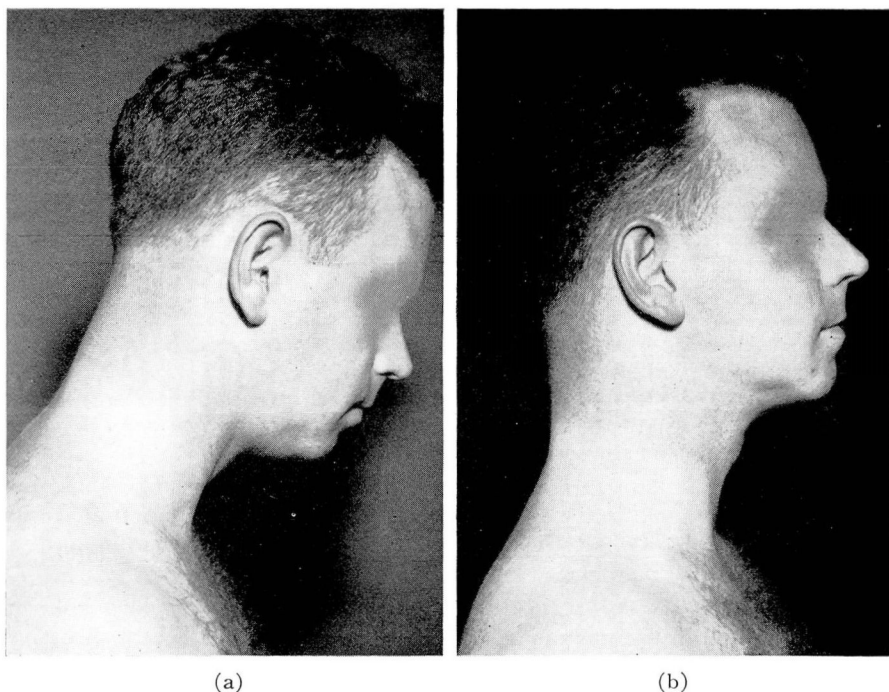


FIG. 1. Case 1. (a) Appearance before reduction of subluxation. (b) After reduction of subluxation and fusion.

Both patients had previously undergone operations of the cervical spine. In case 1 a protruded disk had been removed at the sixth cervical interspace 4 years before. In case 2 a protruded disk, partially osseous in character, had been removed from the sixth cervical interspace 15 months previously. In both patients, the head was carried in a forward position (figs. 1a and 3a), and the muscle spasm was so extreme that extension of the neck was impossible.

In each instance the lateral roentgenogram (figs. 2a and 4a) showed the forward migration of the head and cervical spine above the level of the subluxation and the angulation at the level of the subluxation.

Case Reports

Case 1. A 30-year-old white man was first seen on April 25, 1945, with the chief complaint of pain in the right shoulder and down the right arm to the elbow, of 2 months' duration. On examination tenderness was demonstrated over the spines of C₆ and C₇; pressure immediately lateral to the spines of C₆ and C₇ on the right aggravated the pain in the right shoulder and right arm. The patient also experienced slight weakness of grip in the right hand.

Past history revealed an injury to the neck at the age of 14, sustained when he was thrown forcibly against the top of an automobile. However, he experienced no dis-

bility at that time. He subsequently slipped and fell on the ice, striking his left hip and left shoulder about 3 weeks prior to the onset of the present complaints.

During a 6 week period following his first visit, the patient developed numbness and hypesthesia of the right thumb and index finger and noticed the onset of weakness in the right arm, accompanied by fibrillary twitchings in the right deltoid and pectoral muscles. He also showed moderate diminution in the triceps reflex on the right. Lumbar puncture was normal. The patient was admitted to the hospital on June 3, 1945, and a protruded intervertebral disk was removed between C_6 and C_7 on the right. He had an uneventful postoperative course and was discharged on the fifteenth postoperative day with relief of his pain and numbness, but with definite diminution of the triceps reflex on the right. He remained symptom-free for 4 years until May 15, 1949, when his head dropped backward suddenly while riding on a cart and he felt a snap in the neck.

The patient was re-admitted to the hospital 3 weeks later with the identical signs and symptoms which had existed before the removal of his ruptured intervertebral disk 4 years previously.

His pain gradually subsided and was almost entirely relieved by cervical traction for 12 days. An interlaminar cervical fusion was performed from C_5 to C_7 , with osteoperiosteal bone graft from the tibia. The patient was discharged on the thirty-seventh postoperative day with a cervical brace which he wore for 8 months. X-rays (fig. 2b) were made 9 months after operation and showed satisfactory fusion of C_5 to C_7 and clinically he presented no symptoms with the exception of slight stiffness in the neck. The head was carried in a normal position (fig. 1b).

Case 2. A 36-year-old white man was first observed on February 2, 1948, with the principal complaint of increasing pain in the right shoulder of 5 months' duration. The

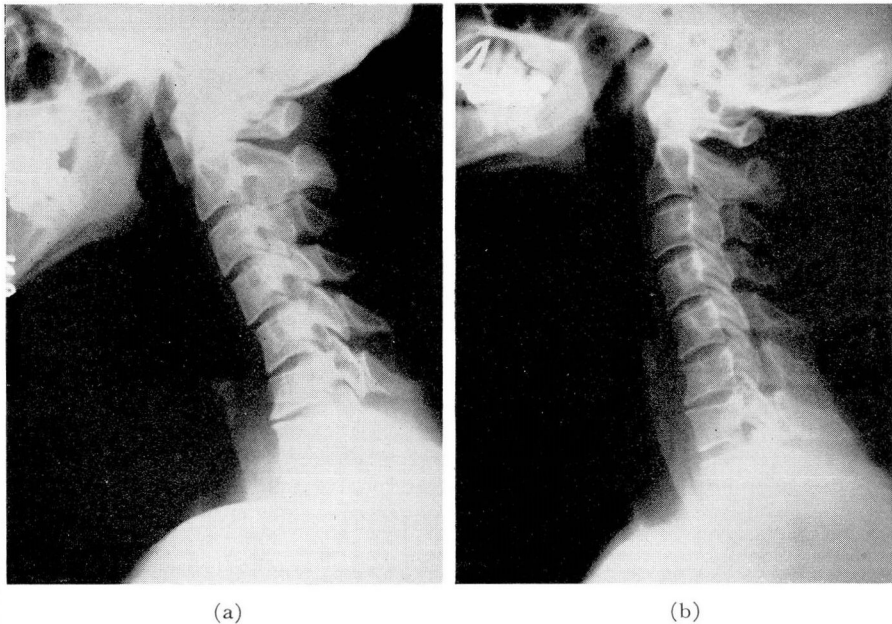


FIG. 2. Case 1. (a) Lateral x-ray showing subluxation. (b) Showing reduction of subluxation and fusion.

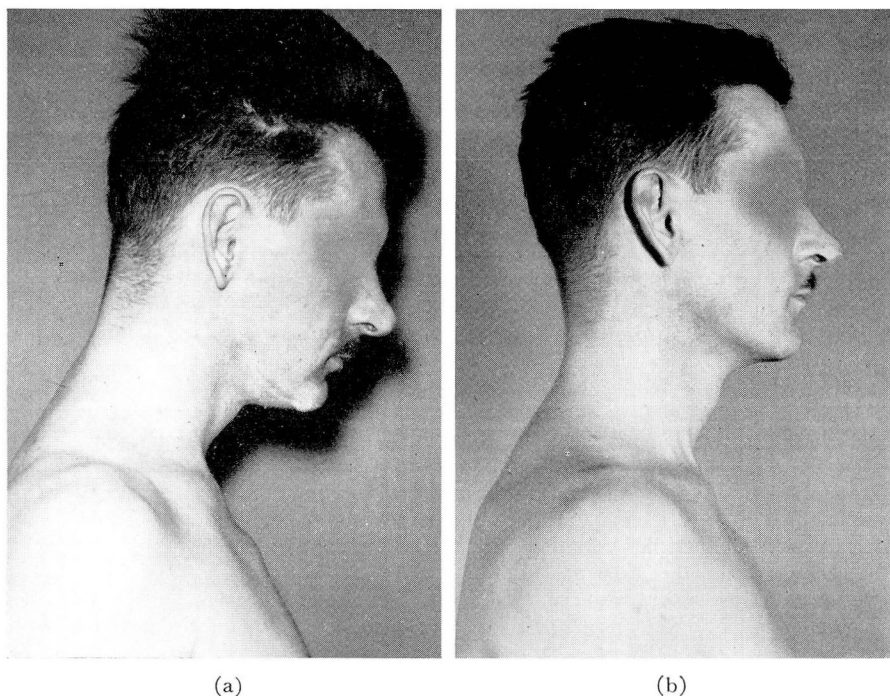


FIG. 3. Case 2. (a) Appearance before reduction of subluxation. (b) After reduction of subluxation and fusion.

pain was worse over the posterior superior border of the trapezius, the lateral portion of the pectoral muscles and over the extensor muscles in the right forearm—so severe that the patient was unable to sleep nights.

On physical examination flexion and lateral motions of the spine aggravated the right shoulder and arm pain. There was slight weakness of grip in the right hand and point tenderness to the right of the spines of C_6 and C_7 and over the posterior superior border of the trapezius on the right. The right radial reflex was absent and the right triceps moderately diminished.

He was admitted to the hospital and cervical traction afforded relief of the pain in the right shoulder in 6 days; however he experienced some numbness in the right index finger. Lumbar puncture was normal.

At operation a disk protrusion was found at C_6 , C_7 , which was partially osseous in character. The following day the patient reported the best night's sleep experienced since the onset of the present condition; however, numbness persisted in the right index finger. He was discharged on the fifteenth postoperative day with a cervical brace, which he wore for 3 months.

He remained symptom-free for 15 months, except for subjective numbness in the right index finger. He then fell while working and received a mild injury to the right chest wall, at which time there was recurrence of pain in the right shoulder and right arm. He was re-admitted to the hospital and was almost completely relieved of pain following restoration of the normal alignment of his cervical spine after a period of

2 weeks in traction. A fusion was done from C₄ to C₇ with osteoperiosteal graft from the tibia. He had an uneventful postoperative course and was discharged on the twenty-ninth postoperative day with a cervical brace which he wore for 7 months. His range of motion improved and he returned to his work as an electrician 9 months after fusion. Cervical roentgenograms 1 year after operation showed fusion from C₄ to C₇ (fig. 4b). The head was carried in a normal position after fusion (fig. 3b).

Discussion

When the instability of the cervical spine following injury of an intervertebral cartilage is of a mild or moderate degree, and narrowing of the intervertebral foramina is only in the vertical diameter, conservative treatment is sufficient to effect relief of pain or paresthesias. The conservative treatment which we recommend is directed toward correcting the abnormal alignment of the cervical spine and maintaining normal alignment until stability can be accomplished by muscle-strengthening exercises. The patient is hospitalized and cervical traction begun by means of a Sayre sling with four-pound weight attached. Traction is employed for 1 hour three times daily and gradually increased to 1½ hours four times daily over a period of 4 to 6 days. The patient also receives daily physical therapy to the neck to overcome muscle spasm. Many patients require 2 weeks or more of such treatment before experiencing relief of pain or paresthesias.

In the cases we have presented, the instability was so pronounced that a

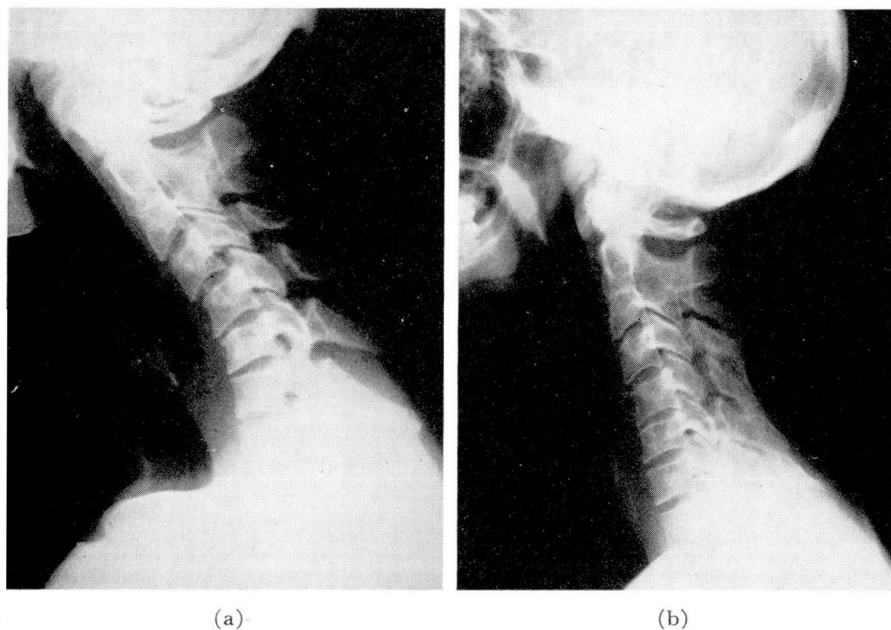


FIG. 4. Case 2. (a) Lateral x-ray showing subluxation. (b) Showing reduction of subluxation and fusion.

true subluxation developed and narrowing of the intervertebral foramen in the anteroposterior diameter, as well as the vertical diameter, resulted in severe nerve root pressure. We believe that, in patients presenting this degree of instability, a fusion is necessary to maintain the normal alignment after reduction of the subluxation has been accomplished.

References

1. Hadley, L. A.: Subluxation of apophyseal articulations with bony impingement as cause of back pain. *Am. J. Roentgenol.* **33**:209 (Feb.) 1935.
2. Semmes, R. E. and Murphy, F.: Syndrome of unilateral rupture of sixth cervical intervertebral disk, with compression of seventh cervical nerve root; report of 4 cases with symptoms simulating coronary disease. *J.A.M.A.* **121**:1209 (April 10) 1943.
3. Nachlas, I. W.: Scalenus anticus syndrome or cervical foraminal compression, *South. M. J.* **35**:663 (July) 1942.