

DIAGNOSIS AND TREATMENT OF AORTIC RINGS

F. MASON SONES, JR., M.D.
Department of Cardiovascular Diseases
and
DONALD B. EFFLER, M.D.
Department of Thoracic Surgery

AORTIC rings constitute a functionally important group of anomalies of the aortic arch which may compress the trachea, esophagus, or both. Many are amenable to surgical correction. It is our purpose to present the available methods by which they may be recognized, and to discuss the problems involved in treatment.

Edwards¹ has presented a logical and complete classification of the possible anatomic variants of the aortic arch system, based upon his recognition of the fact that a functioning double aortic arch exhibits the most complete adult representation of the six embryonic arches. From this basic pattern he classified the reported anomalies, and predicted others, on the premise that atresia of either arch at any given level would cause a specific anatomic variant of the complete pattern.

We believe that a simpler clinical classification, derived from that of Edwards, is useful in the practical approach to the recognition of these anomalies. We have limited the scope of the classification to those elements which are clinically recognizable in the living patient. In our experience it has led to reasonably precise preoperative evaluation of the problems encountered. Its usefulness depends upon the physician's ability to locate the position of the upper portion of the descending aorta. In each group the fundamental pattern is an anterior aortic arch with the descending aorta on the homolateral side. This is the normal structure of the aorta when it occurs on the left, and when seen on the right it is simply the mirror image of the normal pattern. In each group two other clinically recognizable and functionally important variants occur, which may compress the trachea or esophagus.

Group 1. Left descending aorta

- a. Left aortic arch (normal adult aorta).
- b. Left aortic arch with right subclavian artery arising from descending aorta distal to the left subclavian artery.
- c. Functioning right aortic arch, with or without atresia of the left aortic arch. If the left arch is patent a true double arch is present.

Group 2. Right descending aorta

- a. Right aortic arch (mirror image of normal aorta).
- b. Right aortic arch with left subclavian artery arising from descending aorta distal to the right subclavian artery.
- c. Functioning left aortic arch, with or without atresia of the right aortic arch. If the right arch is patent a true double arch is present.

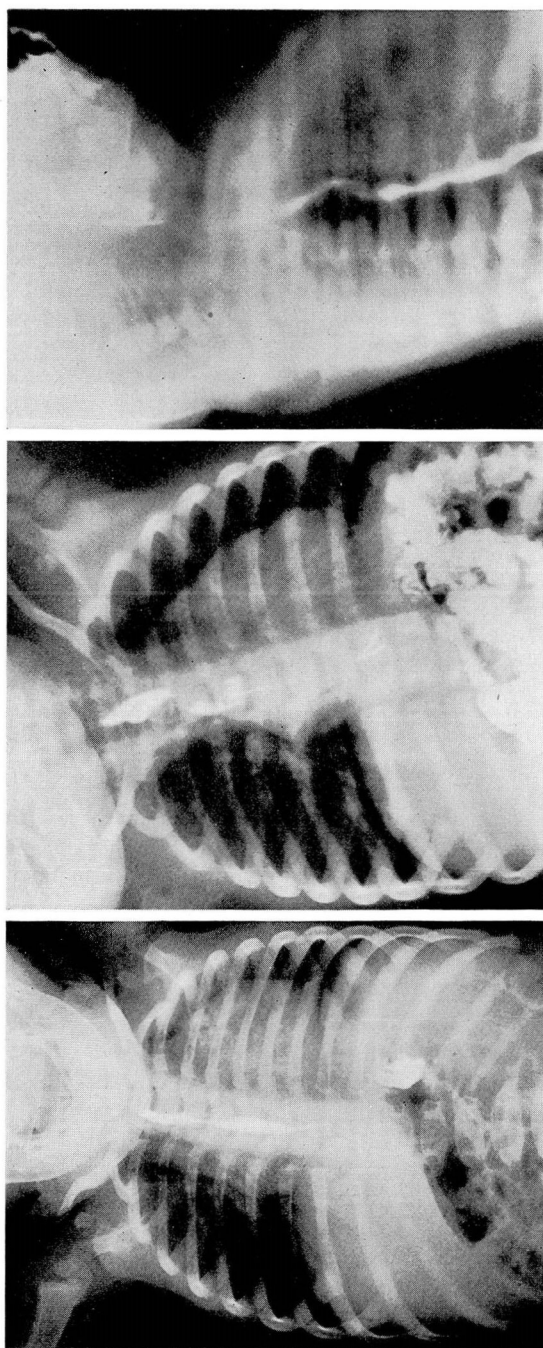


FIG. 1. Fourteen month old girl, weight 15 pounds. Recurrent severe pneumonitis with temperature elevation to 106 F., accompanied by severe dyspnea and cyanotic attacks. (a) Apparently normal barium swallow with infant in upright position. (b) Large oblique esophageal defect caused by retroesophageal right subclavian artery; film made with child in supine position. (c) Right oblique view showing anterior displacement of esophagus at level of aortic arch.

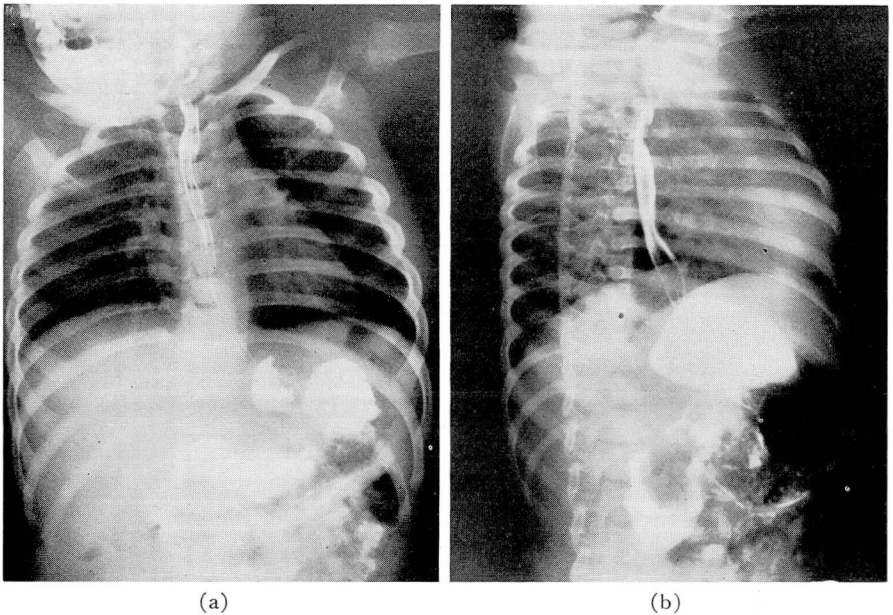


FIG. 2. (Same case as figure 1). Postoperative films in supine position after resection of anomalous right subclavian artery. (a) Posteroanterior view showing normal esophageal pattern. The left aortic arch and descending aorta displace esophagus to right of midline. (b) Normal posterior displacement of esophagus at level of aortic arch in the right oblique view.

The normal left aortic arch crosses transversely from right to left anterior to the trachea and descends on the left side. All of its branches arise anterior to the trachea and no compression is produced.

The most frequently encountered deviation from this normal pattern is the presence of a right subclavian artery having its origin from the upper postero-medial aspect of the left sided descending aorta, distal to the origin of the left subclavian artery. From this point it passes upward and to the right behind the esophagus to reach the right axilla. The characteristics of this anomaly are illustrated in figures 1 and 3. Occasionally the anomalous subclavian artery may pass to the right axilla between the trachea and esophagus and infrequently it crosses to the right in front of the trachea. When such a vessel exists there is, of course, no innominate artery on the right side, and the first branch from the aortic arch is the right common carotid.

When the aortic arch opposite the side of the descending aorta persists as a functioning structure it crosses the midline posterior to the esophagus. Thus, a functioning right aortic arch passes above the right main bronchus to the right of the trachea and esophagus, then crosses behind the esophagus to reach its junction with a left descending aorta. When both aortic arches persist as functioning structures, the left passes anteriorly across the trachea in its usual position, and the right passes posteriorly behind the esophagus as described.

The left is usually the smaller of the two arches, and a segment is often completely atresic; the right arch is seldom smaller.

When the upper part of the descending aorta is displaced to the right side of the esophagus, the mirror images of the patterns previously described occur. The anomalies in this group are encountered less frequently than are those in the first group. Examples of each have been reported, however. The right arch crosses above the right main bronchus anteriorly to reach the right descending aorta, and no compression results. An anomalous left subclavian artery may arise as the fourth branch of a right aortic arch and right descending aorta. Such a vessel will cross upward behind the esophagus from right to left to reach the left shoulder (fig. 4). A functioning left aortic arch will pass to the left and posteriorly above the left main bronchus, and then turn sharply to the right behind the esophagus to join the descending aorta. If both arches persist, the left is the retroesophageal vessel, while the right is the anterior segment. An anomaly of this group is illustrated in figure 5.

Persons with aortic rings which cause a large amount of pressure on the trachea or esophagus will develop symptoms shortly after birth. In many experiencing less severe compression, symptoms may not appear until advanced age has been reached, when degenerative changes lead to widening of the aortic arch and its branches. Seldom will a young adult present definite evidence of compression. When such symptoms exist in this age group they may strongly suggest the presence of globus hystericus, and the patient may suffer for many years with a diagnosis of functional disease.

In infancy partial occlusion of the trachea often results in almost constant stridor. It is manifested by noisy inspiratory and expiratory sounds which are aggravated when the child is awake and excited and are much less pronounced during sleep. More frequently the most important functional embarrassment is caused by pressure upon the esophagus which leads to repeated episodes of regurgitation, followed by aspiration of food and mucus into the bronchial tree. The resulting pulmonary atelectasis and pneumonitis are the commonest causes of death.

Esophageal compression is especially dangerous during the first months of life when control of deglutition is most poorly developed. For this reason the most dangerously ill patients are often those in whom the nature of the lesion is hardest to define. Of 19 infants under 2 years of age reported in the review by Griswold and Young,² 14 died as a result of the lesion, 3 survived successful surgery and 2 died of causes not related to the anomaly. The acute pulmonary complications occurring in this age group draw attention to the lungs while the basic vascular lesion may be overlooked. Constricting anomalies of the aortic arch do not produce significant heart murmurs and there is no cause for cardiomegaly. The dramatic picture of cough, labored breathing, fever, paroxysmal attacks of cyanosis, and radiologic evidence of atelectasis or pneumonitis is dominant.

In older children and adults there may be a history of respiratory difficulties during infancy, but most often the lesion is asymptomatic. Occasionally there is dysphagia, particularly with ingestion of solid foods. Patients beyond middle age may develop this symptom, or persistent hoarseness.

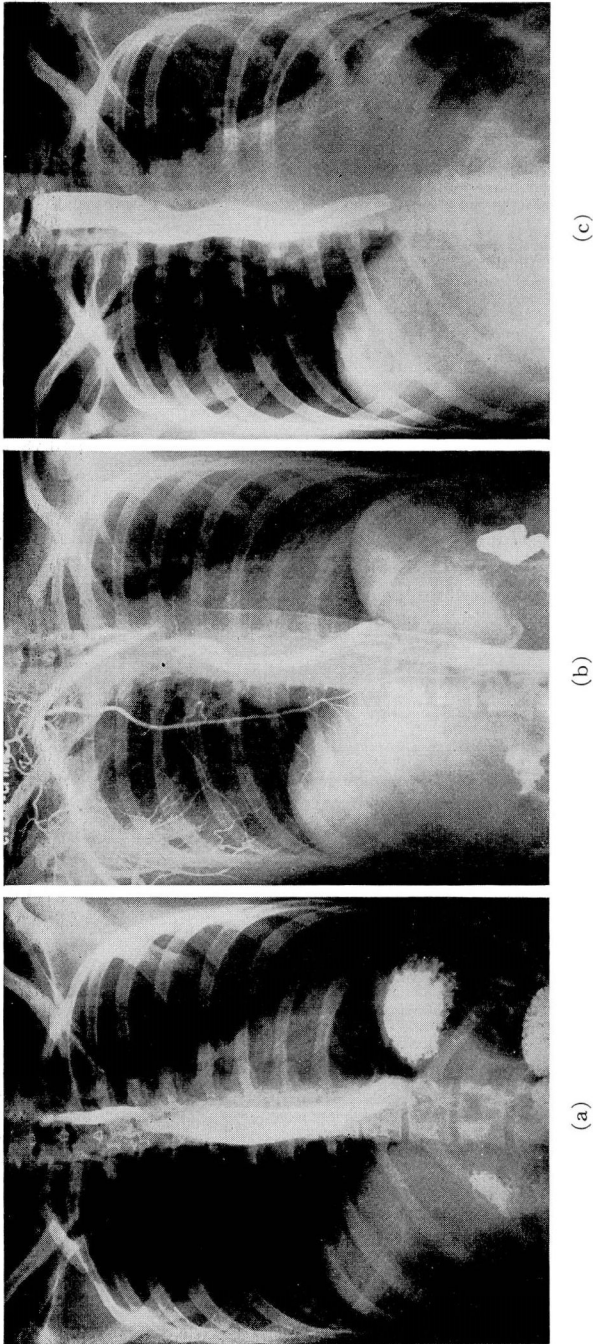
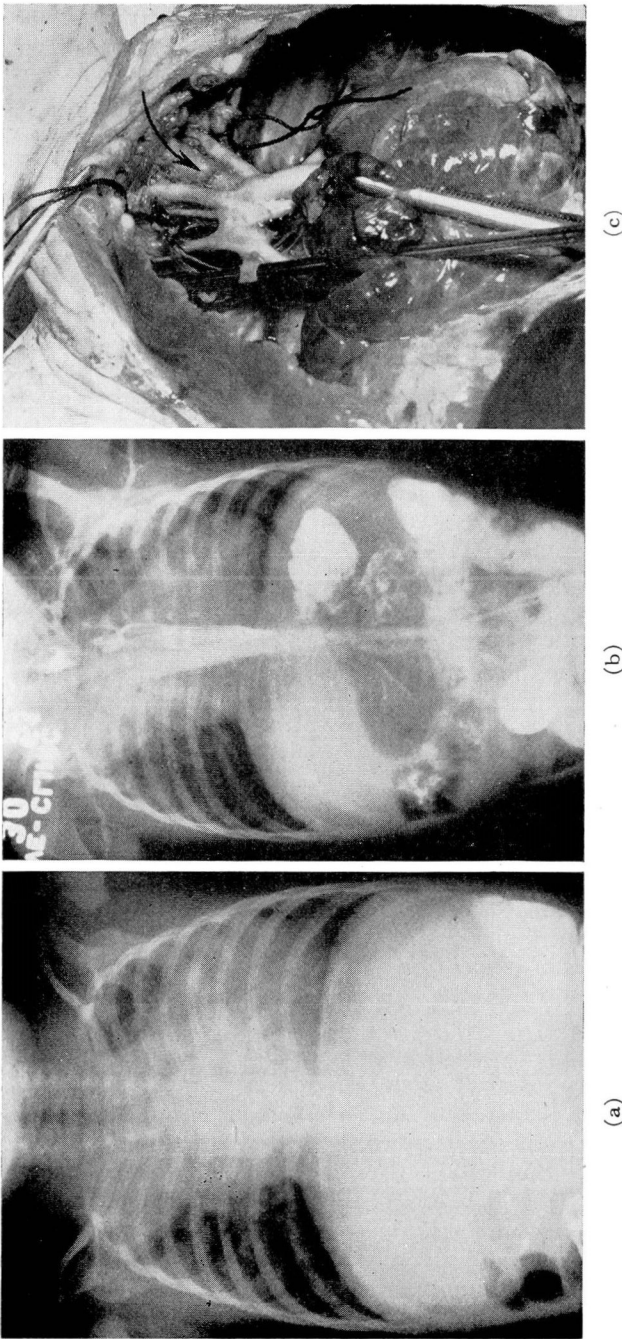


FIG. 3. Thirty-three year old woman with persistent dysphagia since adolescence. No pulmonary symptoms. (a) Posteroanterior view reveals oblique filling defect in barium-filled esophagus. Esophagus displaced to the right; aortic knob poorly defined. (b) Retrograde aortogram from right brachial artery demonstrates right subclavian artery crossing esophagus posteriorly to its origin from left descending aorta. Note relation of descending aorta to barium-filled esophagus. (c) Normal esophageal pattern demonstrated post-operatively.



(a) (b) (c)

FIG. 4. Twenty week old girl, weighing 6 pounds. Intractable pneumonia cough, fever, labored breathing, intermittent cyanosis, failure to gain weight. (a) Chest x-ray demonstrating right upper lobe pneumonia with atelectatic changes in the left upper lobe. (b) Retrograde aortogram from left brachial artery demonstrates left subclavian artery arising anomalously from right descending aorta; produces oblique filling defect in barium-filled esophagus, which is displaced to the left. Descending aorta to right of esophagus is well visualized. (c) Postmortem specimen shows right aortic arch crossing the trachea anteriorly to join right descending aorta. First branch on the left of the trachea (marked by arrow) is left common carotid. Right common carotid arises to the right of trachea. Vessel arising from distal arch is right subclavian artery. Left subclavian artery arises from posterior aspect of upper descending aorta, and is shown here passing around probe which is displacing the origin of vessel anteriorly into view.

When stridor or recurrent acute lower respiratory symptoms suggest the possibility of an anomaly of the aortic arch in infancy, it is usually a simple matter to confirm the presence or absence of the gross lesion. The definitive diagnosis of the abnormality is much more difficult. Without adequate preoperative knowledge of the anatomic structures any surgical attempt at correction is essentially an exploratory procedure, and the literature is replete with accounts of difficulties encountered at operation when only incomplete or fragmentary preoperative diagnoses were possible.^{3,4}

Observation by fluoroscopy of the barium or lipiodol-filled esophagus is the simplest and most informative method available for detecting the presence of an anomaly of the aortic arch. Arkin,⁵ Neuhauser,⁶ and others have described ordinary deviations from the normal esophageal pattern.

The normal left arch and descending aorta do not impinge upon the posterior surface of the esophagus at the level of the aortic arch. In the postero-anterior view there is lateral displacement of the esophagus toward the right, and a slight filling defect is usually seen on the anterior surface of the esophagus in the right anterior oblique view at the level of the arch. The aortic knob is easily visualized in adults on the left side, though it may be difficult to recognize in infants and small children. The left descending aorta displaces the esophagus slightly to the right of the midline in its upper half so that, in the absence of mediastinal shift, the esophagus appears to be closer to the right border of the spine in the posteroanterior view than to the left.

The mirror image of this pattern is produced by a right aortic arch and descending aorta. The aortic knob, if visible, is present on the right side, although it is often obscured by the shadow of the superior vena cava. No posterior filling defect is seen, and the anterior filling defect is usually more prominent in the left anterior oblique than in the right oblique view. In the postero-anterior view the esophagus is displaced to the left at the level of the aortic arch, and the upper half of the esophagus appears closer to the left border of the spine than to the right.

The retroesophageal segment of constricting anomalies of the aortic arch produces a filling defect on the posterior aspect of the esophagus, displacing it anteriorly; this should always be evident on careful observation. The rare exceptions to this rule are instances when an anomalous subclavian artery arises as the fourth branch of the aortic arch and passes to the axilla on the side opposite the descending aorta between the esophagus and trachea, or anterior to the trachea. Ninety per cent of such vessels pass posterior to the esophagus,⁷ and are easily recognized. It is, therefore, of greatest importance to study the appearance of the opacified esophageal lumen, with the patient lying down, in both oblique and the lateral projections. If no anterior displacement of the esophagus exists, it is improbable that any of the anomalies under consideration exist. The patient must be studied in the supine position, since occasionally an important defect will escape recognition if the study is made with the patient upright (figs. 1 and 2). Barium outlines the esophagus more effectively than does lipiodol, though if a tracheoesophageal fistula is suspected in an especially young infant, the danger of barium aspiration outweighs this con-

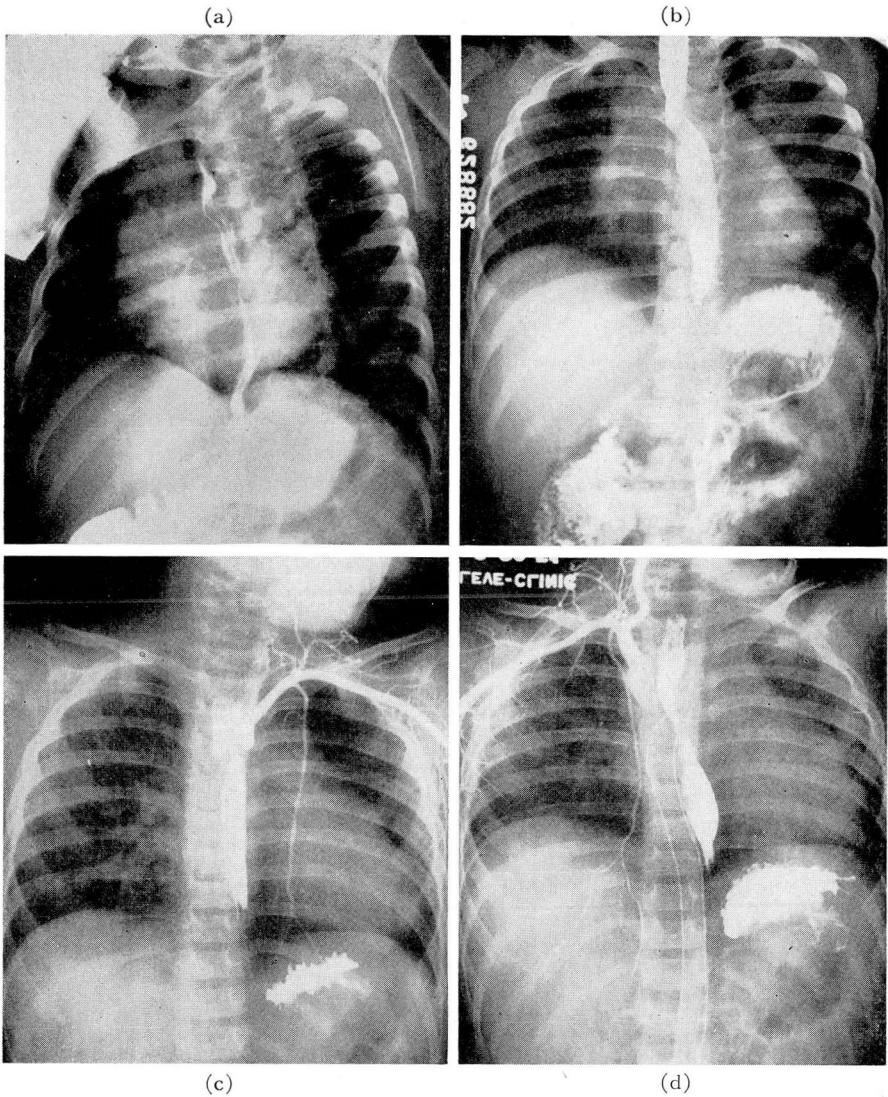


FIG. 5. Twenty-two month old boy had repeated severe episodes of pneumonitis, accompanied by severe dyspnea and cyanosis. (a) Left oblique view showing anterior displacement of barium-filled esophagus at level of aortic arch, indicating presence of a retroesophageal vessel. (b) Barium-filled esophagus visualized in posteroanterior view. Oblique filling defect crosses esophagus from low on right toward left shoulder. Above this there is indentation of esophagus toward right, and below the oblique defect esophagus appears to be displaced toward left. (c) Retrograde aortogram from left brachial artery demonstrates that left subclavian artery does not cross esophagus and therefore does not cause the oblique filling defect seen in (a) and (b). Beneath the barium column immediately above left diaphragm the descending aorta is visible and is displaced to the right of usual position. (Compare with figure 3b). (d) Retrograde aortogram from right brachial artery demonstrates a right innominate artery which does not cross the midline and faintly demonstrates right descending aorta below esophageal deformity. This would appear to be a left aortic arch with retroesophageal segment crossing to join right descending aorta.

sideration. Small quantities should be used in order to diminish the possibility of aspiration and to avoid overdilatation of the esophagus, which will prevent easy recognition of a pressure defect.

Partial occlusion of the trachea may be demonstrated by instillation of lipiodol into the trachea or by bronchoscopy in instances where this is suspected. Plain lateral and posteroanterior films may suggest narrowing of the trachea above the bronchial bifurcation when no significant narrowing is actually present. When occlusion is suggested by history or routine x-ray study, the question should be resolved by one of the more definitive technics.

Although we believe that we can recognize the presence of esophageal deformity due to an aortic ring, we have, nevertheless, experienced great difficulty in visualizing by study of the barium filled esophagus, all of the elements necessary to make a diagnosis accurate enough to assure a reliable surgical approach to its cure. In infants we sometimes have been unable to determine the position of the descending aorta because of the presence of mediastinal shift due to pulmonary disease; this positively must be ascertained before an anatomic diagnosis is possible. The apparent breadth and direction of abnormal filling defects in the esophagus have been used, often correctly, as criteria for establishing the identity of the retroesophageal vessel. This may be misleading. A deformity passing obliquely across the posterior aspect of the esophagus at the level of the aortic arch is probably caused by a retroesophageal subclavian artery, but an aortic arch passing posterior to the esophagus to reach a descending aorta on the opposite side may pass obliquely downward, rather than transversely across, to this junction. The apparent width of the compressed esophageal segment is of little value in this differential diagnosis, since a small vessel may produce an apparently large defect. This is well illustrated in figure 4. The defect in the esophagus appears to be as wide as the descending aorta, but was produced by the much narrower subclavian artery.

Keith and Forsyth⁸ have recently shown the practicability of demonstrating the presence of coarctation of the aorta and patent ductus arteriosus in infants by retrograde aortography. We have utilized this technic in order to clarify some of the problems outlined previously, when preliminary study of the barium-filled esophagus has indicated the existence of a constricting anomaly of the aortic arch.

The method used has been essentially that described by Keith and Forsyth. General anesthesia has not been utilized. In infants premedication consisted of morphine sulfate gr. 1/64 and atropine sulfate gr. 1/1000 per 10 pounds of body weight. Adults were given the same medications in appropriate doses 30 minutes before the test.

The brachial artery opposite the apparent side of the descending aorta was selected. After local infiltration of the skin and periarterial tissues, an incision was made over the artery above the antecubital space, and the largest possible needle was introduced under direct vision. In infants an 18 gage or larger needle was used, and in adults a 12 gage cannula was employed. Injection of contrast substance was made into the artery as rapidly as possible. Both 35 and 70 per cent diodrast were used on different occasions. Immediately prior

to injection a swallow of barium was given to outline the course of the esophagus. X-rays have been taken in the posteroanterior view with the patient in the supine position in order to lateralize clearly the descending aorta in its relation to the esophagus. One and one-fourth cc. of diodrast per kg. of body weight was given to infants, and in adults the total dose varied between 30 and 40 cc.

Tight manual compression upon the carotid artery on the homolateral side at a level immediately above the clavicle was made during the moment of injection, to reduce the possibility of a large amount of dye passing directly into the cerebral circulation. Failure to do this resulted, on one occasion, in immediate syncope, accompanied by the clinical appearance of cardiac asystole of about 15 seconds' duration. No significant reaction occurred in any other patient when satisfactory carotid compression was accomplished. The possibility of introducing a large amount of dye into the cerebral circulation is greatest if the brachial artery used is derived from an innominate artery. In dealing with these anomalies one may not be certain of the location of the innominate artery, if one is present. We believe, therefore, that adequate carotid compression is essential during every injection.

Since we have been unable to expose x-ray films more rapidly than once per second, we have made a single exposure at the instant the injection was completed.

In all patients studied, this technic permitted adequate diagnosis for the determination of operability, and allowed selection of the best surgical approach to the lesion.

In every case the best surgical approach to the defect is from the side of the upper portion of the descending aorta. Posterolateral incision through the fourth interspace is chosen in the case of retroesophageal subclavian arteries. In this manner it is possible to mobilize the upper descending aorta below the level of the homolateral subclavian artery and to divide the anomalous vessel at its origin, thus allowing it to retract to the opposite side; this effectively relieves the esophageal compression.

In those instances in which the entire aortic arch, or the largest segment of a double aortic arch, passes posterior to the esophagus to reach the descending aorta on the opposite side, anterolateral approach on the side of the descending aorta is indicated. We doubt the value of operation in these cases unless organic occlusion of the trachea is demonstrated, since resection of the posterior arch cannot be performed to relieve esophageal compression. The only benefit to be anticipated from surgery is relief of tracheal occlusion.

In the uncommon event that a double aortic arch is demonstrated, in which the anterior arch on the side of the descending aorta is shown to be of equal or larger size than the posterior contralateral arch, division of the posterior arch may be accomplished by anterolateral approach on the side of the descending aorta. This will effectively relieve esophageal compression. Division of the posterior arch must be done distal to the origins of the homolateral carotid and subclavian arteries.

If symptoms in an infant are of mild degree, or if the defect is recognized

as inoperable, intelligent medical management will decrease morbidity and often insure survival. The frequency and magnitude of aspirations may be materially reduced by the simple expedient of restraining the infant on its abdomen during sleep and after feedings, with the head at a level slightly lower than the feet. This will facilitate drainage of regurgitated food and secretions. The mothers of such children must be taught the importance of slow and careful feeding, and bottle propping must be absolutely forbidden. Mothers must also be instructed in the recognition of the acute signs of aspiration and in the prompt institution of postural drainage should this occur.

If postural drainage does not result in rapid clearing of symptoms, skillful bronchoscopic drainage may be necessary. Penicillin is given prophylactically for 48 to 72 hours after any functionally significant aspiration, and materially reduces the incidence of postaspiration pneumonitis. It is often possible by the judicious use of these measures to support an infant through the earliest and most hazardous months of life; after the age of 2 years the outlook for survival is excellent.

Summary

1. A simple clinical classification of constricting anomalies of the aortic arch is presented, which has proved adequate for practical evaluation and treatment.
2. Retrograde aortography has been a useful technic for a more accurate diagnosis of these lesions. Its applicability is illustrated.
3. The indications for surgery and the selection of the best operative approach are discussed briefly.
4. Basic principles of medical management are outlined.

References

1. Edwards, J. E.: Anomalies of derivatives of aortic arch system. *M. Clin. North America* **32**:925 (July) 1948.
2. Griswold, H. E. and Young, M. D.: Double aortic arch. *Pediatrics* **4**:751 (Dec.) 1949.
3. Gordon S.: Double aortic arch. *Arch. Pediat.* **30**:428 (April) 1947.
4. Crystal, D. K., Edmonds, H. W. and Betzold, P. F.: Symmetrical double aortic arch. *West. J. Surg.* **55**:389 (July) 1947.
5. Arkin, A.: Double aortic arch with total persistence of right and isthmus stenosis of left arch; new clinical and x-ray picture. *Am. Heart J.* **11**:444 (April) 1946.
6. Neuhauser, E. B. D.: Roentgen diagnosis of double aortic arch and other anomalies of great vessels. *Am. J. Roentgenol.* **56**:1 (July) 1946.
7. Holzapfel, G., cited by Gross, R. E. and Ware, P. F.: Surgical significance of aortic arch anomalies. *Surg., Gynec. and Obst.* **83**:435 (Oct.) 1946.
8. Keith, J. D. and Forsyth, C.: Aortography in infants. *Circulation* **2**:907 (Oct.) 1950.