

# BARTHOLIN'S CYSTS

JAMES S. KRIEGER, M.D.

Department of Gynecology

and

GEORGE CRILE, JR., M.D.

Department of Surgery

NUMEROUS therapies have been suggested for acute and chronic Bartholin's cysts. Their multiplicity indicates that no wholly satisfactory treatment has yet been found. Generally incision and drainage should be carried out in the acute stages; definite therapy instituted in the past in the chronic stages has involved destruction of the gland.

Mathieu<sup>1</sup> has advocated cruciate incisions with gauze wicking to assure adequate drainage. This is generally followed by excision of the cyst as described by Catell.<sup>2</sup> Schauffler<sup>3</sup> advocated cauterization of the lining wall of the cyst in both the acute and chronic stages. This method not only destroys the gland but also necessitates hospitalization.

Davies<sup>4</sup> attempted to overcome the disadvantages of the above procedures by incising the cysts under local anesthesia and repeatedly packing them with iodoform gauze until the drainage tract had become epithelialized. This provides a permanent new ostium and allows normal function to return.

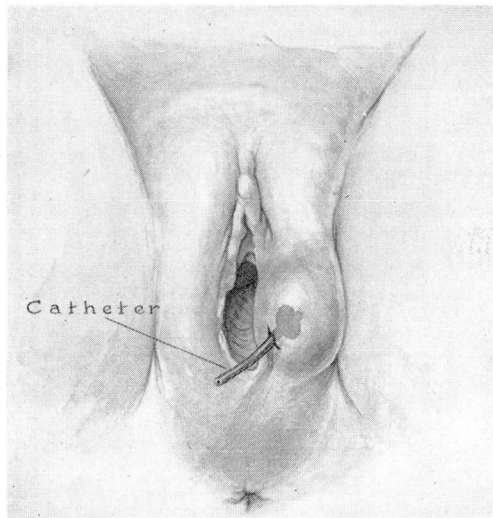


FIG. 1. Catheter drainage of Bartholin's cyst.

For the past several years, we have employed a modification of the above treatment. This was suggested by the catheter drainage of pilonidal cysts previously reported by Crile.<sup>5</sup> Following incision of the cyst, under local anesthesia in the office, a small mushroom catheter is inserted into the cavity (fig. 1). It is cut off close to the skin and a small safety pin is used to prevent its retraction into the cyst. The catheter provides excellent drainage and is nonirritating. It is left in place until epithelialization is complete; this is generally accomplished in 2 to 4 weeks. Patients generally become unaware of the catheter. The only complication we have seen is inadvertent removal of the tube before the tract is well established, with resultant closure. If this occurs, one need only await recurrence of the cyst and repeat the process of catheter drainage. A considerable advantage of this treatment is its application in both the acute and chronic phases of the disease.

A simplified office procedure for the treatment of Bartholin's abscesses and cysts has been presented. This therapy eliminates the expense and inconvenience of hospitalization with secondary incapacity, excludes the possibility of a frequently sanguineous operative procedure, offers primary definitive therapy, and at the same time preserves the function of a physiologically desirable gland.

#### References

1. Mathieu, A.: Office treatment of Bartholin's abscess or cyst. *Am. J. Surg.* **36**:219 (April) 1937.
2. Catell, R. B.: Note regarding removal of Bartholin's cyst. *S. Clin. North America.* **22**:837 (June) 1942.
3. Schauffer, G. C.: Quick, easy, efficient treatment of Bartholin's cyst and abscess. *J.A.M.A.* **102**:839 (March 17) 1934.
4. Davies, J. W.: Bartholin cyst; simple method for its restoration to function. *Surg., Gynec. and Obst.* **86**:329 (March) 1948.
5. Crile, George, Jr.: Definitive ambulatory treatment for pilonidal cysts. *Surgery* **24**:677 (Oct.) 1948.