

INTRACRANIAL OPERATIONS IN THE SITTING POSITION *

W. JAMES GARDNER, M.D.

During the last four years, a majority of the major intracranial operations at the Cleveland Clinic have been performed with the patient in the sitting position. This position has been found to possess many very definite advantages and also certain disadvantages. The idea of placing the patient in the erect posture for craniotomy is not new, and no claim is made for originality in any of the observations to be described. Frazier¹ early appreciated the advantages of the erect posture in operations on the sensory root of the fifth nerve. In several of his communications on trigeminal neuralgia he has stated that in this position there is less bleeding, the patient requires less ether, and the field of operation is on a level with the eyes of the operator, which facilitates exposure. For many years de Martel² has advocated having the patient in the sitting position during intracranial operations. He has employed this method since 1911, and has found that elevation of the patient's head decreases hemorrhage and aids respiration. On account of the greater likelihood of syncope in this position, he favors local anesthesia, which allows earlier recognition of the syncope which can be combated by lowering the patient's head.

In 1930, I began to place the patient in the sitting position for operations on tumors of the cerebellum, with the hope of overcoming certain difficulties, such as the respiratory embarrassment, and also the occasional tendency for the cerebellum to bulge through the craniotomy opening. The cerebellar head rest was attached to the arms of a dental chair, and several operations upon the cerebellum were carried out in this position. After a trial extending over several months, the advantages were so obvious that alterations were made in the head rest so that supratentorial tumors could be attacked with the patient in the same posture. In the last three years, I have reverted to the use of the prone position in only one case of suboccipital craniectomy. This patient was a woman, aged seventy-six years, whose ninth nerve was sectioned for glossopharyngeal neuralgia.

From our experience with this position, its advantages over the horizontal position may be enumerated as follows: (1) There is a reduction of intracranial venous pressure resulting in diminished bleeding, lowering of intracranial pressure and a lessened tendency to cerebral oedema consequent to operative manipula-

*Reprinted by permission from *Annals of Surgery*, 101:138-145, January 1935.

tions; (2) freedom from respiratory embarrassment; and (3) easier access to the patient for the anesthetist, as well as the operator. The disadvantages of this position are: (1) occasionally a patient goes rapidly into profound shock; and (2) the lowered intracranial venous pressure may favor air embolism, if a dural sinus is opened.

The reduction of the intracranial venous pressure, of course, is the result of the improvement in venous return which occurs on elevation of the head. It is due partly to the pull of the column of blood from the brain to the right side of the heart and partly to a lowered intrathoracic pressure. To anyone who has observed

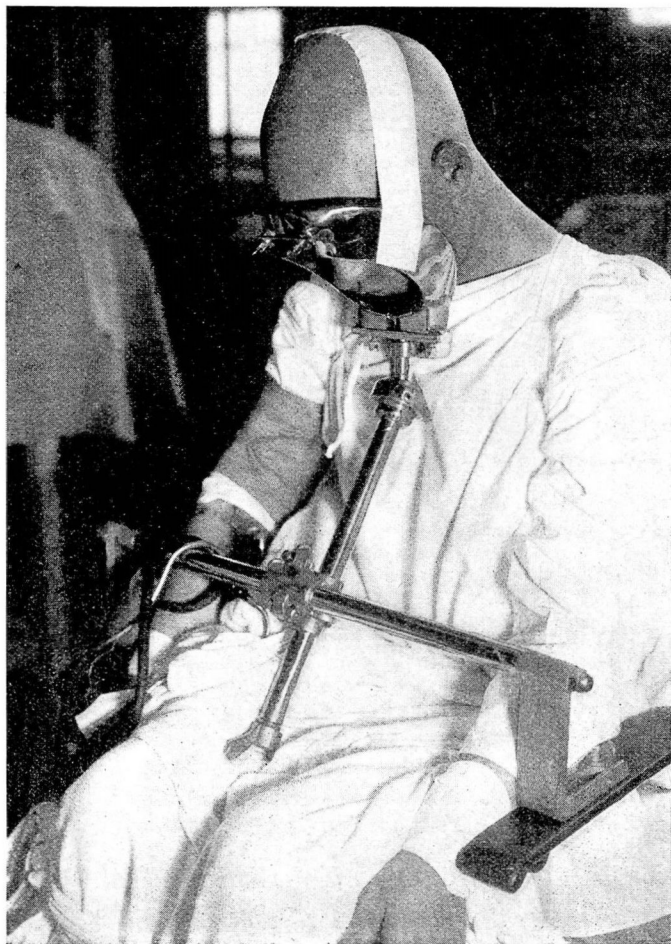

FIG. 1.—Patient in position for a suboccipital craniectomy or cervical laminectomy. The head rest is lined with sponge rubber and is adjusted to the contour of the patient's face.

INTRACRANIAL OPERATIONS IN THE SITTING POSITION

operations with the patient in the erect, as compared with the horizontal position, the diminution of venous bleeding and the ease of its control in the former cannot help but be apparent. The reduction of the intracranial pressure is the most striking and significant advantage gained by elevation of the patient's head. This, of course, is secondary to the reduction of the intracranial



FIG. 2.—The exposure for resection of the fifth and ninth cranial nerves and second and third cervical posterior roots on the right side for relief of pain from carcinoma. Illustration shows the ease of exposure of the eighth nerve and angle. Combined hemisuboccipital craniectomy and hemilaminectomy.

venous pressure. This reduction in pressure can be measured by performing a cisternal or ventricular puncture and recording the pressure in the same patient in both the horizontal and sitting positions. If the intracranial pressure is below 150 millimetres of water in the horizontal position, it will be subatmospheric in the erect posture. If the intracranial pressure is greatly increased in

the horizontal position, it will be found to be at least 200 millimetres lower than when the patient is sitting erect.

When the patient is sitting upright, except in the case of severe intracranial pressure, there is no significant herniation of the brain when the dura is opened. With this reduction of herniation, intracranial exploration can be more thorough and extirpation of the tumor is rendered more simple. Because the tumor can be removed with less trauma and less retraction, immediate cerebral œdema is reduced to a minimum. In no case of cerebral tumor in which the operation was performed with the patient in the erect posture, has it been necessary to sacrifice the bone flap on account of herniation of the brain.

As de Martel has stated, "the sitting position favors easy respiration and is the position all patients instinctively assume when respiration is labored." Certain patients who tend to breathe stertorously when lying horizontally, breathe quietly and without effort in the sitting posture, and also the head can be flexed more without a tendency to stertorous breathing. This is a point of considerable importance in the attack on a cerebellar tumor.

When a brain tumor is removed, a procedure which is likely to be slow and tedious, it is decidedly advantageous that the various members of the operating team are comfortable and have easy access to the patient. This is especially true of the anæsthetist. With the patient in the sitting position, the anæsthetist is not required to sit under a tent of draperies, and therefore has a better opportunity to observe the patient's condition and to minister to his needs. In addition, the patient's arms are available for intravenous medication or for transfusion, should this prove necessary.

In a series of fifty-six suboccipital craniectomy operations, no distinct disadvantages of the sitting position have appeared. These patients have shown no fall in blood-pressure which could not be combated by hypodermic stimulation or intravenous fluids. In operations on the cerebral hemispheres, however, the story is different. The sitting position, of course, would not be desirable or feasible in operations on tumors arising from the floor of the anterior or middle cranial fossæ or from the sellar region. With the operative field in these situations, it would be necessary to lift the brain away from the lesions and against the force of gravity. The sitting position, therefore, is not employed when a tumor is suspected on the inferior surface of the cerebral hemisphere. In the past four years, seventy-eight craniotomies other than suboccipital, have been performed with the patient in the sitting

INTRACRANIAL OPERATIONS IN THE SITTING POSITION

position, as compared with 147 similar operations using the supine position. In this series of seventy-eight cases, a rapid and profound shock appeared in two instances and was accompanied by visible air emboli in the cerebral vessels. Both of these patients were past sixty years of age, had cerebral arteriosclerosis and

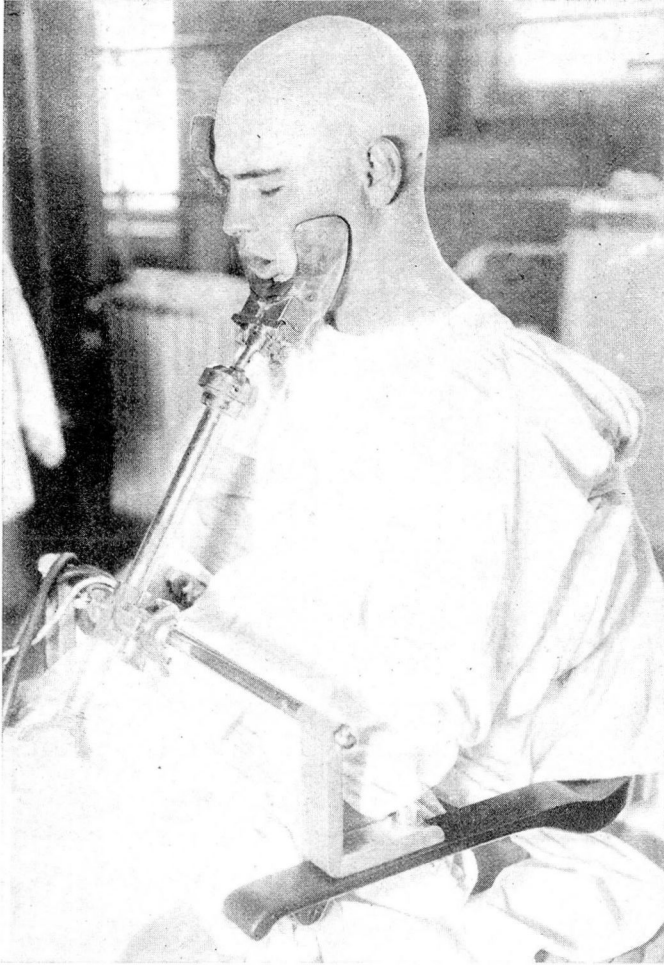

FIG. 3.—Position for frontal or lateral craniotomy. After the field is prepared and the line of the incision marked, the head is fastened to the head-rest with a strip of adhesive.

arterial hypotension, and the lesion in each case was a parasagittal meningioma. In one of these, the sudden syncope undoubtedly contributed to a fatal termination. This patient also had severe asthma and emphysema. Since these experiences, I have not em-

FIG. 4.—Removal of a left parasagittal meningioma. With the patient in the sitting position, the brain retracts by its own weight.

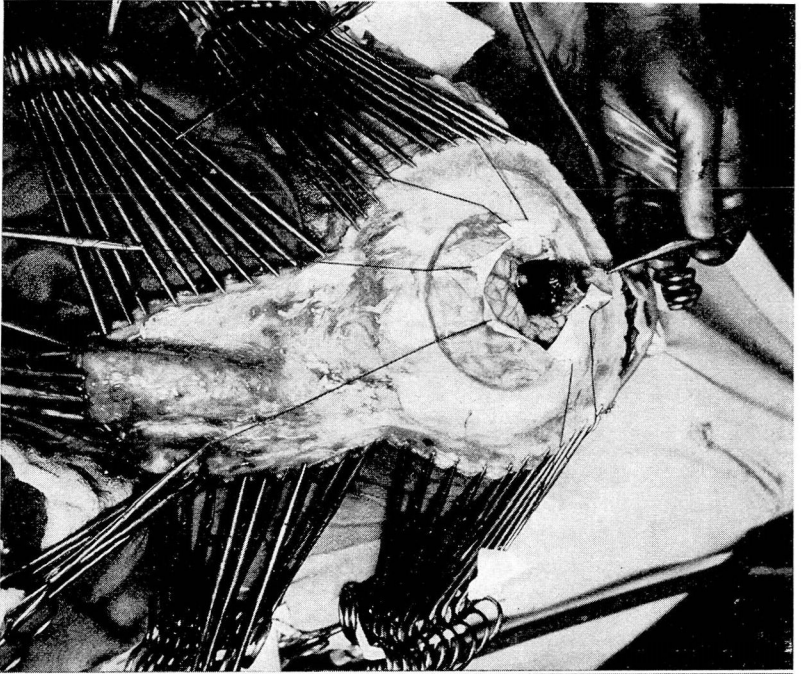
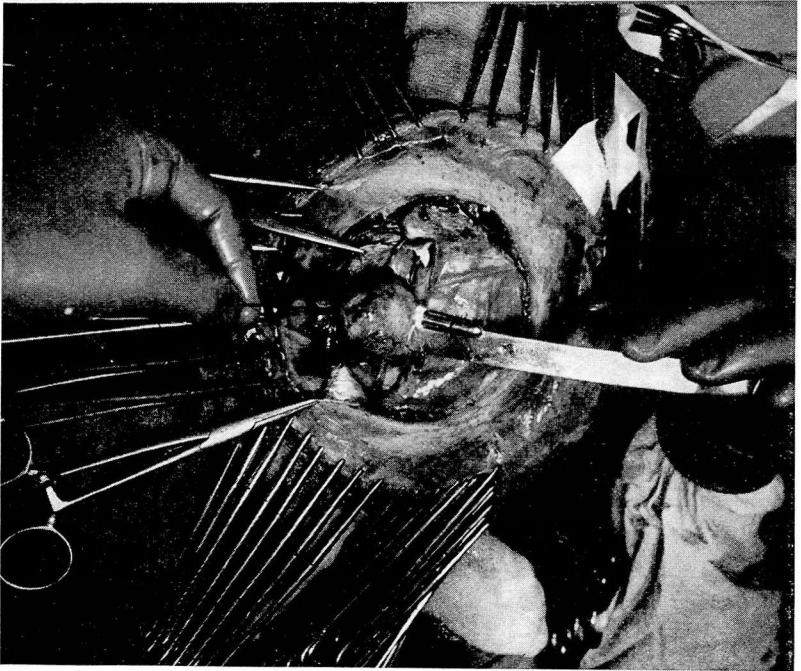


FIG. 5.—Removal of a similar, though smaller, tumor from the right parasagittal region with the patient in the horizontal decubitus. The bulging brain is being retracted from the tumor.



INTRACRANIAL OPERATIONS IN THE SITTING POSITION

ployed the sitting posture in operations upon elderly or arteriosclerotic subjects, particularly when there is an associated hypotension.

De Martel stresses the advisability of employing local anæsthesia when the patient is in the sitting posture, in order to permit earlier recognition of threatened syncope. When this complication occurs, he immediately lowers the head. The chair which he employs permits rapid lowering of the head during the course of an operation. Thus far, I have not been able to incorporate this desirable feature in our equipment. Given a chair with this feature, I believe that the last valid objection to this position would be eliminated.

I do not agree with de Martel's dictum regarding the necessity for local anæsthesia, although it is perfectly true that with local anæsthesia syncope is more readily recognized. But there can be no question also that general anæsthesia, probably by elimination of the psychical factor, reduces very materially the incidence of syncope, and I feel that this reduction in frequency by far outweighs the advantage of its earlier recognition under local anæsthesia. The importance of the psychical factor in syncope is well illustrated by its quite frequent occurrence in encephalography under local, as compared with its rare occurrence under general anæsthesia. Since 1930, I have preferred to use avertin in cranial surgery. In preparation, the patient receives a hypodermic injection of codeine and scopolamine one hour before operation, followed forty minutes later by the instillation into the rectum of 50 to 100 milligrams of avertin per kilo of body weight.

The objection has been raised that the sitting position in craniotomy may favor the occurrence of post-operative hæmorrhage. In the fifty-six cases of suboccipital craniectomy, a post-operative hæmorrhage was not detected clinically or at necropsy in any case. There was likewise no post-operative hæmorrhage in fifty-one operations for resection of the sensory root of the fifth nerve by the temporal approach. Following seventy-eight craniotomies with the patient in the sitting position, a post-operative hæmorrhage occurred in three instances. This incidence of hæmorrhage is considerably higher than in the series of 147 craniotomies carried out with the patients in the horizontal position, in which there was only one post-operative hæmorrhage. On analyzing these cases, however, it was found that post-operative hæmorrhage occurred only in cases of jacksonian epilepsy in which there was no increase in intracranial pressure. In my experience, this type of case is notorious for its high incidence of

post-operative hæmorrhage. Hence the more frequent recording of this complication after operations with the patient in the sitting, as compared with the horizontal position in our series, might be explained by the fact that most patients with jacksonian epilepsy are operated upon in the sitting position. I do not believe that the erect posture during operation favors the occurrence of post-operative hæmorrhage.

The sitting posture is employed routinely in encephalography and in ventriculography. It has also been used in twenty-nine cases of laminectomy on the cervical or upper dorsal spine and in nine operations for removal of the cervicodorsal sympathetic ganglia by the Adson approach. This latter operation, in my experience, is definitely simplified by this technic. In the case of laminectomy, the position is of great value, provided a general anæsthetic is used. In cordotomy when performed under local anæsthesia, in this position, the patient frequently experiences a syncopal attack after the dura is opened. This is caused by the ascent of air into the cerebral subarachnoid spaces. Under general anæsthesia, no significant change occurs when the dura is opened.

The value of the sitting position was strikingly demonstrated recently in the case of a patient with a meningioma at the level of the foramen magnum. This patient had a quadriplegia, the diaphragm was paralyzed and the intercostal muscles were very weak. For this reason, the respirations were shallow and rapid and there was mild cyanosis. This patient obviously would not have tolerated the prone position, but she withstood the operation splendidly in the sitting position and had an uncomplicated convalescence.

SUMMARY AND CONCLUSIONS

The sitting position of the patient, combined with avertin anæsthesia, is recommended for operations on the cerebellum. This position results in (1) a diminution in bleeding, (2) a lowering of intracranial pressure, (3) a lessened tendency to immediate cerebral œdema, (4) an improved respiratory exchange, and (5) it also facilitates access to the patient, particularly by the anæsthetist. This position is not recommended for operations on tumors about the sella turcica or on the inferior surfaces of the cerebral hemispheres. In other cerebral tumors, the position is recommended with reservation because of the tendency for an occasional patient to go into prompt and profound shock. The position has distinct advantages in cervical and upper dorsal laminectomy and in excision of the cervicodorsal sympathetic ganglia by the Adson approach. It does not predispose to post-operative hæmorrhage.

INTRACRANIAL OPERATIONS IN THE SITTING POSITION

REFERENCES

1. Frazier, C. H., and Gardner, W. J.: The Radical Operation for the Relief of Trigeminal Neuralgia. *Surg., Gynec., and Obstet.*, vol. 47, pp. 73-77, 1928.
2. de Martel, T.: Surgical Treatment of Cerebellar Tumors: Technical Considerations. *Surg., Gynec., and Obstet.*, vol. 52, pp. 381-385, February, 1930.