

SPECIAL POINTS IN THE TECHNIQUE OF THYROID SURGERY

ROBERT S. DINSMORE, M.D.

A review of the literature on the technique of thyroid surgery brings one to the conclusion that many variations of technique exist and that all fulfill the requisites for the satisfactory removal of the thyroid gland. After all, a satisfactory technique is one which can be carried out within a reasonable length of time under some form of light anesthesia or analgesia augmented by local anesthesia; one in which the proper amount of the thyroid gland is removed without injury to the recurrent laryngeal nerves or to the parathyroid bodies; one in which

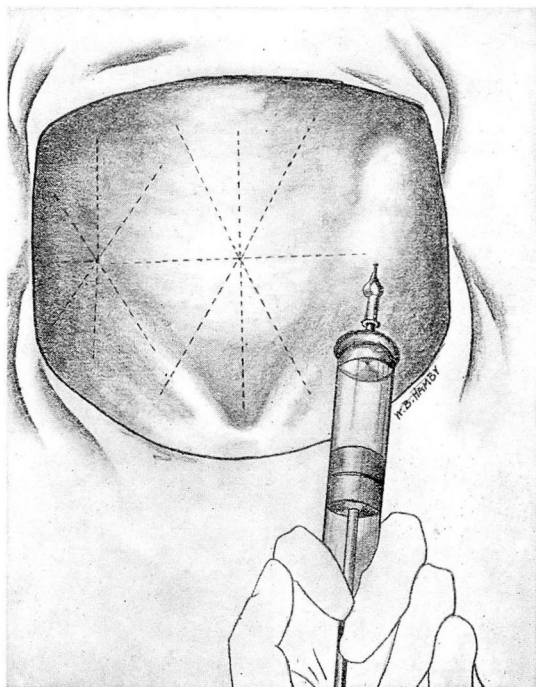


FIGURE 1.—Direction of infiltration with three-fourths per cent novocain. No attempt is made to inject beneath the fascia at the time.

satisfactory results are obtained from a cosmetic standpoint; and above all, one which brings about the cure of the patient.

The infiltration of novocain is carried out in three steps. The skin and subcutaneous tissue is first well blocked over a wide area. In this step, no attempt is made to infiltrate beneath the cervical fascia or in the preglandular muscles.

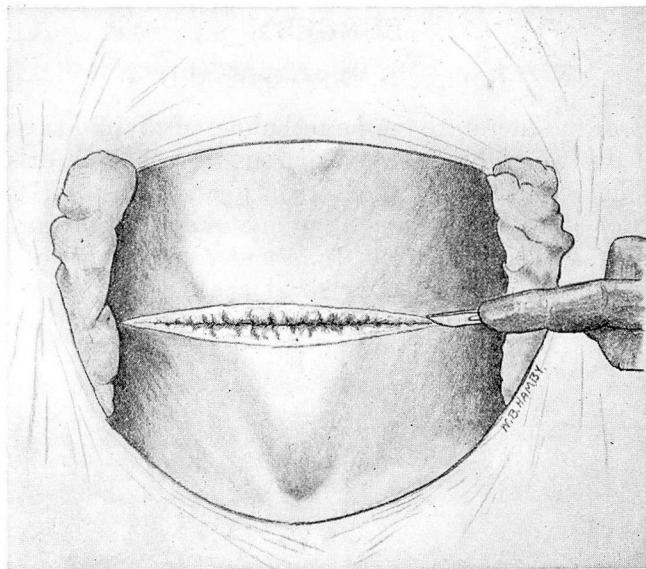


FIGURE 2.—Straight transverse incision across neck. The dissection is carried through the subcutaneous tissue and the platysma muscle down to the cervical fascia, thus making a full-thickness skin flap.

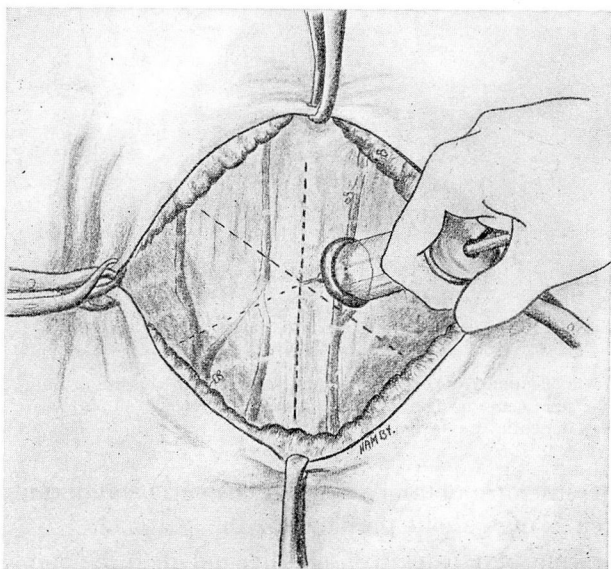


FIGURE 3.—After the dissection of the skin flaps, three-fourths per cent novocain is injected beneath the cervical fascia and into the preglandular muscles.

SPECIAL POINTS IN THE TECHNIQUE OF THYROID SURGERY

For several years I have used a transverse incision, (Richter¹) which is usually at a point about midway between the suprasternal notch and the cricoid cartilage. In my experience, this incision has produced the most satisfactory type of scar. Often, in making an elliptical inci-

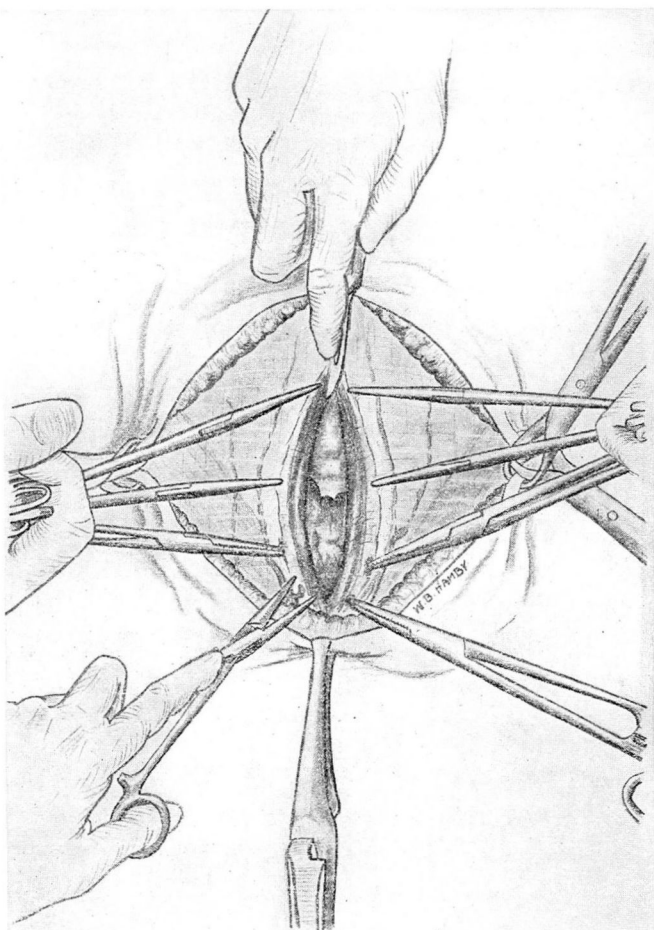


FIGURE 4.—Longitudinal incision through the fascia, pre-glandular muscles and capsule of the gland. This dissection is carried from the level of the cricoid cartilage well down into the suprasternal notch. With a long incision it is not necessary to divide the pre-glandular muscle transversely.

sion, one is surprised to find after the operation, that the ellipse is exaggerated because, at the time of operation the head was in extension and when the head drops down, the curve of the incision is increased. Also, in the elliptical incision, occasionally one is surprised to find that one end of the incision is slightly higher than the opposite one, while

in the transverse incision, a slight ellipse is produced when the head drops down while this does not occur with the straight incision.

The incision is carried through the skin, the subcutaneous tissue, and the platysma muscle directly down to the cervical fascia. The upper

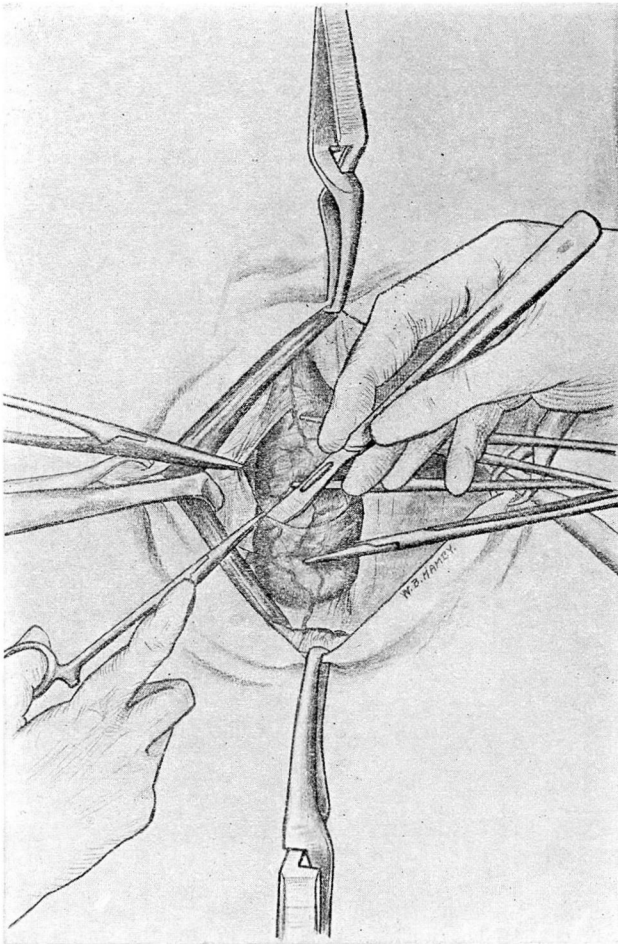


FIGURE 5.—The capsule of the gland is dissected cleanly from its surface laterally to the level at which the gland is to be divided. None of the capsule is removed.

skin flaps then are dissected up to the level of the cricoid cartilage, giving a thick skin flap. The dissection of the lower flap is carried well down to the suprasternal notch. These dissections must be carried a little farther than was the former practice, inasmuch as the preglandular muscles are not divided transversely and the linear incision in the

SPECIAL POINTS IN THE TECHNIQUE OF THYROID SURGERY

midline through the fascia and preglandular muscles is carried from the cricoid to the suprasternal notch.

The cervical fascia and preglandular muscles are then infiltrated with novocain. The capsule of the thyroid is exposed and opened in the same line with the fascia and preglandular muscles. Care is taken that

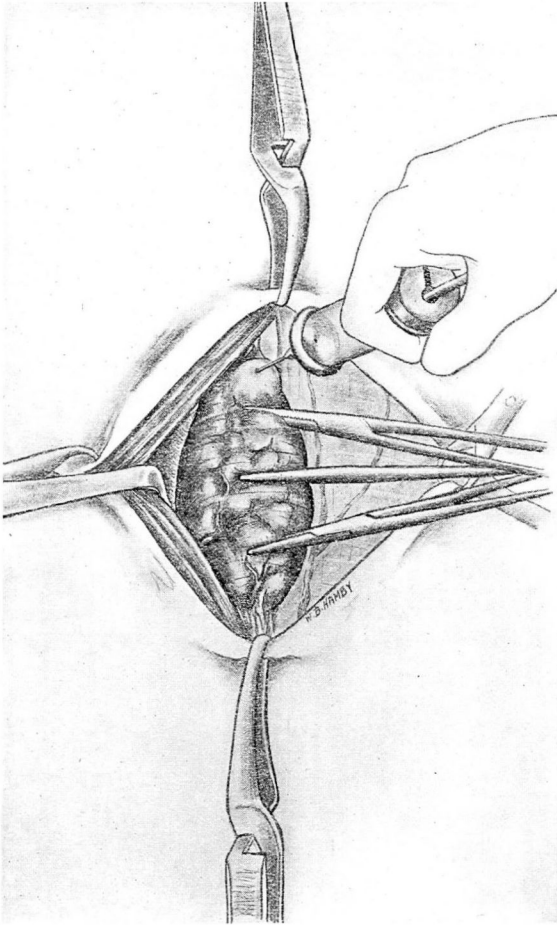


FIGURE 6.—After the gland has been exposed, the third infiltration is made and hemostat is applied for traction.

the capsule is dissected cleanly and that none of it is removed during the operation. I feel that this is extremely important in the prevention of parathyroid tetany, as I am certain that many parathyroid glands have been removed because the capsule was not dissected cleanly from the thyroid gland. After the gland is thus exposed, ordinary hemostats are used to elevate it. I have used various types of goiter clamps,

all of which work very well in the adenomatous and colloid glands, but all of which also have a tendency to break through in the extremely friable and hyperplastic glands. These hemostats are inserted just within the true capsule of the gland.

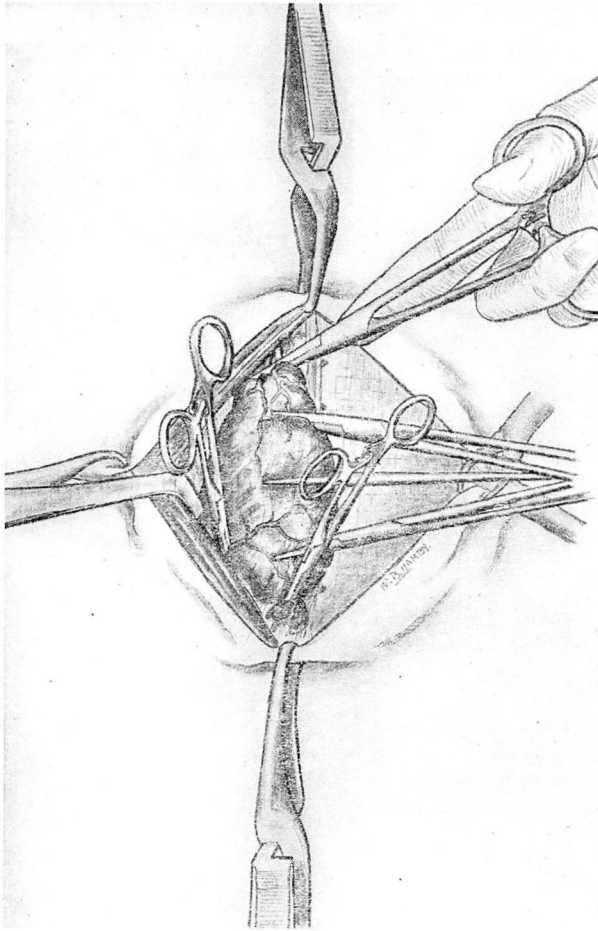


FIGURE 7.—Application of three pilot hemostats. The upper pole is dissected free and lifted up, the hemostat always being directed from within outward. The lateral vessels are caught with the second hemostat. The inferior pole then is caught, the clamp being applied so as to take up some thyroid tissue with it and to have the clamp standing erect.

After the gland has been exposed, the third step of the infiltration is carried out with 10 or 15 cc. of novocain which is injected into the gland itself. The major portion of this is injected at the upper pole, because most of the reflexes of pain apparently are transmitted through the upper pole and, therefore, this should be infiltrated carefully if the

SPECIAL POINTS IN THE TECHNIQUE OF THYROID SURGERY

operation is performed under very light analgesia or local anesthesia. Retractors then are placed inside the cervical fascia and preglandular muscles, and the whole right lobe, if possible, is exposed. The ideal exposure is one in which you can see the superior thyroid vessels, the lateral thyroid vein, and the inferior thyroid vessels.

I have felt that it is quite important that three pilot hemostats be applied before any actual dissection is carried out. These should be applied accurately because many injuries to the recurrent laryngeal nerves can be avoided if care is used in this first step of the actual thyroidectomy. The upper pole of the thyroid ordinarily lies opposite the larynx, close to the point where the terminal branches of the recurrent laryngeal nerves enter the larynx. If the upper pole is separated carefully and the clamp applied from the inside out, these branches cannot be caught in the hemostat. On the other hand, if a clamp is placed from the outside without freeing the upper pole, it is very easy to injure one of the terminal branches by catching the muscle of the larynx with the tip of the hemostat. A second hemostat then is applied to the lateral vein of the thyroid, which is at the outer surface at the juncture of the middle and lower thirds of the gland. Hertzler² has emphasized the importance of this clamp, stating that the cleavage often is lost at this point because of the fact that the fascia planes divide here, one sheath going over the carotid and the other to the gland. Guthrie³ routinely ligates this vessel first. The third clamp then is applied at the inferior pole. I make it a practice to leave some thyroid tissue at this point, and the clamp is so placed that after it has been applied, it will stand erect in the wound. In my own hands, a great deal of the bleeding which is encountered in thyroid surgery can be lessened if these three pilot clamps are accurately and consecutively applied. The poles and lateral thyroid fascia can then be divided and an incision made along the lateral posterior border at the point at which the gland is to be divided. This incision is carried only for a short distance into the gland—approximately 1 cm. After this has been done, it will be noted that the gland can easily be lifted forward, and at this point the gland then is turned outward, and the dissection carried from the tracheal side. Sistrunk⁴ always advocated this procedure, and it has been of great assistance to me. The clamps can then be placed nearly transversely above the trachea into the gland, and the dissection carried from that point outward. In some cases, it may be advisable to split the isthmus first, before starting the dissection on the outside, but ordinarily this is not necessary, and I prefer always to place the pilot clamps and to begin the dissection from the outside of the gland first. In carrying the dissection from the trachea outward, the clamps thus are placed almost transversely, and this eliminates the possibility of having to insert the hemostat downward toward the tracheo-esophageal

groove, since the transverse application actually is away from the groove. This, of course, is a common site for injury to the recurrent laryngeal nerve.

After the gland has been removed, all ligations are performed with fine catgut ties. I know from actual experience that sewing in the bed

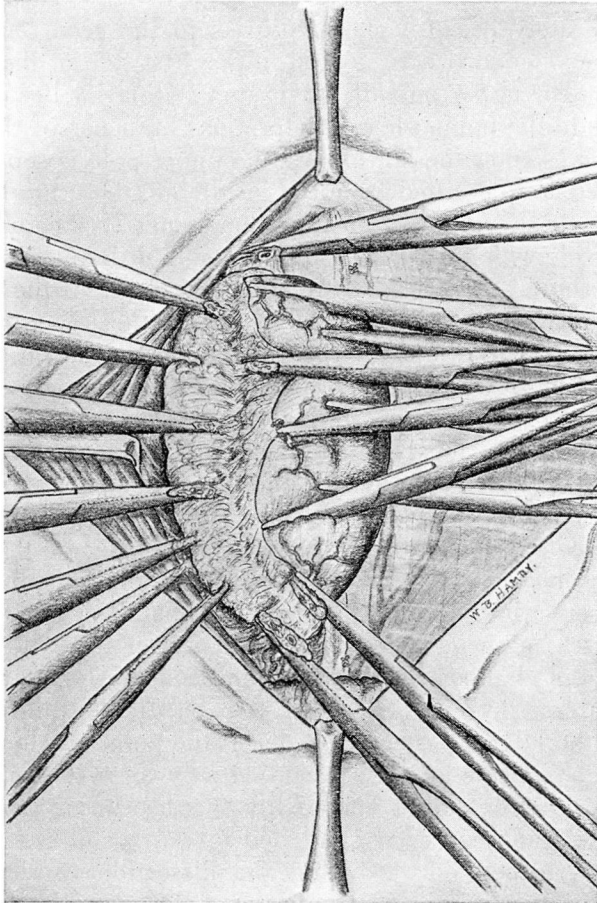


FIGURE 8.—Dissection of gland. After the points within the primary clamps have been divided, the dissection is carried inward from the outside of the gland for about one-third of its extent.

of the gland is a dangerous procedure and if possible, it should not be done. I prefer to ligate the upper pole with catgut suture, inserting it in the same direction as that in which the clamps were applied. After the hemostasis is complete, the same procedure is carried out on the opposite side. There usually is very little difficulty in mobilizing the

SPECIAL POINTS IN THE TECHNIQUE OF THYROID SURGERY

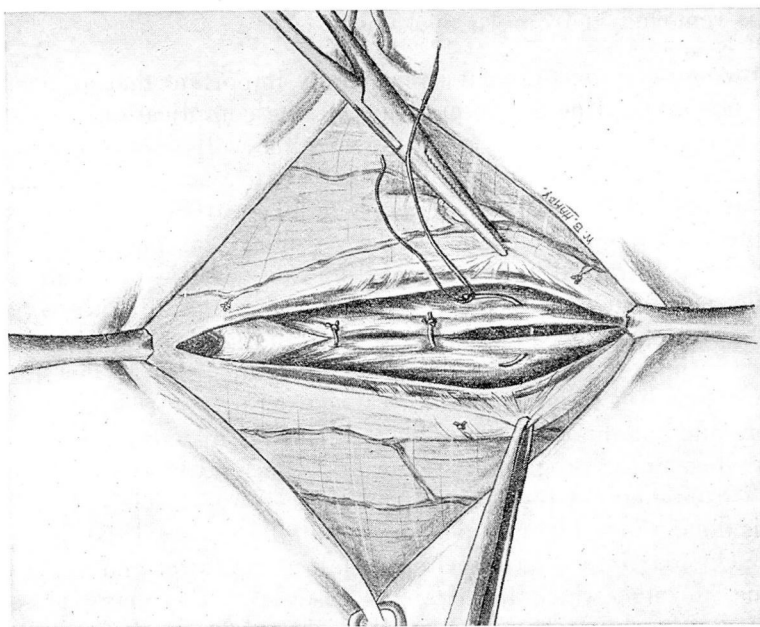


FIGURE 10.—The capsule is closed with interrupted sutures of fine catgut.

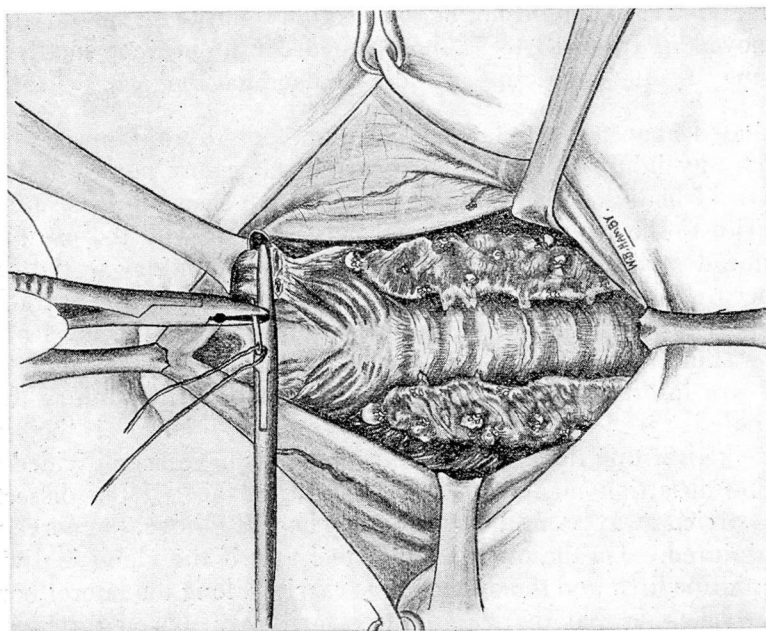


FIGURE 9.—Ligation of the upper pole with double catgut ligature. The pole is lifted up and the ligature always passed from within outward.

small rubber tissue drain, which is placed beneath the muscles and which is removed in from 18 to 24 hours.

Following thyroidectomy, it is extremely important that an accurate closure be done. One of the most distressing complications is a small adhesion or an adherent scar which moves with swallowing. The patient may, or may not complain of this, but it is always noticed by friends and relatives. I have dissected out a number of these postoperative adhesions and in most instances I have found that the pregladular muscles have retracted from the midline and that the cervical fascia was adherent to the trachea. The correction of this oftentimes is not a simple procedure, because a wide dissection may be necessary before one can again free the pregladular muscles and recover the trachea. In the closure, it is important that all the structures be re-approximated in layers and for this reason interrupted sutures first are placed in the capsule, then in the pregladular muscles, and finally a running suture of fine chromic catgut re-approximates the cervical fascia. I feel that if this is done, the number of postoperative adhesions will be extremely small. Ordinarily, a small opening is left at the lower end of the incision line, through which the drain is inserted. For many years we have used skin clips to close the full thickness flaps. It is important that these clips be placed accurately and at right angles to the incision line. It is a common error to apply these clamps to the side so that they appear at many different angles when the incision line is closed completely. They should not be applied too tightly and should always be removed in from 48 to 72 hours in order to prevent small scars which may result if the clips are left in place too long.

As stated above, a satisfactory technique for thyroid surgery must preclude any injury to either the recurrent laryngeal nerves or to the parathyroid bodies. In my own hands, I have seen the least number of injuries to the recurrent laryngeal nerves occur with the use of the technique described. The most common sites for injury to the nerve have been at the superior pole, the inferior pole, and in the tracheo-esophageal groove at about the middle point between the level of the inferior and superior poles. If the superior pole is free, and if the clamps are inserted from within outward, I believe that injury to the upper pole is rare. Injury at the inferior pole also is rare if the hemostats are kept within the gland. After the poles have been divided and a shallow insertion made along the lateral surface, if the dissection then is carried away from the tracheo-esophageal groove, the nerve will not be injured. On the other hand, I feel that if the gland is divided in the midline first, and the dissection is carried along the lateral border of the trachea so that the clamps necessarily are placed through the tracheo-esophageal groove, many injuries to the nerve will result. In

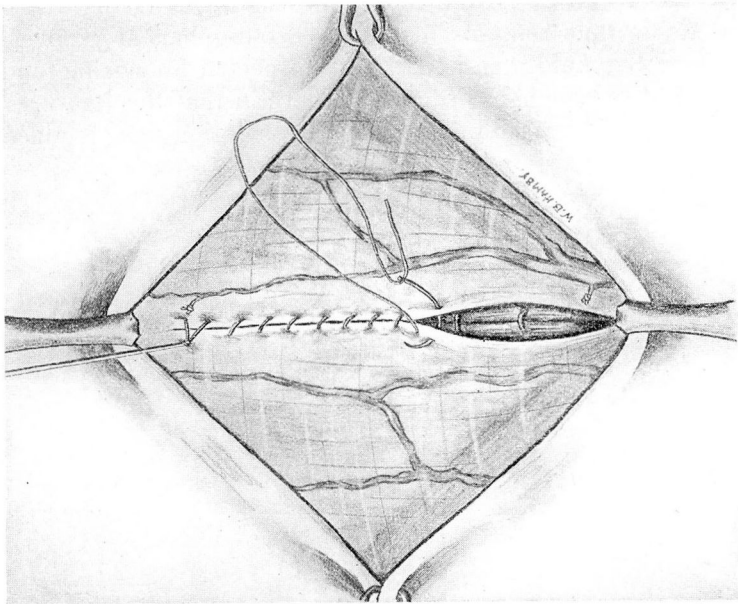


FIGURE 12.—Closure of fascia with fine catgut running suture. A small opening is left in the lower third for drain.

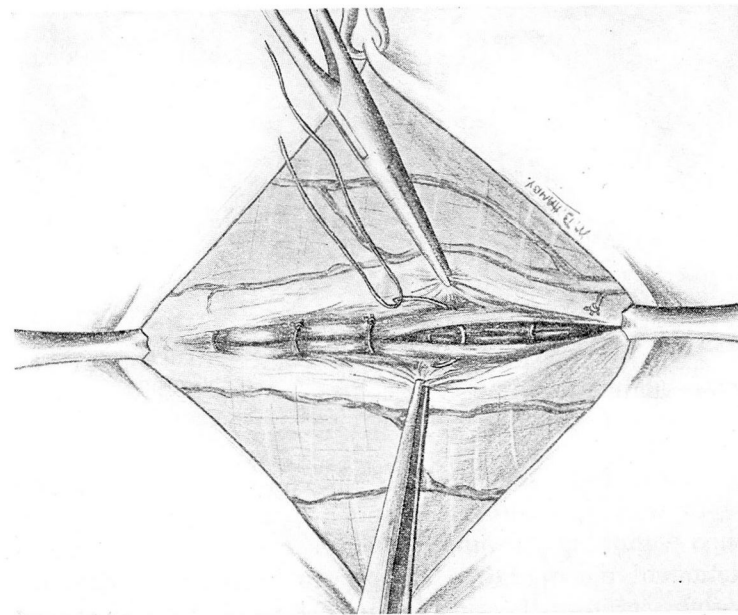


FIGURE 11.—Closure of preglandular muscles with interrupted sutures.

second lobe, inasmuch as the isthmus is divided and the pilot clamps can readily be applied. After such a procedure, a triangular piece of thyroid tissue thus remains in the tracheo-esophageal groove, and the whole operative field then is carefully inspected for oozing, and the patient is asked to cough in order to be certain that the ligatures are securely applied. A small amount of saline solution then is placed in

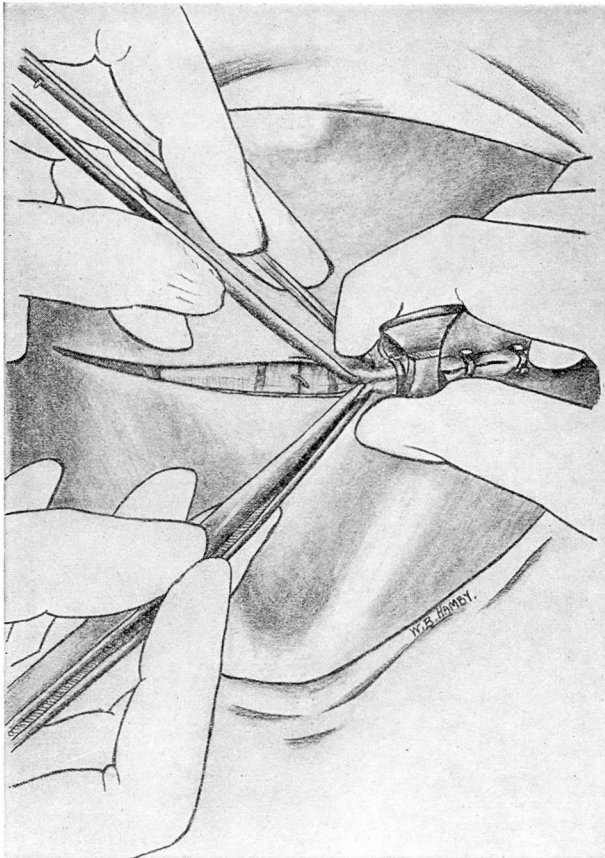


FIGURE 13.—Closure of skin with clips. It is essential that the clips be inserted at right angles to the incision line. To accomplish this, they must be applied from directly above the incision and not from the side as this invariably twists the clip.

the wound. At various times I have tried to close these wounds without drainage. In well encapsulated adenomas, this occasionally can be accomplished without any trouble; however, even though the wound at the completion of the operation appears to be perfectly dry, almost invariably some serum will collect in the neck which must be evacuated. Therefore, it is best to use some type of simple drainage, such as a

SPECIAL POINTS IN THE TECHNIQUE OF THYROID SURGERY

carrying the dissection down along the trachea, there are many small blood vessels which may be in close approximation to the nerve.

I also feel that very few cases of postoperative parathyroid tetany will occur if the capsule is dissected cleanly from the thyroid, care being taken to leave as much of the posterior border of the thyroid as possible. In our own pathological laboratory, Dr. Graham has found from examination of specimens removed at operation, that the most frequent site of removed parathyroid glands is on the lateral inferior border of the gland. Many writers, including Millzner,⁵ Lahey,⁶ and Terry and Searls⁷ have called our attention to the high incidence of parathyroid bodies which lie on the anterior surface of the gland.

The last decade has witnessed a marked reduction in the mortality from thyroid surgery. This is due to the use of Lugol's solution, to more careful and longer preoperative preparation, and to divided operations. Little emphasis has been placed on the morbidity from thyroid surgery, which in most instances can be lessened by a careful and meticulous technique.

I am indebted to our former Resident in Neurological Surgery, Dr. W. B. Hamby, for the preparation of the illustrations, and to the W. B. Saunders Company, Philadelphia, for permission to reprint them from "Diagnosis and Treatment of Diseases of the Thyroid Gland" by George Crile and Associates, 1932.

REFERENCES

1. Richter, H. M.: Thyroidectomy. *Surg. Gynec. and Obst.* 49:67-75, July, 1929.
2. Hertzler, A. E.: Technique for Thyroidectomy. *Surg. Gynec. and Obst.* 47:225-234, 1928.
3. Guthrie, D.: Thyroidectomy Technique; the Postoperative Care of the Toxic Goiter Patient. *Am. J. Surg.* 6:631-633, 1929.
4. Sistrunk: Personal communication.
5. Millzner, R. J.: The Occurrence of Parathyroids on the Anterior Surface of the Thyroid Gland. *J.A.M.A.* 88:1053-1055, 1927.
6. Lahey, F. H.: Transplantation of Parathyroids in Partial Thyroidectomy. *Surg., Gynec. and Obst.* 42:508-509, 1926.
7. Terry, W. I., and Searls, H. H.: Parathyroid Preservation. *J.A.M.A.* 89:966-967, September 17, 1927.