

PROSTATE GLAND BIOPSY

EUGENE F. POUTASSE, M.D.

Department of Urology

THE incidence of cancer of the prostate gland among men who have symptoms of bladder neck obstruction is about one out of five. The actual incidence of cancer is higher because many men are seen with symptoms unrelated to the urinary tract, such as bone pain, or who have evidence of the tumor without symptoms. It is the third most common cancer in men, exceeded only by cancer of the skin and alimentary tract in frequency of recognition.

The chief methods by which a physician discovers prostatic cancer are rectal palpation of the gland, serum acid phosphatase determination, and roentgenographic study of the urinary tract and skeleton. These are satisfactory when the tumor has spread widely beyond the prostate. In this paper methods of biopsy for establishing the diagnosis when cancer of the prostate gland is suspected or when it is desirable to corroborate the clinical diagnosis of extensive cancer will be discussed. The actual diagnosis of cancer is made by microscopic definition, preferably on a block of tumor tissue. Under study is the cytologic examination of prostatic secretion for exfoliated tumor cells,¹ which requires a great deal of time and experience.

Methods of Biopsy

A. Perineal. Exposure of the prostate gland through the perineum permits biopsy of any area of the gland which has been suspected of malignancy on rectal palpation. This approach is particularly useful because more than 90 per cent of all prostatic neoplasms arise in the posterior lobe accessible to rectal palpation. The reason for biopsy of such suspicious areas is to offer the patient an opportunity by total prostatectomy for complete removal of an early cancer or assurance of the benign nature of the lesion.

Patients are selected for perineal biopsy chiefly on the basis of rectal findings of an area of nodularity and induration within the confines of the gland. The size of the gland means little because cancer has a development independent of benign enlargement. Evidence of metastasis on physical examination, roentgenographic study of the bones, or elevation of the serum acid or alkaline phosphatase are contraindications to operative perineal biopsy. A plain film of the pelvis will exclude prostatic calculi as the cause of induration within the gland. History of chronic prostatitis or genitourinary tuberculosis may influence the necessity for biopsy. Men who have a poor life expectancy from the age or health standpoint are not considered suitable candidates for perineal biopsy and possible radical prostatectomy. It is not suggested that every pros-

tate with slight irregularity should be biopsied. Many patients with prostatic irregularity not initially suggestive of cancer can be reexamined at intervals for change.

With the prostate exposed perineally, a suitable block of tissue is removed from the area under suspicion and submitted to the pathologist for frozen section. Frequently, cancer can be suspected when the fragment presents both induration and yellowish surface color. With the frozen section technic utilized by Dr. John B. Hazard² of the Department of Pathology, accurate correlation between rapid sections and later permanent sections has been attained. Interpretation of prostatic tissue by frozen section is generally considered difficult and unreliable, but use of a method providing differential staining and uniform results is of great value. A portion of each tissue block is used for frozen section and the remainder saved for permanent section. Freezing causes distortion of tissue and use of this second and unfrozen portion permits accurate interpretation of each sample.

With the presence of cancer confirmed by frozen section, the entire prostate gland is separated from the bladder and urethra and removed with adjacent portions of the bladder and genital tract, provided cancer has not spread beyond resectability into these structures. Failure to find cancer on the first frozen section necessitates additional biopsies of adjacent areas of the gland. If these are negative and there is no indication for enucleating obstructing prostatic tissue, the perineal incision is closed and the patient is usually out of the hospital within three to four days.

Over a two year period, 40 men were subjected to open perineal biopsy because of suspected early cancer. Twenty-two were proved to have benign conditions causing the induration. Chronic prostatitis and acinar hyperplasia are the main lesions simulating carcinoma. There were no complications among this group. Eighteen men of this group of 40 were found to have cancer. Of these 18, four were shown to have spread of the tumor into the bladder base, urethral bulb, or laterally, and therefore had biopsy only. Fourteen men had total prostatectomy, ten of whom are believed to have a good chance of complete removal of the cancer based on the pathologic examination of the prostate. The remaining four were found to have carcinoma at the line of excision from the bladder base, discovered only after removal of the gland.

The effect of estrogenic hormones prior to biopsy often leads to confusion. It has been generally accepted that prostatic cancer softens under the influence of estrogens. This is often true of suspected early lesions, making the selection of a proper area for biopsy difficult at operation. Not all malignant nodules soften, however. Figure 1 illustrates a section of a totally removed prostate from a man who was treated with estrogens for a year. The original nodular area did not change significantly in size or consistency during this time. It should be noted that estrogens did not alter the malignant appearance of the tumor microscopically.

The extent of prostatic cancer is best evaluated prior to estrogenic therapy. Alteration of the hardness of tumor spread beyond the prostate with such

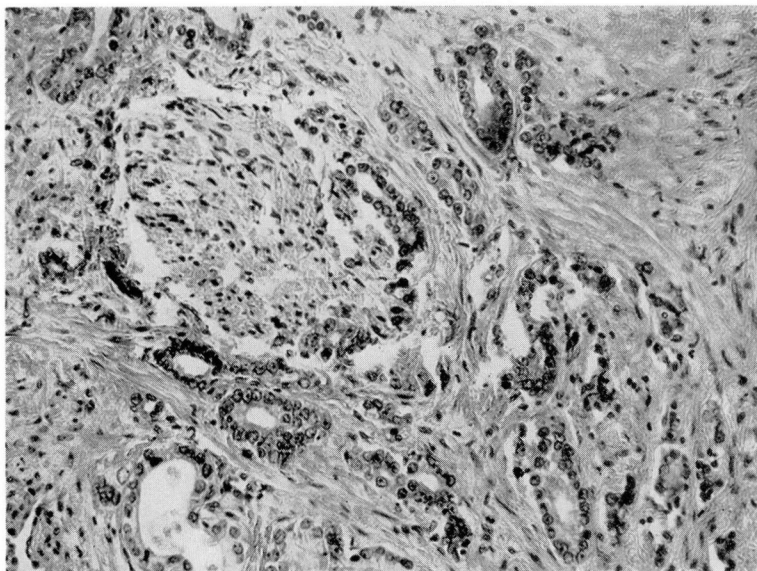


FIG. 1. Adenocarcinoma of prostate gland. Estrogen therapy for one year prior to total prostatectomy. Note perineural lymphatic involvement.

treatment may convey the impression that total prostatectomy will remove all cancer. Complete destruction of tumor cells with hormones does not occur. When a patient is fortunate enough to have a localized prostatic neoplasm diagnosed, the original plan of treatment is most important. Measures should be taken promptly for biopsy and extirpation of these potentially curable tumors.

B. Needle Biopsy. A practical method of securing prostatic tissue for pathologic examination without operation is often desirable to corroborate the clinical impression of cancer. The prostate is accessible to needle biopsy by puncture of the perineum, a finger in the rectum guiding the needle into the desired part of the gland. This is done under analgesia, often in conjunction with a cystoscopy. A Silverman needle is used, although there are several other types of prostate biopsy devices available. Several pieces of tissue 0.5 to 1. cm. long can be obtained from various parts of the gland or perineum. It has been noted that the most satisfactory specimens for biopsy are obtained when carcinoma is present; the least satisfactory when the prostate is small and fibrotic. No complications have arisen and there is no morbidity connected with the procedure. Should bleeding occur, digital pressure against the prostate and perineum for a few moments will suffice to control it.

During the same two-year period, 41 such needle biopsies were performed. Of 33 men who were considered clinically to have prostatic cancer, the diagnosis was confirmed by biopsy in 29. There were four false negative biopsies of men who had metastases demonstrable by x-ray or later operation. This illustrates

the well known fact that a negative biopsy is meaningless and should not influence the course of treatment under such circumstances. Eight men who had clinically benign prostate glands or metastatic tumor from other sites surrounding the genital structures, had prostate biopsy specimens which showed no evidence of malignancy.

For the purpose of perfecting and evaluating this method of needle biopsy, many patients with extensive metastases and abnormal serum phosphatase levels were utilized. Biopsy is not considered essential in such instances, however a satisfactory needle biopsy will provide sufficient tissue to distinguish adenocarcinoma from an undifferentiated carcinoma. This may be of some value in anticipating the result of estrogenic therapy. Biopsy corroboration of prostatic cancer has been particularly useful when metastases are present in an unusual form, as in the following case report:

A 53 year old man was admitted to the hospital, having been bedridden with back pain, weight loss and nausea. The pain in the dorsal area began three months previously. Physical examination disclosed only tenderness over the spine. Roentgen study revealed compression fracture of D6 and D8 vertebrae, and osteolytic metastasis in the right scapula, ribs and iliac bones. The acid phosphatase was 1.5 B.U. Sternal marrow biopsy disclosed adenocarcinoma; following this the prostate gland was reexamined. It was small with a firm upper border joining the bladder base, from which hard cords of tissue extended laterally to the walls of the pelvis. Needle biopsy of the prostate was performed disclosing adenocarcinoma (fig. 2). Immediate weight gain and relief of pain followed institution of estrogenic therapy.

Carcinoma of the prostate usually causes osteoblastic metastases and in this man the bone lesions were destructive. The serum acid phosphatase is elevated in approximately two thirds of all patients with osseous metastases of prostatic origin;³ serum acid phosphatase value of 1.5 B.U., such as in this case, is not considered abnormal.

C. Transurethral Biopsy. Since most prostatic neoplasms develop in the posterior part of the gland, transurethral resection often fails to go deep enough to secure representative tissue from this portion. Unless there is evidence of pathologic change or tumor extension around the vesical neck or into the prostatic urethra cystoscopically, biopsy by this means is usually inadequate. Its usefulness should not be overlooked under appropriate circumstances such as the following case:

A 35 year old man entered the hospital with chills, fever, dyspnea, and abdominal masses of one month's duration. One episode of acute urinary retention occurred followed by frequency and urgency. There were rales in both lungs, a large spleen, and an enlarged firm right lobe of the prostate gland. Chest x-ray showed patchy infiltration of both lungs. Abdominal film showed localized inflammatory changes in the 12th vertebral body, and a large splenic shadow with displacement of the left kidney downwards. The urogram revealed normal kidneys but the bladder base was indented, consistent with a large prostate. The hemoglobin was 9.8 Gm. per hundred cubic centimeters; urine was loaded with pus cells, red blood cells, and showed albumin; it was sterile on culture. The urine, gastric washings, and sputum were all negative for acid fast bacilli. PPD. was negative on first strength but positive on second strength. Cysto-

scopy revealed elevation of the posterior commissure; several pieces of tissue were removed from this area with the resectoscope. These showed active caseating tuberculosis.

The differential diagnosis in this man was between Hodgkin's disease and tuberculosis. Transurethral biopsy of his abnormal prostate gland proved a simple and efficacious means of establishing the diagnosis.

Summary

1. Three methods of prostatic biopsy are described with their indications and limitations.

2. The results of 81 prostate gland biopsies are presented. There were 40 open perineal biopsies in men suspected of having localized prostatic cancer. Twenty-two of these showed no evidence of cancer on biopsy; 18 demonstrated cancer on biopsy and appropriate surgical measures were taken wherever possible. There was an accurate correlation between the frozen and permanent sections in all instances.

Forty-one perineal needle biopsies were done during the same period. Of 33 men known to have metastatic prostatic cancer, 29 biopsies showed cancer and four did not (false negative). The eight remaining patients were not considered to have prostatic cancer and had negative biopsies.

3. Transurethral biopsy of the prostate is usually inadequate unless there is evidence of pathologic change along the urethra.

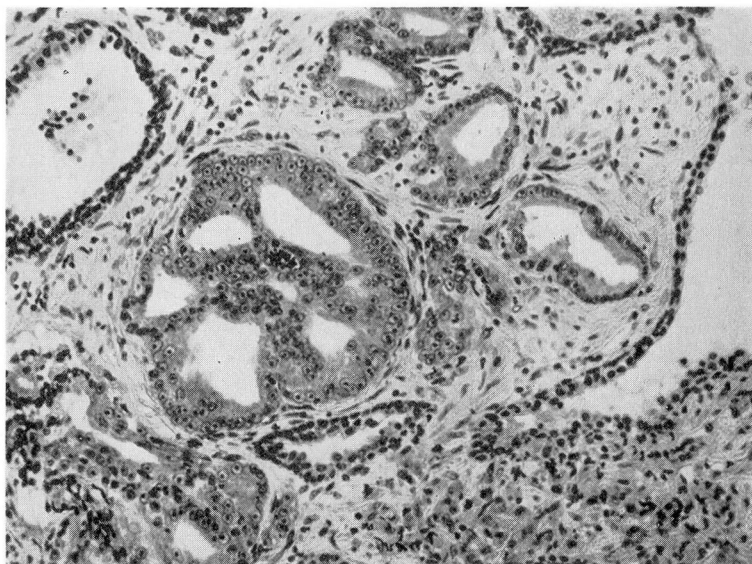


FIG. 2. Adenocarcinoma of prostate gland. Specimen secured by needle biopsy. Note reduplication of lumina and nuclear dedifferentiation.

4. Open perineal biopsy is the preferred method of accurately establishing the diagnosis of localized prostatic cancer, and is necessary for histologic confirmation prior to radical prostatectomy. Chronic prostatitis and acinar hyperplasia often simulate cancer on rectal palpation.

5. Needle biopsy is a useful means of obtaining tissue for histologic confirmation of metastatic prostatic cancer, particularly when the metastases are of an unusual nature. It is not accurate enough to use with localized lesions nor is it adaptable to frozen section technics.

References

1. Peters, H. and Young, J. D.: Prostatic smear in cancer diagnosis. *J.A.M.A.* **145**: 556 (Feb. 24) 1951.
2. Hazard, J. B. and Stevenson, G. F.: A frozen section technic. *Am. J. Clin. Path.* **19**: 873 (Sept.) 1949.
3. Nesbit, R. M. and Baum, W. C.: Serum phosphatase determinations in diagnosis of prostatic cancer. *J.A.M.A.* **145**: 1321 (April 28) 1951.