VITAMIN A INTOXICATION

MARY T. HARRISON, M.D.* and ROBERT D. MERCER, M.D.
Department of Pediatrics

THE clinical entity of hypervitaminosis A was first described in 1944 by Josephs.[1] In 1947 Toomey and Morissette[2] published a study conducted with excellent controls which clearly established the etiology of the disease. Since that time, the diagnosis has been made with increasing frequency, with a total of 24 cases reported to date.[3-16]

Three clinical factors must be established before the diagnosis can be made: (1) a clear-cut history of excessive intake of vitamin A; (2) elevated levels of vitamin A in the blood; and (3) roentgenographic evidence of subperiosteal new bone formation. Other clinical manifestations which have been reported include hyperirritability, pruritus, rash, alopecia, tenderness over the long bones, cheilosis, and bleeding tendency.

In all cases reported there was rapid improvement in clinical appearance after the vitamin concentrate was eliminated from the diet. The bone changes disappeared also, but this was a much slower process and required a number of months.

The following case is presented as an example of this syndrome.

CASE REPORT

A 28 month old boy was admitted to the hospital on March 17, 1953, because of fever of ten days' duration. He had been in good health until ten days prior to admission when his temperature rose to between 102 and 103 degrees F., the lips cracked and bled, and an ill-defined rash appeared on the face and anterior chest wall. Intense pruritus developed and resulted in deep excoriations of the skin of the arms, legs and trunk. The patient complained of pain in his penis, and a fissure on the glans penis was noted by the mother. Painful lumps appeared on both forearms and on the outer aspect of both feet. He walked "like a baby taking his first steps." The feet swelled so much that the shoes could not be worn. There was extreme irritability, restlessness and whining. At the onset of fever an injection of penicillin was given and antipyretics were started. For several weeks prior to the onset of the illness there had been mild constipation.

The family history was non-contributory. The birth and development had been entirely normal.

There had been an intake since the neonatal period of as much as 1 to 2 teaspoonfuls of Oleum Percomorph (Mead-Johnson) daily. One teaspoonful of this vitamin A-D concentrate provides 200,000 u. vitamin A and 30,000 u. vitamin D.

Physical Examination. The child was acutely ill. The rectal temperature was 101 degrees F., the pulse rate 120 per minute, and the respiratory rate 30 per minute. The blood pressure was 140 systolic (crying). The skin was hot and dry and showed

Fellow in the Department of Pediatrics.

Downloaded from www.ccjm.org on April 19, 2024. For personal use only. All other uses require permission.

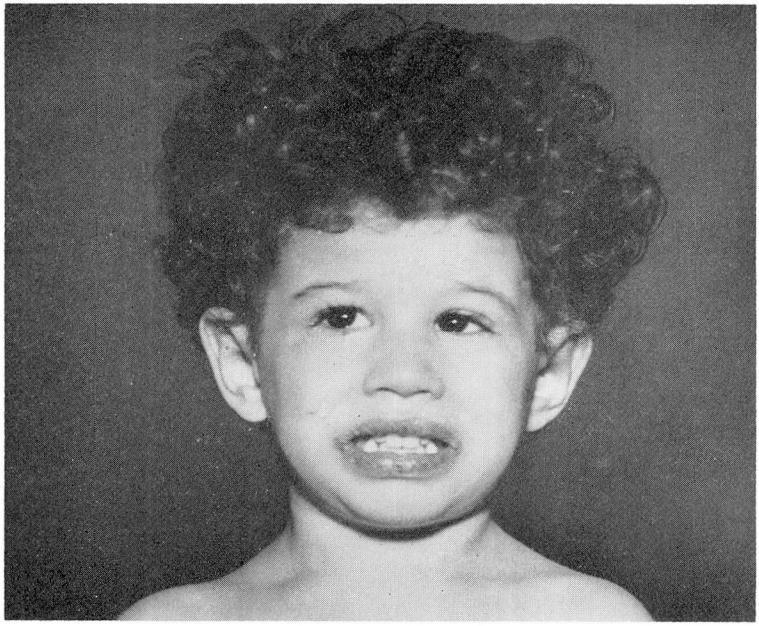

Fig. 1. Photograph of patient. Note fissuring of lips.

many deep excoriations. The lips were red and fissured with much bloody crusting (fig. 1). On both forearms along the ulnar shafts there were hot, tender, egg-sized swellings (fig. 2). Similar swelling was noted in the region of the fifth metatarsals of both feet.

The head was symmetrical and not enlarged. No pathologic changes were seen in the eyes, ears, nose and throat. There was moderate enlargement of the cervical, axillary and inguinal lymph nodes. The lungs were clear on percussion and auscultation. The heart was normal in size; the heart sounds were of good quality and a soft systolic pulmonic murmur was heard. The abdomen was normal in contour and soft. The liver was palpated 3 cm. below the right costal margin. The spleen was not felt. There was a small fissure at the urethral meatus. The rectal examination was normal. The child refused to stand or walk during the examination. The neurologic examination revealed no abnormalities.

Laboratory Studies. The red blood cell count was 4,380,000 per cu. mm., the hemoglobin content 11 Gm., and the white blood cell count 9200 per cu. mm. with 75 per cent neutrophils, 15 per cent lymphocytes and 10 per cent monocytes. Several urinalyses and stool examinations were normal. The sedimentation rate was 1.1 mm./min. The fasting blood sugar content was 83 mg. per hundred cc., and the blood ascorbic acid level was 0.26 per hundred cc. The Wassermann and serologic tests for lupus erythematosus were negative. Blood and stool cultures showed no pathogenic organisms. The vitamin A blood level was 4 plus elevated on the basis of a semi-quantitative test.[17]

X-ray Examination. X-rays of the chest and skull were reported as normal. Films of the upper extremities showed symmetrical cortical hyperostoses of the ulnas (fig. 3). Similar hyperostotic changes were present in the right fifth and left fourth and fifth

Downloaded from www.ccjm.org on April 19, 2024. For personal use only. All other uses require permission.

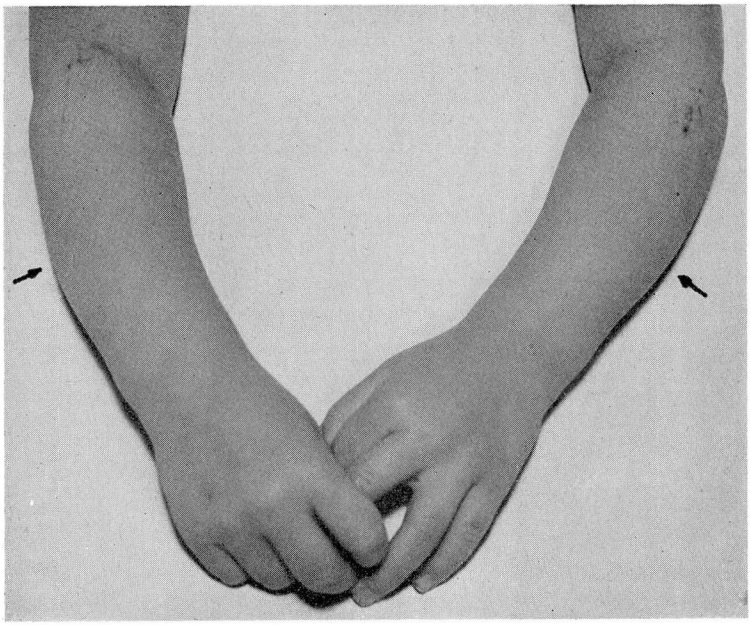

Fig. 2 Photograph of forearms. Note swelling over ulnar regions.

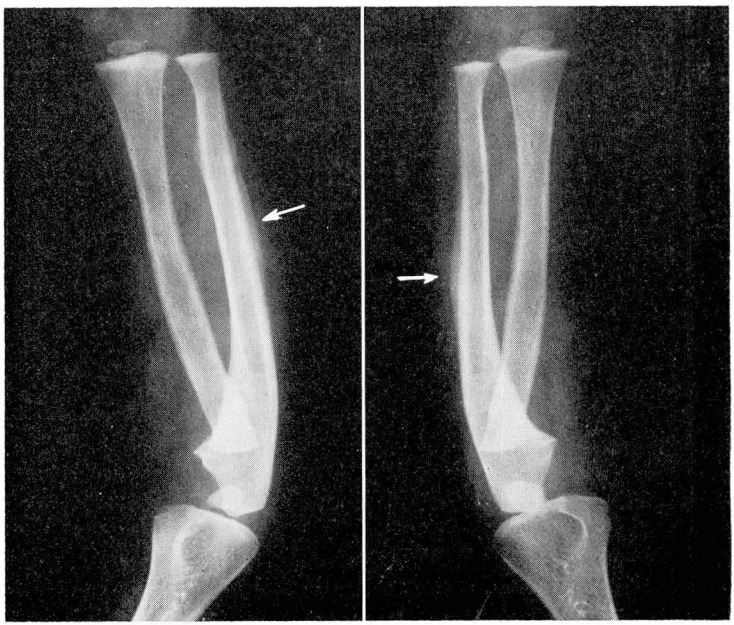

Fig. 3. X-rays of forearms demonstrate hyperostotic changes on ulnar bones.

Downloaded from www.ccjm.org on April 19, 2024. For personal use only. All other uses require permission.

metatarsals (fig. 4). Because of the increased lines of density at the lower ends of the ulnas, it was believed that healing rickets or scurvy was also present.

Course. Diagnoses of hypervitaminosis A and subclinical scurvy were made. Therapy consisted only of an adequate diet and 50 mg. of ascorbic acid daily. Within several days the child was much improved. There have been several follow-up examinations, the latest one on July 8, 1953, four months after admission, at which time the patient was clinically well. X-ray studies at this time showed much improvement with only minimal periosteal changes in the metatarsals.

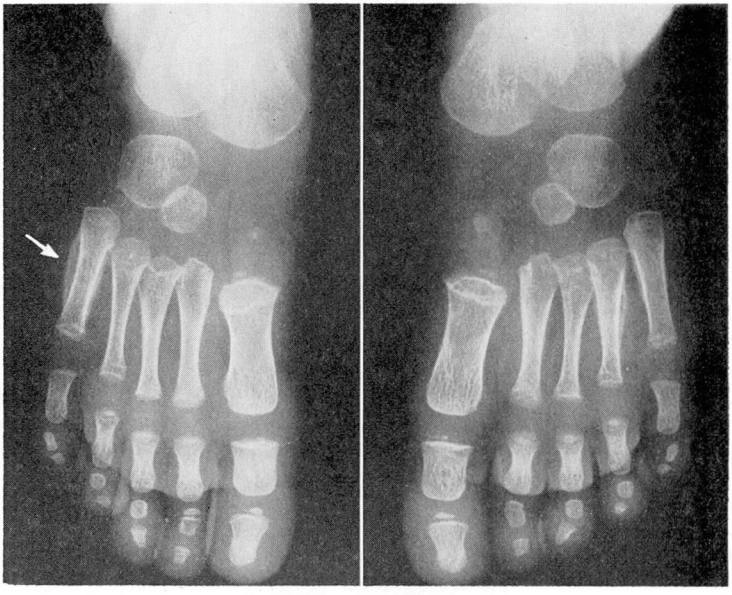

Fig. 4. X-rays of feet demonstrate hyperostotic changes on metatarsal bones.

DISCUSSION

The diagnosis of hypervitaminosis A can be made readily if the syndrome is kept in mind and if a careful history of vitamin intake is routinely taken. The essential clinical features are pruritus, cheilosis, hyperirritability, and swellings of forearms and feet. The roentgenographic changes resemble those of infantile cortical hyperostosis, from which it must be differentiated. Thus far, vitamin A intoxication has not been reported to involve the mandible, which is usually reported in infantile cortical hyperostosis. Vitamin A intoxication is rarely seen before the age of 18 months, whereas the diagnosis of infantile cortical hyperostosis can usually be made before the age of six months. Children with this latter disease have been reported to show remission in symptoms while taking large amounts of vitamin A. Caffey[6] has pointed out that the predilection in hypervitaminosis A for "exposed bones," such as ulnas, fifth metatarsals,

Downloaded from www.ccjm.org on April 19, 2024. For personal use only. All other uses require permission.

fibulas, and clavicles, would tend to support the theory that the changes may be related in part to trauma.

One cannot emphasize too strongly the need for careful instruction of mothers in the correct dosage of vitamin A concentrates. The mother of our patient was not aware of any danger in overdosage and was of the opinion that "if the boy doesn't eat, he probably needs more vitamins." The result of this rationalization was the daily use of 10 to 20 times the usual amount of A-D concentrate. A six month old sibling who was receiving the same dosage of vitamin A did not show bony changes demonstrable by x-ray or increased blood vitamin A level. Apparently the clinical picture results from overdosage with vitamin A for a long period of time.

SUMMARY

A case of vitamin A intoxication in a 28 month old child is presented. The principal clinical manifestations were hyperirritability, cheilosis, pruritus, and swelling along the ulnas and along the fifth metatarsals. Roentgenographic evidence of subperiosteal new bone formation as well as high blood vitamin A levels helped to confirm the diagnosis. Prompt relief of symptoms followed the withdrawal of vitamin A.

References

1. Josephs, H. W.: Hypervitaminosis A and carotenemia. Am. J. Dis. Child. **67**:33-43 (Jan.) 1944.
2. Toomey, J. A. and Morissette, R. A.: Hypervitaminosis A. Am. J. Dis. Child. **73**:473-480 (April) 1947.
3. Arena, J. M., Sarazen, P., Jr. and Baylin, G. J.: Hypervitaminosis A; report of unusual case with marked craniotabes. Pediatrics **8**:788-794, 1951.
4. Bair, G.: Chronic vitamin A poisoning; report of case. J.A.M.A. **146**:1573-1574 (Aug. 25) 1951.
5. Berrey, B. H.: Postinfantile cortical hyperostosis with subdural hematoma; report of case and review of literature. Pediatrics **6**:78-85 (July) 1950.
6. a) Caffey, J.: Chronic poisoning due to excess of vitamin A. Description of clinical and roentgen manifestations in 7 infants and young children. Pediatrics **5**:672-687 (April) 1950.
   b) Caffey, J.: Chronic poisoning due to excess of vitamin A; description of clinical and roentgen manifestations in 7 infants and young children. Am. J. Roentgenol. **65**:12-26 (Jan.) 1951.
7. Dickey, L. B. and Bradley, E. J.: Hypervitaminosis A; case report. Stanford M. Bull. **6**:345-348 (May) 1948.
8. Fried, C. T. and Grand, M. J. H.: Hypervitaminosis A. Am. J. Dis. Child. **79**: 475-486 (March) 1950.
9. Goldzier, S. E., Pisacano, J. C. and Wald, A. M.: Hypervitaminosis A. J. Ped. **41**:198, 1950.
10. Gribetz, D., Silverman, S. H. and Sobel, A. E.: Vitamin A poisoning. Pediatrics **7**:372-384 (March) 1951.
11. Naz, J. F. and Edwards, W. M.: Hypervitaminosis A; case report. New England J. Med. **246**:87-89 (Jan. 17) 1952.

Downloaded from www.ccjm.org on April 19, 2024. For personal use only. All other uses require permission.

12. Reyersbach, G. C., Hanelin, J. and Joplin, R. J.: Vitamin A intoxication; report of case. New England J. Med. **246**:978-980 (June 19) 1952.

13. Rineberg, I. E. and Gross, R. J.: Hypervitaminosis A with infantile cortical hyperostosis, J.A.M.A. **146**:1222-1225 (July 28) 1951.

14. Rothman, P. E. and Leon, E. E.: Hypervitaminosis A; report of 2 cases in infants. Radiology **51**:368-374 (Sept.) 1948.

15. Sulzberger, M. B. and Lazar, M. P.: Hypervitaminosis A; report of case in adult. J.A.M.A. **146**:788-793 (June 30) 1951.

16. Wyatt, T. C., Carrabello, C. A. and Fletcher, M. E.: Hypervitaminosis A; report of case. J.A.M.A. **144**:304-305 (Sept. 23) 1951.

17. Josephs, H. W.: Studies in vitamin A; relation of vitamin A and carotene to serum lipids. Bull. Johns Hopkins Hosp. **65**:112-124 (July) 1939.

Downloaded from www.ccjm.org on April 19, 2024. For personal use only. All other uses require permission.