

SURGERY OF AORTIC ARCH ANOMALIES

DONALD B. EFFLER, M.D.
Department of Thoracic Surgery

and

F. MASON SONES, JR., M.D.
Department of Cardiovascular Disease

ANOMALIES of the aortic arch represent clinically the most important group of congenital lesions in the heart and great vessels. The clinical importance of these extracardiac anomalies is based on three major factors: (1) accurate diagnosis is possible in most instances, (2) surgical correction is possible in the majority of cases, and (3) definitive surgical therapy may offer a normal life expectancy to the patients.

Aortic arch anomalies are classified in the noncyanotic category of congenital heart disease. In a high percentage of cases early recognition of the condition is possible during infancy and preschool childhood. Most important, it is in this group of congenital lesions that surgery offers a physiologic cure if intervention occurs before irreversible secondary changes have become manifest. In contrast, surgery for intracardiac lesions is usually of a palliative nature in congenital heart disease and should not be considered curative except in isolated instances.

PATENT DUCTUS ARTERIOSUS

Persistence of the ductus arteriosus occurs more frequently than any of the other aortic anomalies. In 1939 Gross¹ reported the first successful ductus ligation; this brilliant surgical feat provided a tremendous stimulation to clinical interest. Ductus surgery is commonplace today, attesting to the importance of Gross' contribution.

The ductus arteriosus is an integral part of the fetal circulation; with the foramen ovale it shunts most of the blood flow from the right side of the heart and the pulmonary artery into the systemic circulation. Functional closure occurs shortly after birth and eventual obliteration is represented by the ligamentum arteriosum.²

When patency persists, there is a great alteration in circulatory dynamics. Aeration of the lungs at birth is associated with a fall in pulmonary vascular resistance and a relative decrease in pulmonary arterial pressure. During the first months of life, pressures in the systemic circulation progressively exceed the pulmonary arterial pressure. At the beginning there is an appreciable differential only in systole, and a reversal of the fetal shunt occurs with systolic aorto-pulmonary flow. This early phase of patent ductus arteriosus may persist

during the first two to four years of life and manifest itself by only a systolic murmur. With body growth the resistance in the systemic circulation increases until aortic diastolic pressure greatly exceeds the diastolic pressure in the pulmonary artery. When this occurs the shunt continues from aorta to pulmonary artery throughout all phases of the cardiac cycle and the characteristic continuous murmur appears (fig. 1). When the continuous, or "machinery,"

DUCTUS ARTERIOSUS

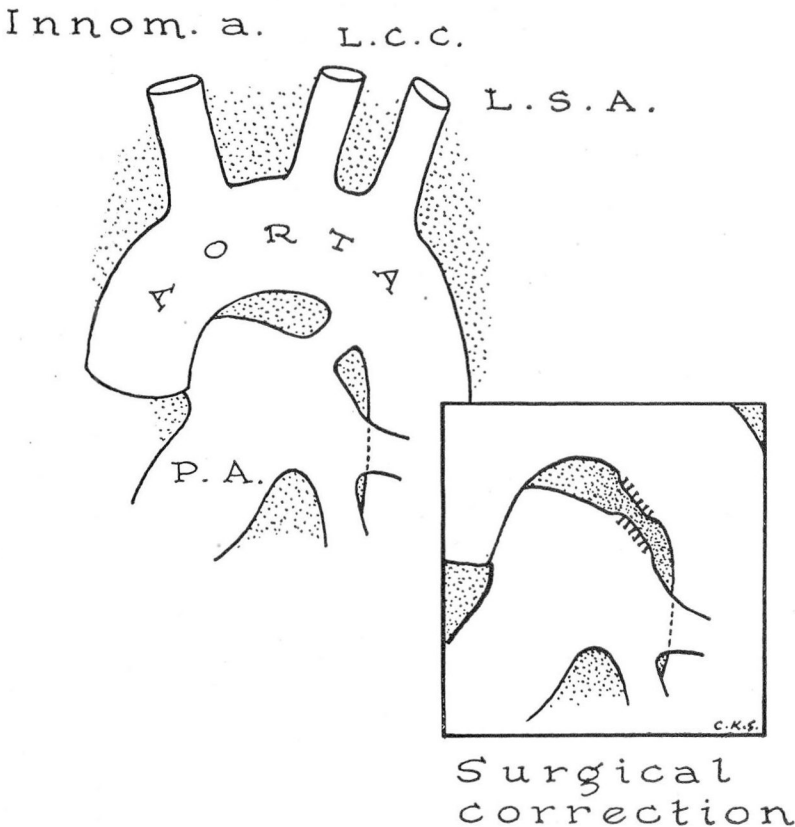


Fig. 1. The patent ductus arteriosus is a direct communication between the descending arch of the aorta and the pulmonary artery; as such it shunts arterial blood from the aorta into the "venous" blood of the pulmonary arterial circulation. In effect, this is a physiologic arteriovenous shunt. Surgical treatment must offer permanent obliteration of this shunt; surgical division, rather than ligation in continuity, best accomplishes this end.

COMPLICATED ADULT DUCTUS

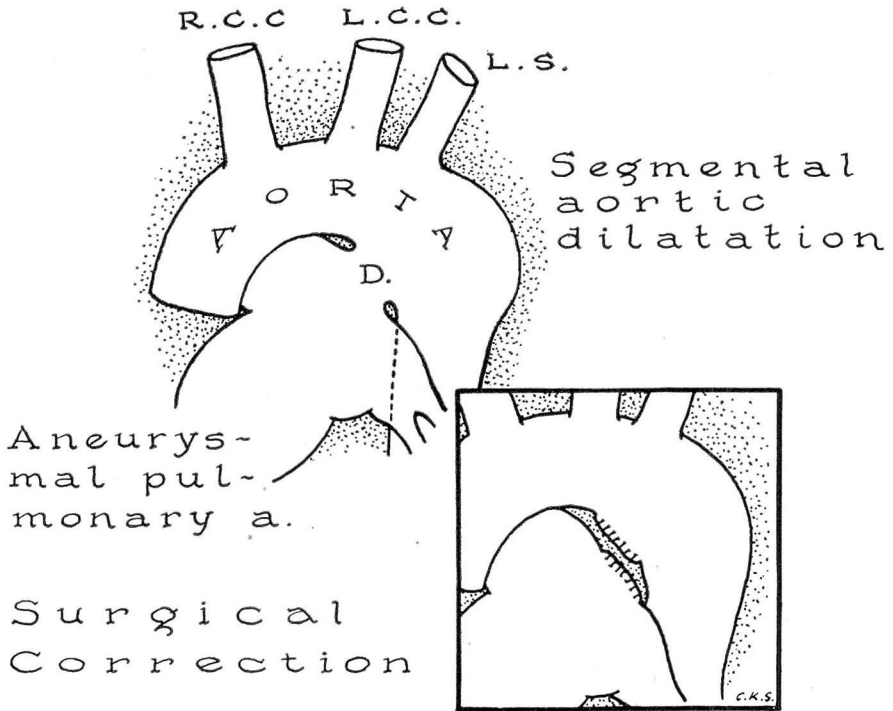


Fig. 2. Complicated ductus arteriosus with aneurysmal changes is usually observed in young adults. Dilatation of the aorta at the level of the ductus may be associated with medial necrosis of the aortic os. Aneurysm of the pulmonary artery effects both shortening and widening of the ductus. In all probability this is the "window" type of ductus described by Rokitsky⁶ in 1852. Surgical division of the complicated ductus will be facilitated by controlled arterial hypotension.^{3,7,8}

murmur is present it is usually diagnostic of a patent ductus arteriosus, nevertheless a significant feature must be recognized—the absence of a continuous murmur does not indicate the absence of a patent ductus arteriosus! We have treated ten infants between 4 and 33 months of age, who suffered severe cardiac embarrassment because of large ducti producing only a systolic murmur. In each case it was possible to demonstrate the lesion by cardiac catheterization and to effect surgical obliteration of the shunt. We believe that the majority of these infants would have died before a continuous murmur were to become apparent.

Adults with patent ductus arteriosus who develop progressive pulmonary

hypertension and degenerative changes in the pulmonary artery lose the continuous murmur, if pulmonary arterial pressure rises to systemic levels; in this group, the continuous murmur may give way to a systolic murmur only. Occasionally a "to-and-fro" murmur may be present because of the development of pulmonary valve incompetence; in such a case the clinical picture may closely resemble that of aortic insufficiency. Cyanosis is never a clinical feature of patent ductus arteriosus, unless accompanied by another lesion (fig. 2).

The treatment of patent ductus arteriosus is surgical. Division of the ductus is the ideal therapy and is superior to ligation in continuity. Operative mortality in patients with uncomplicated ductus arteriosus is less than 2 per cent. The ideal candidate is the youngster of 5 or 6 years who demonstrates only the typical auscultatory findings of the anomaly. In such a patient the lesion should be corrected when it is recognized, before bacterial endarteritis, myocardial insufficiency, pulmonary aneurysm or other local vascular changes occur, as these complications add appreciably to the surgical risk. We have found controlled arterial hypotension to be a valuable adjunct in surgical division of complicated ductus arteriosus. When there is aneurysmal dilatation of the pulmonary artery or local degenerative changes in the aorta or ductus, the risk of uncontrollable hemorrhage is considerable. These degenerative changes may be secondary to previous infection or simply to progressive, long-standing pulmonary hypertension. However, when these changes are present, the elasticity and the integrity of the involved vessel walls are greatly altered. Reduction of the intraluminal pressure by controlled arterial hypotension facilitates the dissection of the complicated ductus and adds appreciably to the safety of the operation. Intra-arterial transfusion is an effective means of treating surgical hemorrhage should it occur in spite of all precautions.³

COARCTATION OF THE AORTA

Coarctation is a localized constriction of the aorta; in the adult form the constriction is at or below the ligamentum arteriosum. The constriction may be total, producing complete obstruction. More commonly it presents a small, eccentrically placed lumen that permits a jet-like stream of blood to enter the distal aorta. The constant impingement of this jet stream against the wall of the descending aorta may produce a localized atheroma (jet plaque) and predispose to a localized aneurysm.

Coarctation of the aorta produces a radical alteration in the circulatory dynamics. Obstruction below the ligamentum ductus produces the pathognomonic findings of hypertension in the upper extremities and a corresponding hypotension in the lower extremities (fig. 3). The blood volume through the constricted area may be negligible or absent. Hence, a well-developed collateral circulation is necessary to supply the trunk and lower extremities. Three main pathways develop: (1) the internal mammary arteries supplying the anterior chest wall and abdomen enter the inferior epigastric arteries; (2) the high intercostals

convey blood from the first branches of the subclavian arteries to the aorta below the constriction; and (3) the descending vessels in the scapular area arise from the subclavian and axillary arteries to supply the posterior chest wall and communicate with the perforating branches of the lower intercostals. It is the development of these tortuous collaterals which produces the visible pulsating vessels in the interscapular region and the characteristic rib notches visible on the roentgenogram.

ADULT COARCTATION , AORTA

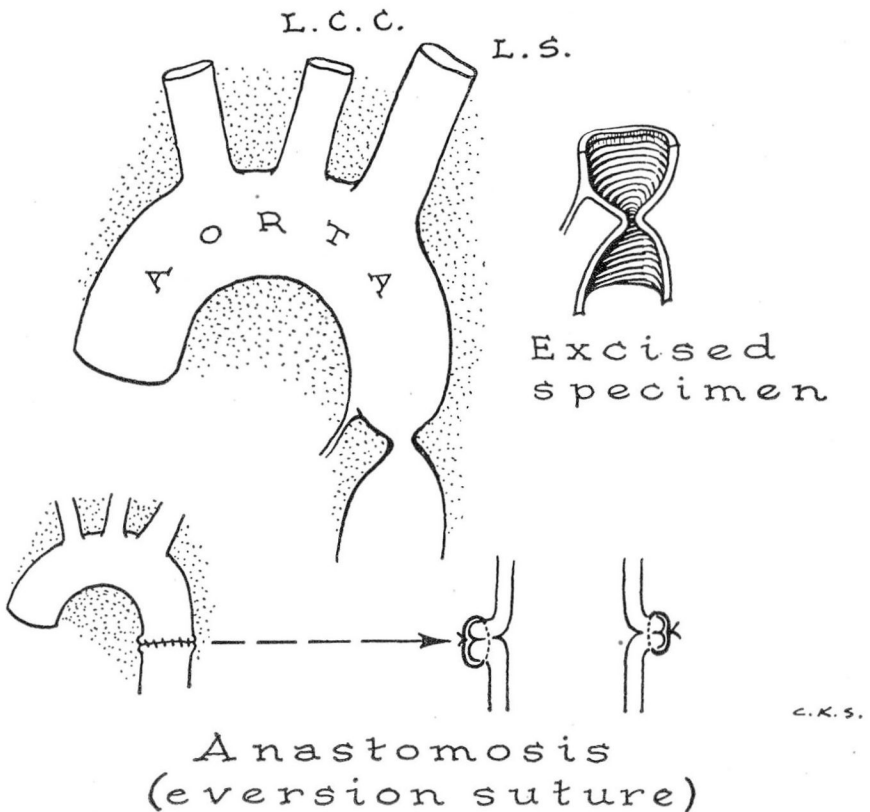


Fig. 3. Simple type of adult coarctation occurring below the ligamentum arteriosum. The localized constriction may have a tiny lumen or complete diaphragm. Surgical correction is accomplished by excision of the constricting lesion and primary end-to-end anastomosis of the aortic segments.

COMPLICATED ADULT COARCTATION

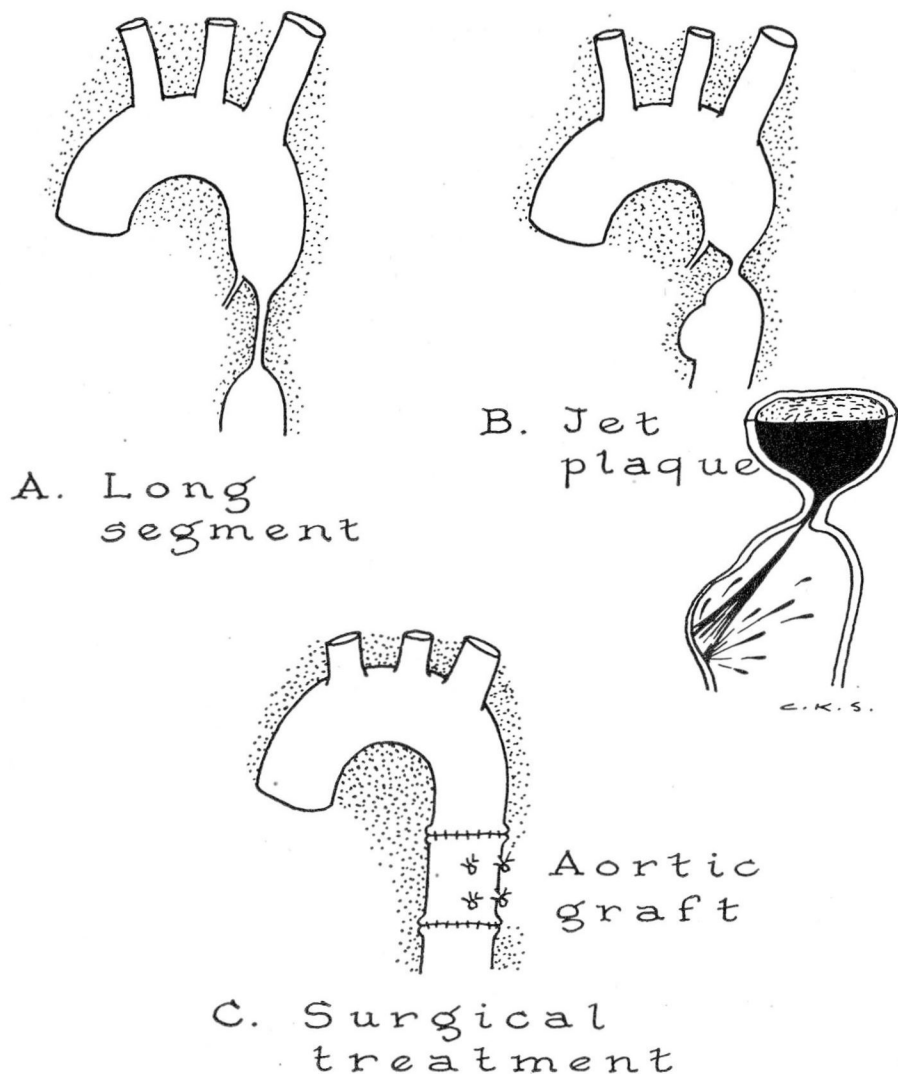


Fig. 4. A. Occasionally the area of constriction is several centimeters in length. Excision of this type of coarctation will not permit primary approximation of the aortic segments. Preserved aortic graft is used to bridge such a gap. B. Simple coarctation with an eccentric, intraluminal ring may direct the jet-like stream against the wall of the descending aorta. A localized atheroma (jet plaque) may develop at this point; localized aneurysm below the coarctation will require more extensive resection than described in figure 3.

The dangers of untreated coarctation are widely known. In addition to the obvious hazards of severe hypertension with cardiac embarrassment and cerebral vascular accident, patients with untreated coarctation may develop medial necrosis of the aorta with dissecting aneurysm or spontaneous rupture. It is our belief that the vascular degeneration of untreated coarctation appears earlier in young men and may be a serious factor by the age of 20 years. Recognition and surgical therapy in patients between 5 and 10 years of age approximates the ideal treatment for this condition.

The surgical treatment of adult coarctation is best accomplished by excision of the constricting lesion with end-to-end anastomosis of the proximal and distal aortic segments.⁴ Less direct methods that utilize the dilated subclavian artery to bypass or re-establish continuity of the aorta are falling into discard. If the area of constriction is unusually long, or there are irreversible degenerative changes in the aorta immediately above or below the coarctation, arterial grafts should be employed (fig. 4). Medial necrosis of the proximal aorta, or in the region of the jet plaque below, is a serious threat to anastomotic healing; dissecting aneurysm or frank dehiscence of the suture line has occurred days or weeks after operation when this localized vascular degeneration was present.

Coarctation of the aorta is a serious anomaly which when untreated has a poor, over-all prognosis. Recognition and proper surgical intervention before the onset of vascular degeneration and cardiac embarrassment offer a promising outlook.

AORTIC RINGS

The third major group of arch anomalies includes the so-called aortic rings. These developmental anomalies of the aortic arch and its major vessels are characterized by reduplication of the arch, by anomalous origin of a major tributary, or by deviation of the normal left-sided pattern to the right. In a previous communication⁵ devoted to the diagnosis and the treatment of aortic rings, we suggested the following simple classifications of these anomalies:

Group I—Left Descending Aorta:

- (a) Left aortic arch (*normal adult*).
- (b) Left aortic arch with right subclavian artery arising on descending aorta distal to the left subclavian artery (*dysphagia lusoria*).
- (c) Left aortic arch (with or without atresia) and a functioning right arch constituting an anatomic double arch.

Group II—Right Descending Aorta:

- (a) Right arch (*mirror image of normal aorta*).
- (b) Right arch with *dysphagia lusoria* (*mirror image of b in Group I*).
- (c) Right aortic arch with a functioning left arch (*mirror image of c in Group I*).

This group of embryologic anomalies, aortic rings, possesses a clinical significance that should not be overlooked. The term ring is employed because

ANOMALOUS RIGHT SUBCLAVIAN

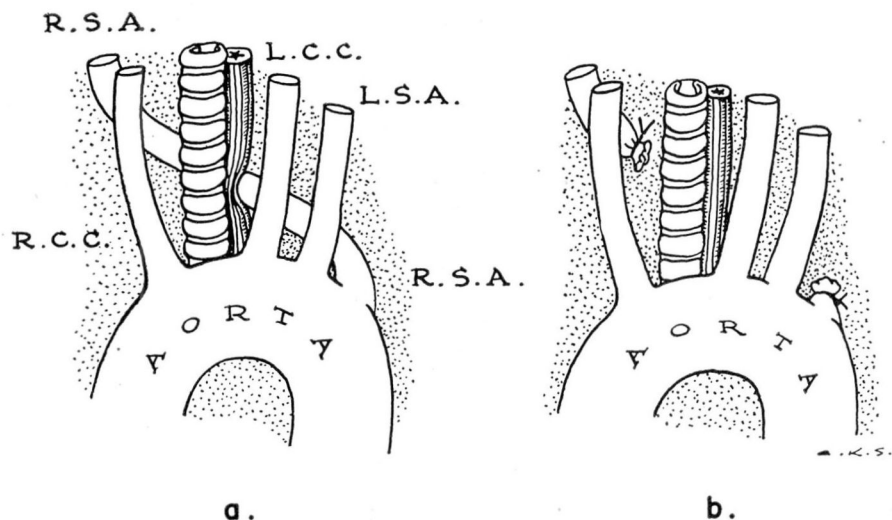


Fig. 5. a. Simple aortic rings produced by retro-esophageal, right, subclavian artery which arises from the descending aorta below the normal left subclavian artery (after Gross).⁹ b. Obstruction of esophagus (dysphagia lusoria) relieved by surgical division of the anomalous right subclavian artery. Division of this vessel does not impair the arterial circulation of the right arm.

each of these variations results in a vascular encirclement of trachea, of esophagus, or of both tubes (fig. 5). If the encirclement is tight enough to encroach upon these hollow tubes, mechanical impairment will result. Usually the anomaly itself produces no embarrassment in circulation; it is the constriction of the trachea and/or of the esophagus which produces disease.

Symptoms produced by aortic rings will usually appear in infancy. The degree of severity is usually proportional to the degree of mechanical encroachment of the encircling vessel on the esophagus or trachea. Some children will have obvious distress in respiration or in feeding, and even at rest; others will manifest these symptoms only during stress imposed by physical exertion or secondary infection. Unusual feeding problems characterized by prompt regurgitation and choking spells may suggest a vascular anomaly. Likewise, persistent wheezing and stridor may be due to extrinsic tracheal compression;

when these respiratory symptoms are coupled with a mechanical feeding problem, the possibility of a vascular ring is very real (fig. 6).

Methods of diagnosis have been described in detail⁵ and will not be repeated here. It is worthwhile to state, however, that clinical suspicion and simple radiographic studies may serve to establish the presence of a ring. The exact nature of the anomaly can be determined by retrograde arteriography in a large percentage of cases. Proper diagnostic studies will have a great influence on the surgical result, since each of the lesions is amenable to surgical relief.

DOUBLE ARCH LEFT DESCENDING AORTA

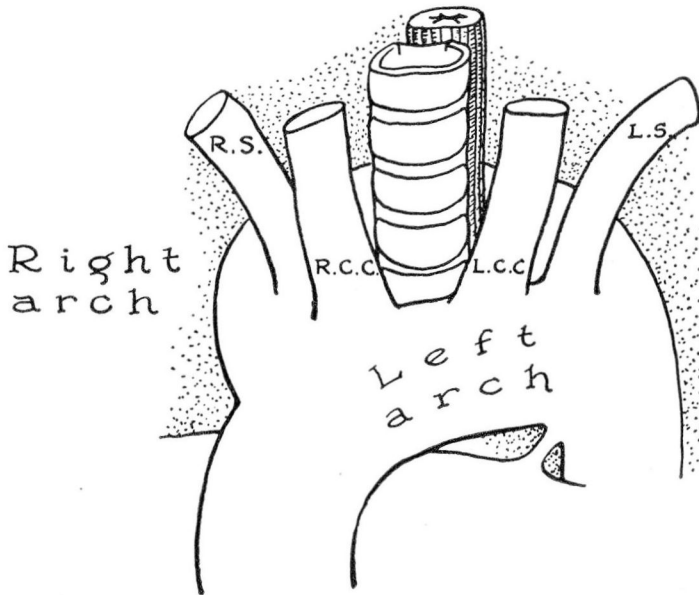


Fig. 6. Double aortic arch with left descending aorta (after Gross).⁹ In this case both arches are patent; surgical division of the left arch to relieve tracheo-esophageal compression may be done with comparative safety.

SUMMARY

Anomalies of the aortic arch do not produce cyanosis unless accompanied by other cardiac lesions or as a terminal feature of cardiac failure. Recognition of

these lesions is mandatory if surgical correction is to be accompanied by a low mortality figure. Most of these congenital abnormalities present clinical features that are recognizable on physical examination alone; diagnostic refinements, such as cardiac catheterization and aortography, are necessary in a comparatively small percentage of cases.

References

1. Gross, R. E. and Hubbard, J. P.: Surgical ligation of a patent ductus arteriosus; report of first successful case. *J.A.M.A.* **112**:729-731 (Feb. 25) 1939.
2. Taussig, H. B.: *Congenital Malformations of the Heart*. New York, The Commonwealth Fund, 1947, p. 331.
3. Effler, D. B. and Sones, F. M., Jr.: Controlled hypotension in surgical treatment of patent ductus arteriosus. To be published.
4. Crafoord, C. and Nylin, G.: Congenital coarctation of the aorta and its surgical treatment. *J. Thoracic Surg.* **14**:347-361 (Oct.) 1945.
5. Sones, F. M., Jr., and Effler, D. B.: Diagnosis and treatment of aortic rings. *Cleveland Clin. Quart.* **18**:310-320 (Oct.) 1951.
6. von Rokitsansky, C.: *Ueber einige der wichtigsten Krankheiten der Arterien*. Wien, Staatsdruckerei, p. 72, 1852.
7. Gardner, W. J.: Control of bleeding during operation by induced hypotension. *J.A.M.A.* **132**:527-574 (Nov. 9) 1946.
8. Hale, D. E.: Controlled hypotension by arterial bleeding during operation and anesthesia. *Anesthesiology* **9**:498-505 (Sept.) 1948.
9. Gross, R. E. and Ware, P. F.: Surgical significance of aortic arch anomalies. *Surg., Gynec. & Obst.* **83**:435-448 (Oct.) 1946.