

VALUE OF KVEIM TEST AS A DIAGNOSTIC MEASURE IN SARCOIDOSIS

A Preliminary Report

FRANCIS J. ROGERS, M.D.* and JOHN R. HASERICK, M.D.

Department of Dermatology

IN 1941, Kveim¹ published a report on a "new and specific cutaneous I reaction in Boeck's sarcoid." He observed that following the intracutaneous injection of a tissue suspension of sarcoid lymph nodes in 13 patients with active sarcoidosis, 12 developed a papule at the site of injection. Histologically, these papules resembled cutaneous sarcoidosis. No papule developed in patients with either tuberculosis or syphilis who were similarly tested.

The test is not widely used, however, due to a number of inherent difficulties. The sarcoid tissue is not easy to obtain in quantity. The suspension cannot be standardized as to its potency, and the length of time needed to interpret the test tends to lessen its practical application. Further, subsequent investigators have questioned Kveim's opinion as to the test's specificity. It has been claimed that dead tubercle bacilli,² BCG vaccine,^{3,4} normal spleen suspension,^{5,6} and leukemic lymph node suspension^{7,8} may give a response similar to the sarcoid-tissue suspension when injected into patients with sarcoidosis. Also, the test has occasionally been reported as positive in conditions other than sarcoidosis.⁷⁻⁹ Nevertheless, interest in the test has been maintained by other reports¹⁰⁻¹⁸ that tend to substantiate the usefulness of this delayed papular response in the diagnosis of sarcoidosis. The Kveim test has been employed extensively at the Cleveland Clinic for the past three years. The present study is concerned with an evaluation of the test based upon the reactions in 88 patients. The results have proved to be of such consistent diagnostic and prognostic value as to prompt this preliminary report.

METHODS

Method of Preparation of the Antigen. ** Portions of lymph nodes (usually cervical or axillary) are obtained at the time of surgery from a patient undergoing a diagnostic biopsy for suspected sarcoidosis. The lymph nodes are tested for sterility, and then stored in the refrigerator at about minus 10 degrees C. If the tissue is sterile and the clinical and pathologic criteria of sarcoidosis are established for the patient, it is pooled with lymph nodes similarly obtained from other patients. The pooled tissue is then ground, while frozen, in a sterile mortar. Physiologic saline is added during the grinding in the propor-

* Fellow in the Department of Dermatology.

** Mr. Alfred Reich of the Department of Clinical Pathology has prepared all antigen used. The method described by Kveim has been slightly modified.




Fig. 1




Fig. 2

Fig. 1. Positive Kveim test at six weeks. The tuberculoid reaction in this test was quantitatively small and superficial. X 35.

Fig. 2. Positive Kveim test at six weeks. The tuberculoid reaction is extensive, involving most of the dermis. Otherwise it is similar to the reaction in figure 1. X 35.

tion of nine parts saline to one part frozen tissue, by weight. Aqueous merthiolate to make a 1:10,000 solution is added as a preservative. The resultant suspension is strained through eight to ten layers of wet gauze and stored in 10 cc. vials. After pasteurization in a water bath at 60 degrees C. for one hour on two consecutive days, a final check for sterility is made. If the suspension is sterile, it is then ready for use.

Method of Testing. The suspension settles on standing and should be shaken lightly prior to use. The test is done in the same manner as is a tuberculin test: with a 25-gauge needle, the suspension is injected as superficially as possible into the dermis. With the 10 per cent lymph node suspension used, 0.1 cc. of suspension is injected. The injection is usually made on the flexor aspect of the forearm, and a mole, scar, or other landmark is used to chart the test site. Patients are instructed to return in six weeks, at which time the test site is excised with a small 5-mm. cutaneous punch.

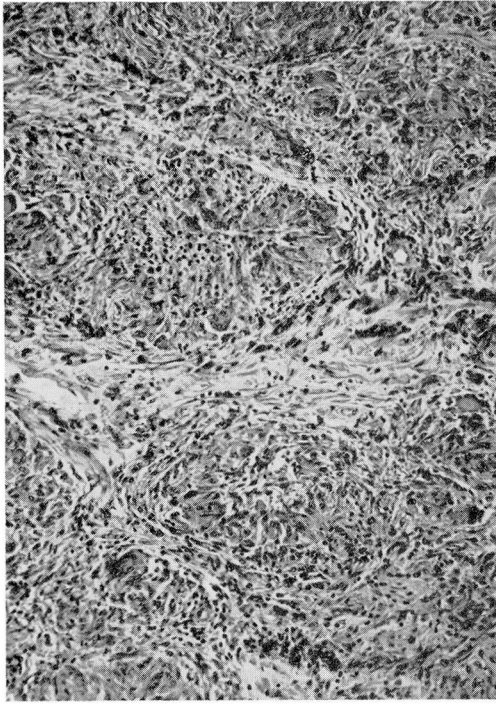


Fig. 3

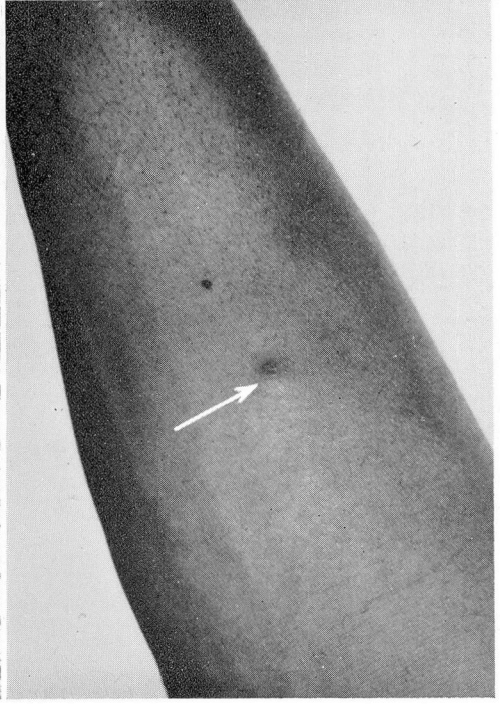


Fig. 4

Fig. 3. Enlargement of the square marked on figure 2. The tuberculoid reaction resembles that seen in sarcoidosis. X 135.

Fig. 4. Papule at site of a positive Kveim test of six weeks' duration (flexor aspect of the forearm). All papules are not this large or prominent. The size of the papule corresponds to the amount and depth of the underlying tuberculoid reaction.

EVALUATION OF THE TEST

Criterion of a Positive Test. In this study the sole criterion of a positive test is the histologic demonstration in the excised test site of a tuberculoid reaction resembling cutaneous sarcoidosis. This reaction consists of the focal collections of epithelioid cells with a variable but usually slight lymphocytic infiltration, and an occasional giant cell of the Langhans' type.

Variations in the histologic reactions of positive tests in this investigation have been thought due to three factors: (1) the differences in quality (potency) of the antigen used; (2) the differences in duration of the tests; and (3) the patient's susceptibility to the stimulus.

By preparing a large amount of antigen at one time, and injecting a constant amount for each test, the first factor is minimized as much as possible. The duration of the test prior to excision also influences the resulting histologic

characteristics of the positive test. If excised under four weeks the tuberculoid nature of the infiltrate may be too immature to recognize, while if excised after three months, the test may be histologically indistinguishable from cutaneous sarcoidosis.

It has been observed, however, that tests of the same duration using the same batch of antigen will vary somewhat in their microscopic characteristics from patient to patient. Some patients will develop only a few focal areas of epithelioid cells, while others will develop a more massive reaction involving the entire width of the dermis down to and including the upper hypoderm. Figures 1, 2, and 3 illustrate the variations that have been observed in tests of six weeks' duration, using the same batch of antigen.

Other Factors to Consider in Evaluating the Test. In some reports, emphasis is placed on the cutaneous response at the test site. With a positive test, a characteristic papule usually develops which lasts for months and usually involutes in about a year. This reliance on the clinical appearance of the test site has many disadvantages however. An inflammatory nonspecific response to the antigen may develop and the resulting papule may appear similar to that produced by the true positive granulomatous reaction; or the granulomatous reaction may be quantitatively slight without the development of a well-defined papule at the test site. Much confusion has undoubtedly been created in the past by the use of poorly defined clinical criteria in assessing the test.

In this study, two patients each presented, at six weeks, a palpable infiltration at the test site, without the development of a visible papule. Microscopically, the tuberculoid reaction was situated deep in the dermis and was quantitatively small. (Early in the investigation large-bore needles were used for the injections, which, inadvertently, were occasionally given too deep in the dermis.)

At the sites of the other positive tests, papules were present. These papules began to develop as early as one week, and by six weeks had attained a size of 3 to 6 mm. in diameter. They were of a reddish-brown color, remained stationary in size up to the time of excision, and did not break down or ulcerate (fig. 4).

However, papules have developed at the test site in three instances using the suspension of sarcoid gland, and two instances using a suspension of normal spleen. Such papules appeared similar to those usually seen at the site of a positive test, but histologically revealed a mild inflammatory infiltrate without a tuberculoid reaction and these tests were considered negative.

It has also been observed that if the injection is made superficially in an area where there is little underlying fat, such as the forearm, and no papule or palpable infiltration is present at the test site within six weeks, such a test site will reveal normal skin when excised. The smallest degree of tuberculoid infiltration encountered in the present series has reflected its presence clinically as an area of induration at the test site.

All papules and test sites with the slightest suspicion of an infiltration were excised, and a positive test was interpreted solely on the basis of the histologic appearance. Also, after the excision of many "clinically negative" test sites only to find normal skin microscopically, it seems justifiable to interpret a test

as negative when no infiltration appears at the test site six weeks after the superficial injection of an antigen known to be potent.

VALUE OF THE TEST IN THE DIAGNOSIS OF SARCOIDOSIS

Patients included in this study may be divided into three groups: (1) a control group in which the diagnosis of sarcoidosis had been established before the time of the test; (2) a control group in which diseases other than sarcoidosis were present; and (3) a group in which the diagnosis was uncertain at the time of testing. In the latter group, sarcoidosis, tuberculosis, certain occupational diseases of the lungs, pulmonary malignancy, and Hodgkin's disease and other lymphoblastomas were among the diagnoses considered when the patients were first seen; in most instances the diagnoses were established only by prolonged observation, extensive laboratory investigations and/or biopsies of the affected tissues (such as lung, lymph node, liver, and skin). Group 3, in short, represents the difficult diagnostic problems in which a reliable test for sarcoidosis would be of greatest value.

A total of 88 patients have been tested and sufficiently followed to include in this study. Table 1 lists the diagnoses of these cases. They will be discussed according to the test results.

TABLE 1
Diagnoses in 88 Cases

No. of Cases	Results of Kveim Test	Biopsy of Test Site	Diagnosis	Comment
40	Positive	Yes	Sarcoidosis	Clinically active as judged by follow-up
(4)	Positive when first tested, then later negative	Yes	Sarcoidosis	(Included in group of positive tests) Retest was negative when in clinical remission as judged by follow-up
4	Negative	Yes	Sarcoidosis	3 in remission 1 entering remission
3	Negative	Yes	Sarcoidosis (?)	2 suspected sarcoidosis in active stage 1 suspected case entering remission
19	Negative	Yes	Pulmonary berylliosis — 2 cases Tuberculous adenitis Interstitial pneumonitis Chronic uveitis, unknown origin Regional enteritis	Positive patch tests and work histories Positive culture

Table 1 (*Continued*)

No. of Cases	Results of Kveim Test	Biopsy of Test Site	Diagnosis	Comment
			Diffuse pulmonary fibrosis Chronic ulcerative colitis Mycosis fungoides Chronic periostitis of nasal bones Congestive heart failure Chronic nonspecific lymphadenitis Rheumatic fever with erythema nodosum Sjögren's syndrome Pulmonary fibrosis — 2 cases Pulmonary fibrosis with lipid pneumonitis Chronic parotitis (unilateral) No disease	Biopsy of lung Biopsy nasal bones Gland biopsy Lung biopsy Lung biopsy Gland biopsy
2	Negative	No	Sarcoidosis — 2 cases	Patients in long clinical remission
18	Negative	No (clinically negative test sites at 6 weeks)	Pulmonary tuberculosis — 9 cases Tuberculous adenitis Pulmonary fibrosis Lupus erythematosus Mycosis fungoides Pulmonary berylliosis Emphysema Regional enteritis Bronchogenic carcinoma Chronic interstitial pneumonitis	Sanatorium patients Positive culture Lung biopsy Positive patch tests and work histories Lung biopsy Lung biopsy
2	Borderline (see text)	Yes	Erythema nodosum (bromides?) Erythema induratum (?) (Darier-Roussy sarcoidosis)	Papules present at test sites when excised in 6 weeks

Patients Having Positive Kveim Tests. The tests were positive, by the single criterion mentioned, in 40 patients, and in all 40, diagnoses of active sarcoidosis were made independently of the tests. Table 2 lists some of the features of the group as determined up to the time of excision of the test sites. Table 3 indicates the durations of the tests prior to excision.

TABLE 2
Data on 40 Patients Who Had Positive Kveim Tests

Race	No. of Cases	Age		Skin Lesions			Diagnostic Biopsy Performed (Lung, Lymph Nodes, Liver, Skin, etc.)
		Under 40	Over 40	Superficial Plaques	Deep Nodules	Erythema Nodosa	
White	24	19	5	1	3	3	11
Negro	16	14	2	—	4	—	8

Race	Roentgenogram of the Chest				Peripheral Lymph-adenopathy	Extensive Tuberculous Investigation
	Enlarged Nodes Only	Parenchymal Lesions Only	Enlarged Nodes and Parenchymal Lesions	Normal Chest		
White	16	1	7	—	5	6
Negro	9	1	5	1	7	6

Race	Symptoms		Estimated Duration of Disease When Tested				Tuberculin Sensitivity			Disease Found by Survey Chest X-ray	
	Primarily Pulmonary	Systemic	None	Over 5 yr.	1-5 yr.	Under 1 yr.	Not Known	+ to P.P.D. 0.005 mg.	— to P.P.D. 0.005 mg.		Not Known
White	5	8	11	4	7	8	5	1	10	13	8
Negro	1	11	5	2	5	3	6	1	9	6	1

TABLE 3
Durations of Positive Tests Prior to Excision

Time of Excision of Test Site	No. of Patients		
	White	Negro	Total
In the 4th week	1	0	1
5th	1	1	2
6th	9	5	14
7th	4	3	7
8th	3	2	5
9th	1	0	1
10th	1	1	2
11th	0	2	2
12th	1	1	2
Over 12 weeks	3	1	4
<hr/>			
TOTAL	24	16	40

The cases in this group include a wide range of clinical types of sarcoidosis of varying degrees of acuity and causing varying degrees of disability. Some cases presented many of the classic features of the disease including splenomegaly, leukopenia, elevated serum globulin, generalized lymphadenopathy, and cutaneous lesions. Three patients (white women) were acutely ill with uveo-parotid fever when tested. At the other extreme were several patients who were completely asymptomatic, without abnormal physical or hematologic findings, but with abnormal findings on x-ray examination of the chest (hilar gland enlargement). The disease was discovered in nine such patients following routine x-ray examinations of the chest; in follow-ups of these patients it was found that either they developed other manifestations of the illness, or they experienced a remission of the disease as evidenced by clearing of the abnormal pulmonary shadows.

Patients Having Negative Kveim Tests. The tests were initially negative in 46 patients. Four patients, who previously had developed a positive test, were retested when the disease entered a clinical remission (spontaneous remission in two patients and related to treatment in two others). On retesting, no reaction developed at the test sites either clinically or histologically.

Five patients with previously active sarcoidosis were tested while in remissions of six months' to five years' duration, and the tests were negative. One patient with established sarcoidosis and one with suspected sarcoidosis were tested while entering a remission, as judged by clinical follow-up and x-ray examination. The tests were negative. In two patients with apparently active sarcoidosis the tests were negative. In one of these, biopsy of the lung was only suggestive of sarcoidosis.

Of the remaining 37 patients, some were known to have diseases other than sarcoidosis when tested (control patients) and the others proved, after completion of investigative studies, to have diseases other than sarcoidosis. Two of these patients each developed a papule at the test site, but serial section of the entire excised lesion in each case failed to reveal a tuberculoid reaction. Thirty-five

patients failed to develop a reaction at the test site. Seventeen of these "clinically negative" test sites were excised and revealed normal skin. Eighteen were not excised, but the tests were considered negative on clinical grounds.

Borderline Reactions. In the majority of test sites, the histologic reaction was distinct. The tuberculoid characteristics of the positive Kveim test were readily recognized, while negative tests usually revealed normal skin or a mild inflammation. Two cases were seen in each of which the infiltrate, while chiefly lymphocytic, had, in some areas, a poorly defined, questionable tuberculoid reaction (fig. 5). They had, in essence, more reaction than the usual negative test, but did not have a sufficient or clear-cut tuberculoid response as that found in the usual positive test. Neither patient had sarcoidosis as far as could be determined.

It is reasonable to expect a certain proportion of nonspecific and atypical reactions in a test dependent on the response to injection of a foreign substance. It is therefore surprising that in the present study these reactions that are so difficult to classify have been the exception rather than the rule.

Control Antigens. Normal lymph node and normal spleen suspensions were prepared in the same manner as was the Kveim antigen. There were no

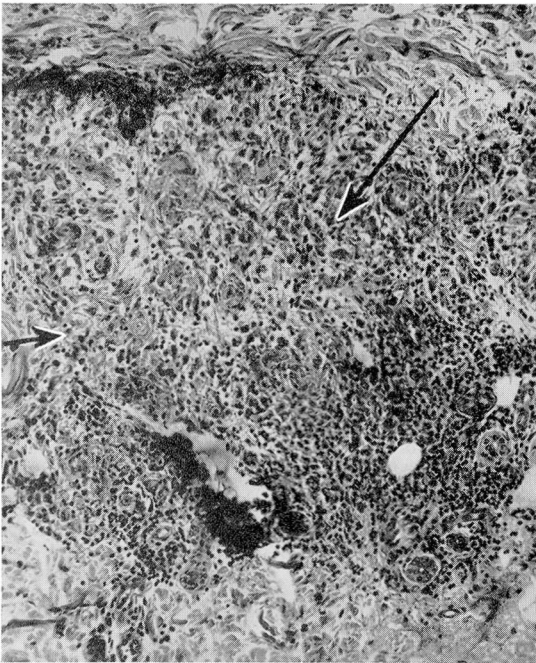


Fig. 5. Borderline reaction (see text). Poorly defined epithelioid cell and lymphocytic response to the antigen. Such responses have been quantitatively small and granulomatous in appearance but do not resemble sarcoidosis. X 135.

clinical or histologic reactions to the injection of normal node suspension in 11 patients who developed positive reactions to the sarcoid node suspension. Under similar circumstances, normal spleen suspension gave no reaction in three cases, while in two others, a small infiltration was present at six weeks, which histologically revealed a mild inflammatory infiltrate.

DISCUSSION

The results of this study support the original opinion of Kveim¹ and the subsequent experience of Danbolt^{10-12,15} that the test is useful in the diagnosis of sarcoidosis. It seems preferable to base the interpretation of a positive test solely on the histologic reaction rather than on the evolution of the resulting cutaneous lesion as suggested by Danbolt.¹⁵ By the histologic criterion, false positive papules are detected early, and the atypical positive reactions with long latent periods that have been reported in certain tuberculoderms⁹ would be considered negative.

The results of the present investigation would suggest that the presence of a tuberculoid reaction resembling sarcoidosis at the Kveim test site in six weeks (i.e. a positive test) is strong evidence that the patient has active sarcoidosis. The absence of such a reaction (assuming the antigen is potent) would suggest that the patient either does not have sarcoidosis, or that the proliferative phase of sarcoidosis is in remission.

There have been no cases of delayed papules in the present series. If the test was clinically negative at six weeks (i.e. no papule or palpable infiltration at the test site) it remained negative in the few cases in which the test site was not excised.

The scars following the excision of positive and negative tests have been normal. No instances of an untoward local reaction either before or after excision have been encountered in this study.

The lack of response to a suspension of normal lymph nodes is generally agreed upon by all investigators. This investigation, as well as Danbolt's, has been unable to confirm the report that normal spleen suspension produced reactions similar to those produced by the sarcoid-tissue suspension.

Two of the patients with active sarcoidosis had positive tuberculin tests. The results of the Kveim test in these two were in no way different from the results in the tuberculin negative group with active sarcoidosis.

SUMMARY

Kveim tests were performed on 88 patients. The tests were positive in 40 patients, all of whom had sarcoidosis in a clinically active phase. In four of these, a second test was negative when the disease entered a remission.

The tests were initially negative in six patients with sarcoidosis in a remission or entering it; in two patients with suspected sarcoidosis in a clinically active

phase; in one patient with clinically active sarcoidosis entering a clinical remission; and in 37 patients with other diseases.

The tests were difficult to interpret in two patients.

The majority of the test sites were excised in the sixth, seventh, or eighth week.

A positive test was based on the histologic demonstration in the excised test site of a tuberculoid reaction resembling sarcoidosis.

References

1. Kveim, A.: Preliminary report on new and specific cutaneous reaction in Boeck's sarcoid. *Nord. med.* 9:169-172 (Jan. 18) 1941.
2. Bjornstad, R. B.: Intracutaneous tests with killed tubercle bacilli in patients with sarcoid. *Acta dermat.-venereol.* 28:174-185, 1948.
3. Leider, M. and Sulzberger, M. B.: Studies in allergy of infection; responses of skin to BCG vaccination in various categories of tuberculin sensitivity. *J. Invest. Dermat.* 13:249-264 (Nov.) 1949.
4. Leider, M. and Hyman, A. B.: Studies in allergy of infection; histologic responses of skin to BCG vaccination in various categories of tuberculin sensitivity. *J. Invest. Dermat.* 14:459-470 (June) 1950.
5. Nelson, C. T.: Observations on Kveim reaction in sarcoidosis of American Negro. *J. Invest. Dermat.* 10:15-26 (Jan.) 1948.
6. Nelson, C. T.: Kveim's reaction in sarcoidosis. *Arch. Dermat. & Syph.* 60:377-387 (Sept.) 1949.
7. Putkonen, T.: Über die Intrakutanreaktion von Kveim (KvR) bei Lymphogranulomatosis benigna und über das Bild dieser Krankheit im Lichte der Reaktionsergebnisse. *Acta dermat.-venereol.* (supp. 10) 23:1-194, 1943.
8. Putkonen, T.: Über die Kveimreaktion bei Lymphogranulomatosis benigna. Mit einen Beitrag zur Thermostabilität und Haltbarkeit des Antigens. *Acta dermat.-venereol.* (fasc. 5) 25:393-410 (March) 1945.
9. Putkonen, T.: Case of skin tuberculosis with positive Kveim's reaction as late as five years after injection of antigen. *Acta dermat.-venereol.* (supp. 29) 32:294-296, 1952.
10. Danbolt, N.: On Kveim's reaction in Boeck's sarcoid. *Acta med. Scandinav.* 114:143-158, 1943.
11. Danbolt, N. and Nilssen, R. W.: Investigations on course of Kveim's reaction and its clinical value. *Acta dermat.-venereol.* (fasc. 6) 25:489-502 (March) 1945.
12. Danbolt, N.: On the antigenic properties of tissue suspensions prepared from Boeck's sarcoid. *Acta dermat.-venereol.* 28:151-157, 1948.
13. Leider, M.: Kveim test in sarcoidosis; theory, meaning and practical value of skin tests and reactions in sarcoidosis. *J. Invest. Dermat.* 10:377-387 (May) 1948.
14. Danbolt, N.: Progressive papule caused by injection of sarcoid tissue suspension (Kveim's test) in patient with Boeck's sarcoid. *Transactions of Norwegian Dermatological Society for 1948, Acta dermat.-venereol.* 31:446-448, 1951.
15. Danbolt, N.: On skin test with sarcoid-tissue-suspension (Kveim's reaction). *Acta dermat.-venereol.* 31:184-193, 1951.
16. Wade, H. W.: Leprosy and sarcoid; Kveim test in leprosy patients and contacts. *J. Invest. Dermat.* 17:337-347 (Dec.) 1951.
17. Sondergaard, A.: Kveims reaktion anvendt ved diagnosen af den pulmonale form af lymphogranulomatosis benigna (schaumann). *Ugeskrift f. Læger* 113:1412-1415 (Oct. 18) 1951.
18. Dupont, A.: Intérêt de l'intra-dermo-réaction à l'antigène de Kveim pour le diagnostic des cas douteux de maladie de Besnier-Boeck-Schaumann. *Arch. belges dermat. et syph.* 7:32-34 (March) 1951.
19. Williams, R. H. and Nickerson, D. A.: Skin reactions in sarcoid. *Proc. Soc. Exper. Biol. & Med.* 33:403-405 (Dec.) 1935.