

THE USE OF RADIOACTIVE PHOSPHORUS* IN THE DETECTION OF INTRAOCULAR TUMORS

ROSCOE J. KENNEDY, M.D.,
Department of Ophthalmology

OTTO GLASSER, Ph.D.
Department of Biophysics

and

PHILIP KAZDAN, M.D.**

INTRAOCULAR tumors often present a difficult diagnostic problem that involves the important decision of whether or not to enucleate an eye. When the eye that is suspect is the better of the two, the decision is critical. Radioactive phosphorus (P^{32}) was used as a diagnostic aid in 24 cases of intraocular lesions. The purpose of this report is to present the findings in this group.

Radioactive phosphorus was used by Low-Beer¹ in 1946, in the detection of tumors of the breast. In 1949, Selverstone, Solomon and Sweet² reported its value in the location of tumors of the brain. As concerns the eye, in 1951 Dunphy and Selberstone³ showed that P^{32} concentrated in the vascular more than in the nonvascular tissues and intraocular fluids.

The use of P^{32} intravenously in the detection of intraocular tumors was first reported by Thomas, Krohmer and Storaasli,⁴ who published findings in eight cases in 1952. Others have since reported their experiences.⁵⁻⁷

TECHNIC

P^{32} is used because it emits a beta radiation that easily can be detected with a Geiger counter. The average range of these beta rays in penetration of tissue is 2 mm., although the most penetrating may travel as deep as 6 mm. The half-life of the isotope is 14.3 days.

Eyes were anesthetized with 0.5 per cent tetracaine (pontocaine) hydrochloride. Five-hundred microcuries (0.5 millicuries) of sterile P^{32} (in saline solution) was then injected intravenously and counts were started immediately over the suspected area, and a corresponding area in the unaffected eye. An end-window Geiger tube of 6-mm. diameter was used and held directly against the sclera (fig. 1). One must be careful not to hold the Geiger tube over a rectus muscle, as this will have the undesirable effect of artificially increasing the count. Haigh and Reiss⁸ have shown that intravenous P^{32} shows its greatest concentration in the uveal tract and rectus muscles soon after injection, and then levels

* The radioactive phosphorus used was supplied by Abbott Laboratories on authorization from the Isotopes Division, U. S. Atomic Energy Commission.

** Former Fellow in the Department of Ophthalmology; now at City Hospital, Cleveland, Ohio.

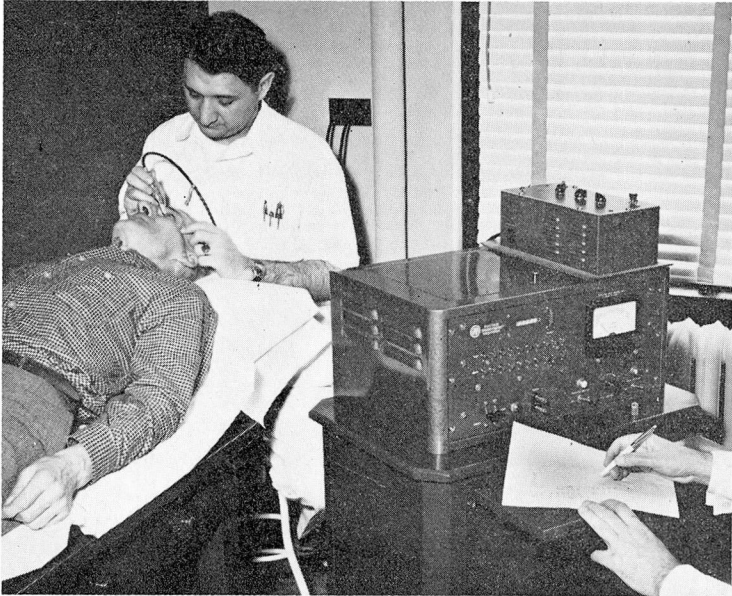


Fig. 1. The Geiger tube is being applied to the sclera.

off and finally gradually falls in concentration as the tracer is removed from the blood. Localization of the suspected lesion by ophthalmoscopic examination is important before starting the test, so that the counter can be applied as nearly as possible over the lesion site.

Counts on the Geiger scaler were taken for one hour at one-minute intervals. In some cases counts over both eyes were also taken after 24 hours, since the diagnosis of neoplasm is definitely indicated if the higher uptake in the affected eye is maintained for 24 hours.

The concentration of P^{32} in tumor tissue is illustrated by a radioautograph

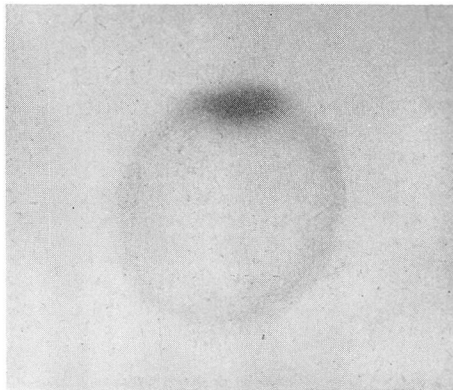


Fig. 2. Radioautograph illustrating the concentration of P^{32} in tumor tissue.

DETECTION OF INTRAOCULAR TUMORS

(fig. 2). Just what factors produce the increased count in a tumor are not known. One seems to be increased metabolic activity (phosphate turnover) of the nucleoproteins of the tumor; another may be vascularity of the tumor. Bettman and Fellows⁶ have shown that vascularity is one important factor; they reported a higher count in a portion of a melanoma that was extremely vascular as compared with that in a much less vascular part of the same tumor.

RESULTS

A total of 24 cases was studied. The clinical diagnosis and the positive or negative character of the selective uptake ratio for each case are listed in the

TABLE
Findings with Intravenous P³² in 24 Cases of Intraocular Lesions

Clinical Diagnosis	No. of Cases	Character of Selective Uptake Ratio (P ³² Isotope)	
		Initial	24 hr.
Melanosarcoma	7	+	+
	3	—	—
Metastatic carcinoma	1	+	Not done
Retinoblastoma	1	+	+
Melanoma iris	1	—	—
Thinning of sclera with ciliary body showing through	1	—	Not done
Retinal detachment	4	—	—
Retinal detachment with massive hemorrhage	1	+	Not done
Intraocular hemorrhage	1	—	—
Choroiditis	3	—	Not done
Macular cyst	1	—	—
	Total		
	24		

table. The selective uptake ratio was recorded as the ratio of the count in the affected eye to that over a corresponding area in the unaffected eye. Roughly two thirds (seven of ten) of the melanosarcomas initially had a positive P³² uptake ratio that remained high at the end of 24 hours. Three cases of melanosarcoma had low uptake ratios that were considered not diagnostic. The lesions

MELANOSARCOMA, CILIARY BODY O.D.

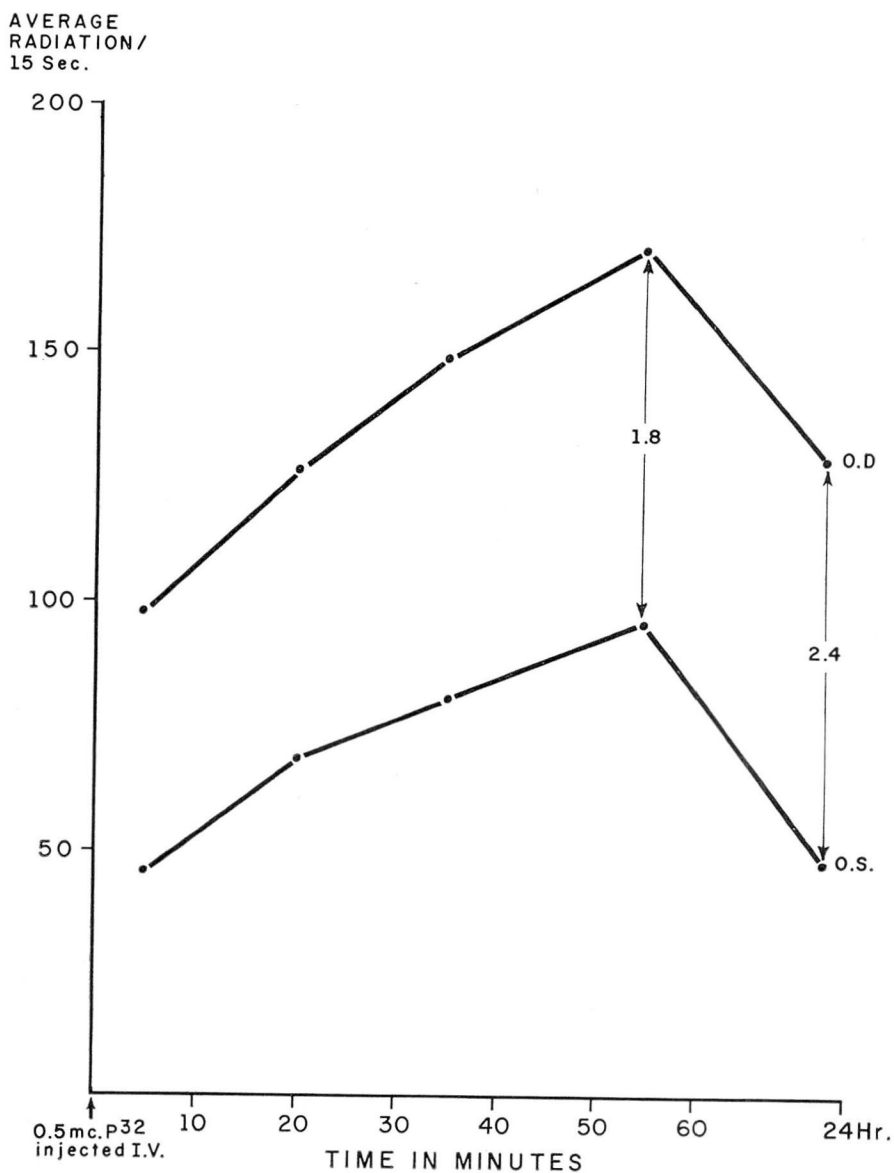


Fig. 3

DETECTION OF INTRAOCULAR TUMORS

in these three cases were small and posteriorly situated. One retinoblastoma had a strongly positive uptake ratio initially and at the end of 24 hours. One metastatic carcinoma initially had a strongly positive uptake ratio. One falsely positive initial result was recorded from a retinal detachment with massive hemorrhage. Observations were not done at 24 hours in these two cases. The 11 remaining were cases of non-neoplastic lesions showing no abnormal distribution of P^{32} .

Krohmer and his associates⁷ state from their figures on anterior segment lesions that a selective uptake ratio of 1.4 or higher is very suggestive of tumor, while a selective uptake ratio of less than 1.2 is good evidence of a non-neoplastic

MALIGNANT MELANOMA POSTERIOR O.D.

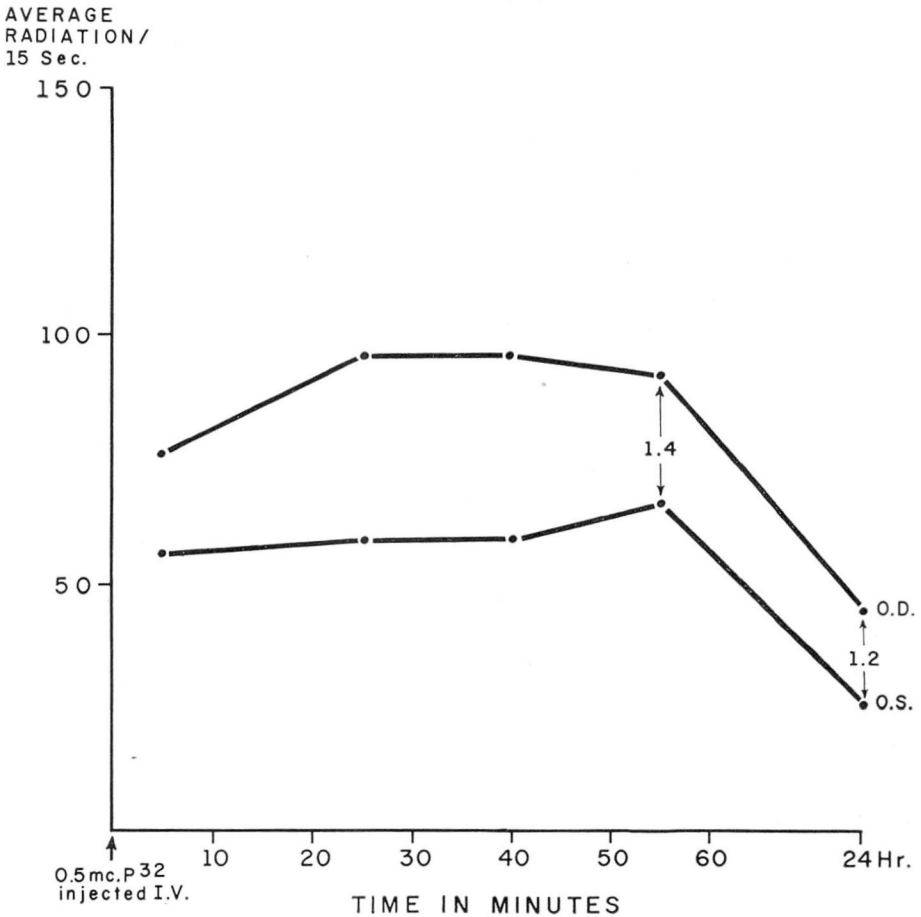


Fig. 4

METASTATIC CA. TO O.D.
(^{131}I Bronchogenic Ca.)

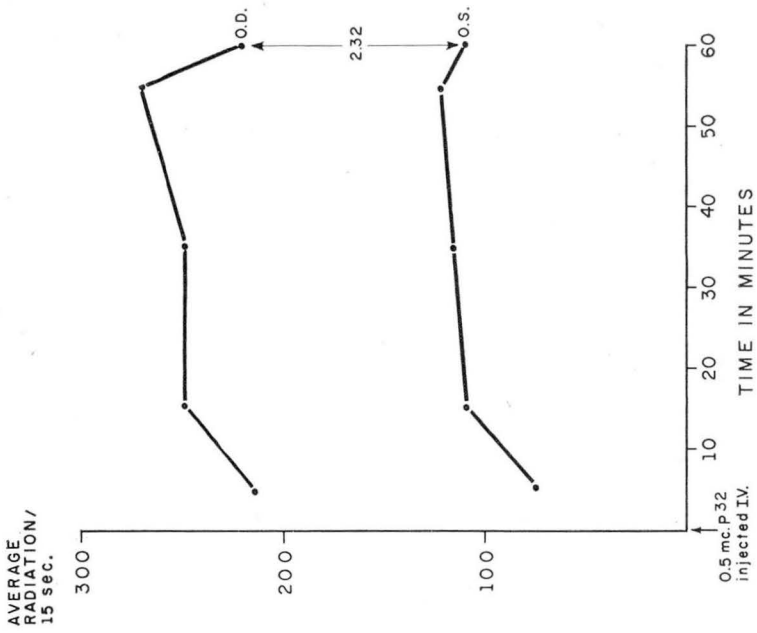


Fig. 6

SEROUS RETINAL DETACHMENT O.D.

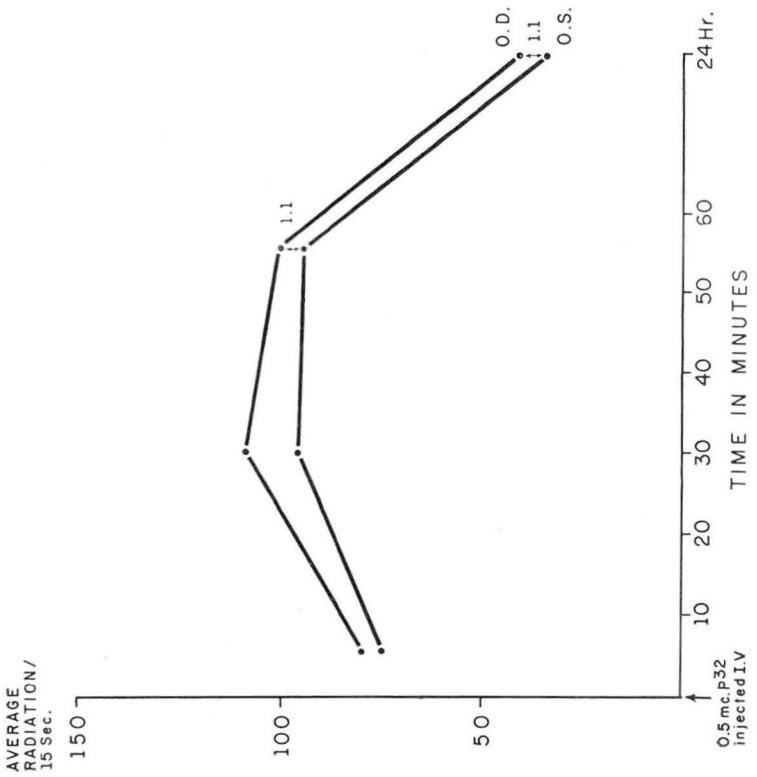


Fig. 5

DETECTION OF INTRAOCULAR TUMORS

- METASTATIC (Bronchogenic Ca) TO O.D.
- MELANOSARCOMA OF CILIARY BODY O.D.
- - - - ● MALIGNANT MELANOMA O.D.
- - - - ● SEROUS RETINAL DETACHMENT O.D.

SELECTIVE UPTAKE RATIO : $\frac{\text{AFFECTED}}{\text{UNAFFECTED}}$

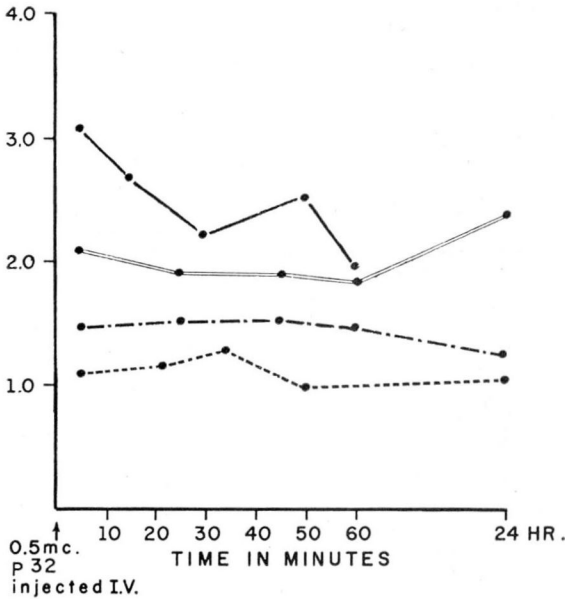


Fig. 7

process. When a tumor is located posteriorly, it is relatively inaccessible and it is difficult to place the counter in close apposition to it, so that selective uptake ratios are elevated over the eye, but only moderately so. This is demonstrated by comparison of figures 3 and 4. Figure 3 illustrates the uptake ratios of a melanosarcoma of the ciliary body which had an initial selective P³² uptake ratio of 1.3 rising to 2.4 at 24 hours. Figure 4 shows the uptake ratios of a posterior malignant melanoma. Here, the initial selective uptake ratio was 1.4 and at 24 hours 1.2.

Figure 5 shows nearly equal uptakes in the affected and unaffected eyes of a patient having retinal detachment.

Figure 6 shows a strongly positive P³² uptake of radiation by a metastatic lesion of bronchogenic carcinoma.

Figure 7 is a composite chart that illustrates the selective uptake ratios of four lesions. The ratio of 2.4 at the end of 24 hours of the anterior segment melanoma is clear evidence of a neoplastic process. The ratio of 1.2 of the posterior segment melanoma is a moderate elevation, and the ratio of 1.1 of the non-neoplastic lesion (retinal detachment) is not significant. The metastatic

carcinoma had a higher selective uptake ratio than that of a primary tumor of the eye.

APPLICATIONS

In all suspected cases of intraocular neoplasm, and in certain cases of retinal detachment, especially when a tear is lacking, this test is indicated.

Intravenous P^{32} may be of diagnostic aid in one-eyed persons if the lesion is so placed that counts can be made over comparable affected and unaffected areas in the same eye.

SUMMARY

Twenty-four intraocular lesions were examined by Geiger counter after intravenous injection of P^{32} . Non-neoplastic lesions (11) caused no inequality in localization of P^{32} . A significant increase in uptake of P^{32} was observed over nine lesions in eyes affected by malignant neoplasms. No significant increase was detected in three cases of melanosarcoma, apparently because the site of the tumor could not be approached with the counter.

It would appear from these results that P^{32} is a useful diagnostic aid in intraocular tumors, especially when the lesions involve the anterior half of the eye where a positive finding with P^{32} is of utmost importance. However, if the lesion involves the posterior half of the eye, a negative result does not rule out the presence of tumor, and for diagnosis one must still rely upon clinical findings and observations.

References

1. Low-Beer, B. V. A.: Surface measurements of radioactive phosphorus in breast tumors as possible diagnostic method. *Science* **104**: 399 (Oct. 25) 1946.
2. Selverstone, B., Solomon, A. K. and Sweet, W. H.: Location of brain tumors by means of radioactive phosphorus. *J.A.M.A.* **140**: 277-278 (May 21) 1949.
3. Dunphy, E. B. and Selberstone, B.: Distribution of radioactive phosphorus in ocular tissue. *Society Proceedings, The New England Ophthalmological Society, Am. J. Ophth.* **34**: 1603 (Nov.) 1951.
4. Thomas, C. I., Krohmer, J. S. and Storaasli, B.: Detection of intraocular tumors with radioactive phosphorus; a preliminary report with special reference to differentiation of the cause of retinal separation. *A.M.A. Arch. Ophth.* **47**: 276-286 (March) 1952.
5. Dunphy, E. B., Dreisler, K. K., Cadigan, J. B. and Sweet, W.: The uptake of radioactive phosphorus by intraocular neoplasms. *Am. J. Ophth.* **37**: 45-54 (Jan.) 1954.
6. Bettman, J. W. and Fellows, V.: Radioactive phosphorus as a diagnostic aid in ophthalmology. *A.M.A. Arch. Ophth.* **51**: 171-179 (Feb.) 1954.
7. Krohmer, J. S., Thomas, C. I., Storaasli, J. P. and Friedell, H. L.: Detection of intraocular tumors with the use of radioactive phosphorus. *Radiology* **61**: 916-921 (Dec.) 1953.
8. Haigh, C. P. and Reiss, M.: Diagnostic and therapeutic uses of radioactive isotopes: symposium; some applications of I^{131} and Na^{24} to clinical diagnoses. *Brit. J. Radiol.* **23**: 534-541 (Sept.) 1950.