

# THROMBOANGIITIS OBLITERANS: OCCURRENCE IN A BROTHER AND A SISTER

WILLIAM R. BIDDLESTONE, M.D.\*

and

FAY A. LeFEVRE, M.D.

Department of Cardiovascular Disease

**T**HROMBOANGIITIS obliterans has been observed in sisters,<sup>1-8</sup> in brothers,<sup>9,10</sup> and in father and son,<sup>11</sup> but to our knowledge this report is the first of its occurrence in brother and sister. In early adult life, both had symptoms and signs of peripheral vascular disease. The clinical findings were typical of thromboangiitis obliterans.

## CASE REPORTS

**Case 1.** A 30 year old man of Bohemian descent was examined in April 1942 because of a three-year history of recurrent ulcer of the toe and intermittent claudication at the level of the calf. Examination revealed color and temperature changes in both feet. There was an ulcer on the great toe of the right foot. The pulses of the feet were absent bilaterally. There was no evidence of diabetes. The patient had been smoking approximately 30 cigarettes per day for 12 years. He stopped smoking, was placed on conservative management, and obtained relief of symptoms.

Following this observation, the patient was seen on five separate occasions over a 12-year period because of exacerbations of the vascular disease. These are briefly outlined below. Each recurrence was preceded by a period of smoking, although he had been repeatedly warned not to smoke.

Twenty-one months after first examination (January 1944) the patient returned because of pain and swelling of the middle finger of the right hand. Oscillometric readings at the wrist level were reduced. A subungual abscess was incised and drained, and again the patient's symptoms subsided with conservative treatment.

He was next seen in December 1948, approximately six and a half years after the initial examination. He complained of a severe retrosternal pain. The electrocardiogram showed changes consistent with acute posterior myocardial infarction. The suspected cause of the infarction was thromboangiitis obliterans.

In March 1950, nine years after initial examination, he returned because of pain and an ulcer in the great toe of the left foot. Treatment with debridement, caudal blocks, and antibiotics relieved the symptoms, but they recurred in October of 1950. A left lumbar sympathectomy and sequestrectomy of the great toe of the left foot were performed in January 1951, and the distal phalanx of the great toe of the right foot was removed in March 1951.

---

\* *Fellow in the Department of Medicine.*

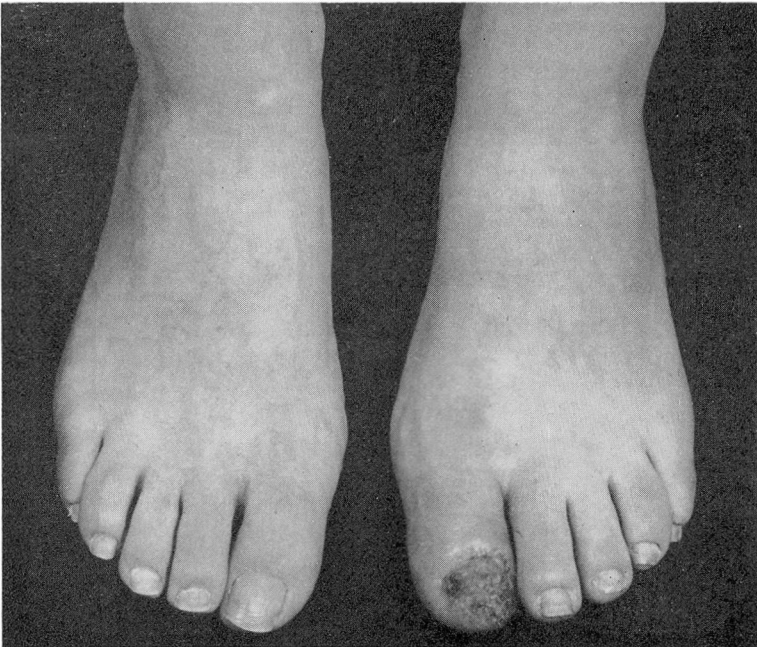
He was not seen again until June 1953, approximately 11 years after his initial visit, when he returned because of pain and a recurrence of the ulcer in the great toe of the left foot of one week's duration. At this time he could walk one block without leg pain. When exposed to cold, the fifth digit of the right hand turned pale, and when he walked rapidly, retrosternal pain developed which was relieved by rest and nitroglycerine. He had been smoking 20 cigarettes per day.

**Case 2.** In May 1954, a 33 year old housewife, the sister of the patient discussed in case 1, was first examined because the great toe of the left foot had become infected as a result of an ingrown toenail. The infection had begun six months previously, and had not responded well to local therapy. The infection continued to drain seropurulent material.

She had no prior history of foot ulcers, diabetes, or varicose veins. During the past two years she had noted that exposure to cold caused the fingers to blanch and to become numb.

She had smoked 20 cigarettes per day since the age of 25 years.

Physical examination revealed a dusky cyanosis of the fingers and toes. There was an area of gangrene on the great toe of the left foot (fig. 1), and an area of discoloration and desquamation of the left heel, which appeared to be an incipient ulcer. The posterior tibial and dorsalis pedis pulses were absent bilaterally. Oscillometric readings were 0 in both feet, and  $\frac{3}{4}$  in the right and  $\frac{1}{2}$  in the left ankle. The Allen test revealed obstruction of the right ulnar artery.



**Fig. 1.** (Case 2) Note area of gangrene involving left great toe.

The patient was admitted to the hospital where she was treated with left lumbar sympathetic blocks, antibiotics, and local foot care. She stopped smoking completely.

Her condition was much improved after three weeks of treatment. She was discharged and conservative treatment was continued at home. The patient was last seen in September 1954; at that time, although the pulses were not palpable in the left foot, it was warm and the color had greatly improved.

## COMMENT

We believe that the diagnosis of thromboangiitis obliterans is substantiated in each of our cases by the history and the clinical findings, although confirmation by pathologic examination is not available.

A diagnosis of Raynaud's disease must be considered in young adults, especially women, who have symptoms of peripheral vascular disease. In both of our cases a diagnosis of Raynaud's disease was excluded because of the absence of major arterial pulsations. The possibility of arteriosclerosis obliterans was eliminated because of the young age of both patients; in addition, examination of the fundi revealed no signs of arteriosclerosis, and roentgenograms of the lower extremities demonstrated no evidence of arterial calcification.

The bases of the diagnosis of thromboangiitis obliterans in each patient were: young age; history of having been a heavy smoker for many years; absence of major pulsations including those of the upper as well as of the lower extremities; temperature and color changes; and painful ulcers. In addition, the marked improvement in symptoms in each patient when smoking was stopped further substantiated the diagnosis, since this manifestation is most frequently encountered in thromboangiitis obliterans.

## CONCLUSION

The occurrence of thromboangiitis obliterans in a brother and a sister supports the belief that heredity plays a role in the susceptibility of the arteries to this disease.

## References

1. Horton, B. T. and Brown, G. E.: Thrombo-angiitis obliterans among women. *Arch. Int. Med.* **50**: 884-907 (Dec.) 1932.
2. Herrell, W. E. and Allen, E. V.: Thrombo-angiitis obliterans in women. *Am. Heart J.* **12**: 105-108 (July) 1936.
3. Millman, S. J.: Thromboangiitis obliterans in woman. *Am. Heart J.* **15**: 746-748 (June) 1938.
4. Atlas, L. N.: Case of Buerger's disease in an old woman. *Am. Heart J.* **26**: 120-123 (July) 1943.
5. LeFevre, F. A. and Burns, J.: Thromboangiitis obliterans in women; report of 2 cases. *Cleveland Clin. Quart.* **11**: 49-52 (April) 1944.

## THROMBOANGIITIS OBLITERANS

6. Williams, W. S. and Barker, N. W.: Thrombo-angiitis obliterans among women: report of 2 cases. Proc. Staff Meet., Mayo Clin. **21**: 55-58 (Feb. 6) 1946.
7. Silbert, S.: Further experience with thromboangiitis obliterans in women. Am. Heart J. **36**: 757-771 (Nov.) 1948.
8. Wilensky, N. D. and Collens, W. S.: Thrombo-angiitis obliterans in sisters. J.A.M.A. **110**: 1746-1747 (May 21) 1938.
9. Samuels, S. S.: Incidence of thrombo-angiitis obliterans in brothers. Am. J. M. Sc. **183**: 465-467 (April) 1932.
10. Martorell, F.: Thromboangiitis obliterans in 2 brothers. Angiology **3**: 271-274 (Aug.) 1952.
11. Weber, F. P.: Thrombo-angiitis obliterans in father and son. Lancet **2**: 72-73 (July 10) 1937.