

FIFTY PER CENT UROKON SODIUM* AS AN INTRAVENOUS UROGRAPHIC CONTRAST MEDIUM

A Study Based on 250 Cases

WILLIAM C. STRITTMATTER, M.D.
Department of Roentgenology

INTRAVENOUS urography is a safe, relatively simple procedure that offers much valuable information about the form and the functioning of the urinary tract and its neighboring structures. For these reasons it frequently is employed as a diagnostic measure. Although several commercially available contrast media give good visualization of the urinary tract and cause few postinjection reactions, new preparations constantly are being sought which will improve visualization and further decrease the likelihood of untoward reactions.

The medium that we have been testing, Urokon sodium (sodium 3-acetylamino-2,4,6-triiodobenzoate), is a brand of sodium acetizoate. The dry salt is a white crystalline powder that is soluble in water. Urokon sodium has been thoroughly investigated both as a 30 per cent and as a 70 per cent solution and has been found to be satisfactory as a contrast medium. It now is commercially available as a 50 per cent solution. Because of the higher concentration of iodine, visualization of the urinary tract should be better than with the 30 per cent solution. Fifty per cent Urokon contains 65.8 per cent iodine by weight, which is more iodine than is in Hypaque (59.8 per cent), in Diodrast (48.9 per cent), or in Neo-Iopax (51.5 per cent).

Procedure

A series of 250 consecutive ambulatory outpatients were used in this study. There were 147 males and 103 females who were from 11 to 80 years of age and from 76 to 305 pounds in weight.

A *urogram survey sheet* was made out for each patient who was sent to the Department of Roentgenology for urographic study. On the sheet were recorded the patient's Clinic number, age, race, weight, and sex. The common allergies and those reactions most frequently seen following injection of urographic contrast media were listed on the survey sheet, and a history of these was noted prior to injection of the medium. On the same survey sheet were later recorded the length of time allowed for injecting the Urokon, the presence of any post-injection reactions experienced by the patient, and the rating of the urograms for diagnostic quality.

*The Urokon sodium used in this study was kindly supplied by Mr. B. A. Parker of Mallinckrodt Chemical Works, 3600 N. Second St., St. Louis 7, Mo.

The urographic series for each patient consisted of five films, the first two of which were exposed 5 and 15 minutes, respectively, after injection of the medium, with abdominal compression in place. The compression was then removed and 16- and 30-minute films were exposed. A 30-minute film centered over the bladder area also was made.

Reactions

Twenty-three (9.2 per cent) of the 250 patients gave a history of previous allergies, enumerated as follows: hay fever, 11; asthma, 3; food allergy, 3; drug allergies, 4; hives and eczema, 1 each. Of those 23 patients, 15 had one or more reactions to the injection of 50 per cent Urokon. Of the 227 patients without known allergies, 111 (approximately 50 per cent) had one or more reactions to the medium. Thus, there was a total of 126 (50.4 per cent) patients who had one or more reactions to 50 per cent Urokon. Table 1 gives an analysis of reactions; those most frequently experienced were nausea, vomiting, and bad taste. Although all were unpleasant, none of the reactions were serious and all promptly subsided without treatment.

TABLE 1
Reactions to 50 Per Cent Urokon Sodium in 126 Patients

Reaction	Incidence
Nausea	67
Bad taste	47
Vomiting	25
Warmth	17
Dizziness	4
Sneezing	3
Flushing	2
Moderate pain	1
Choking	1
Tinnitus	1
Edema (eyelids)	1

Ninety-one patients were given injections over periods of one minute each, and 49 (54 per cent) of these had reactions. Of the remaining 159 patients who were given injections over periods of two minutes each, 77 (48.4 per cent) had reactions. A comparison of these figures indicates that there apparently is no great advantage in using the slower rate of injection.

Diagnostic Rating of Urograms

The technical quality of the urograms was rated according to the criteria devised by Hoppe¹; both the demonstration of morphologic structure of the urinary tract and the density of the shadows were taken into consideration (Table 2). In general the results were good. Ninety-four urograms (37.6 per

UROKON SODIUM

cent) were rated excellent with brilliant shadows, and 113 (45.2 per cent) were rated good.

TABLE 2
Analysis of Urographic Visualization with Urokon Sodium in 250 Patients*

	No. of patients	Per cent of total
<i>A. Morphology of upper urinary tract</i>		
No visualization	0	0
Upper third of either or both ureters faintly visible	4	1.6
Upper third of either or both ureters distinctly visible	6	2.4
Calyces, pelvis and upper ureter of one side visible	17	6.8
Calyces, pelvis and upper ureter distinctly visible on one side with partial visualization on other side	58	23.2
Calyces, pelvis and upper ureters of both sides distinctly visible	165	66.0
Total	250	100.0
<i>B. Only the bladder visible</i>		
	0	0
<i>C. Radiographic quality (density of shadows)</i>		
No visualization	0	0
Poor—shadows barely visible, morphology indistinct	12	4.8
Fair—faint but distinct outlines	31	12.4
Good—distinct shadows of unquestionable diagnostic quality	113	45.2
Excellent—brilliant shadows, structures stand out in bold relief in contrast to surrounding tissue	94	37.6
Total	250	100.0

The excretion of Urokon was prompt as evidenced by the fact that the best concentration of the medium in the upper urinary tract was usually seen on the 5- or 15-minute films in each series. In 118 cases the 5-minute films showed the best concentration; and in 122 cases the concentration was best on the 15-minute films.

Comparison with Hypaque

Root and Strittmatter² recently reported the findings in a series of 350 patients in whom Hypaque was used as the urographic medium. The urogram survey sheets were of the same form as those used in the present study of Urokon. Only 9.7 per cent of the patients receiving Hypaque exhibited any reaction, as compared with the 50.4 per cent who had reactions to injections of 50 per cent Urokon. Visualization of the urinary tract was slightly better with Hypaque: 43.4 per cent showed excellent contrast with brilliant shadows as compared to 37.6 per cent with 50 per cent Urokon. Because of the significantly

*Criteria according to Hoppe.¹

lower percentage of patients having reactions, in addition to the good visualization achieved, Hypaque has become our choice of medium for intravenous urography.

Summary

Intravenous urograms, for which 50 per cent Urokon was used as a contrast medium, were made for a series of 250 Clinic patients. Visualization of the urinary tract was good. The incidence of postinjection reactions (50.4 per cent) was high, although no reactions of a serious nature were encountered. In comparison with 50 per cent Urokon, Hypaque² caused fewer postinjection reactions (incidence, 9.7 per cent) and provided slightly better visualization of the urinary tract.

References

1. A laboratory summary of the chemical and pharmacological properties of Hypaque. Winthrop-Stearns Inc., 1954.
2. Root, J. C. and Strittmatter, W. C.: Hypaque, a new urographic contrast medium. *Am. J. Roentgenol.* 73: 768-770 (May) 1955.

TREATMENT OF CANCER OF THE THYROID WITH DESICCATED THYROID

GEORGE CRILE, JR., M.D.
Department of General Surgery

IN recent years it has been discovered that certain types of goiter diminish in size when patients are given desiccated thyroid. Many large goiters resulting from struma lymphomatosa shrink or even disappear when thyroid is given in doses of 2 to 4 grains daily.¹ Some adenomas of the thyroid and some multinodular goiters get smaller.² Now it appears that some well-differentiated cancers of the thyroid also can be controlled by thyroid feeding.

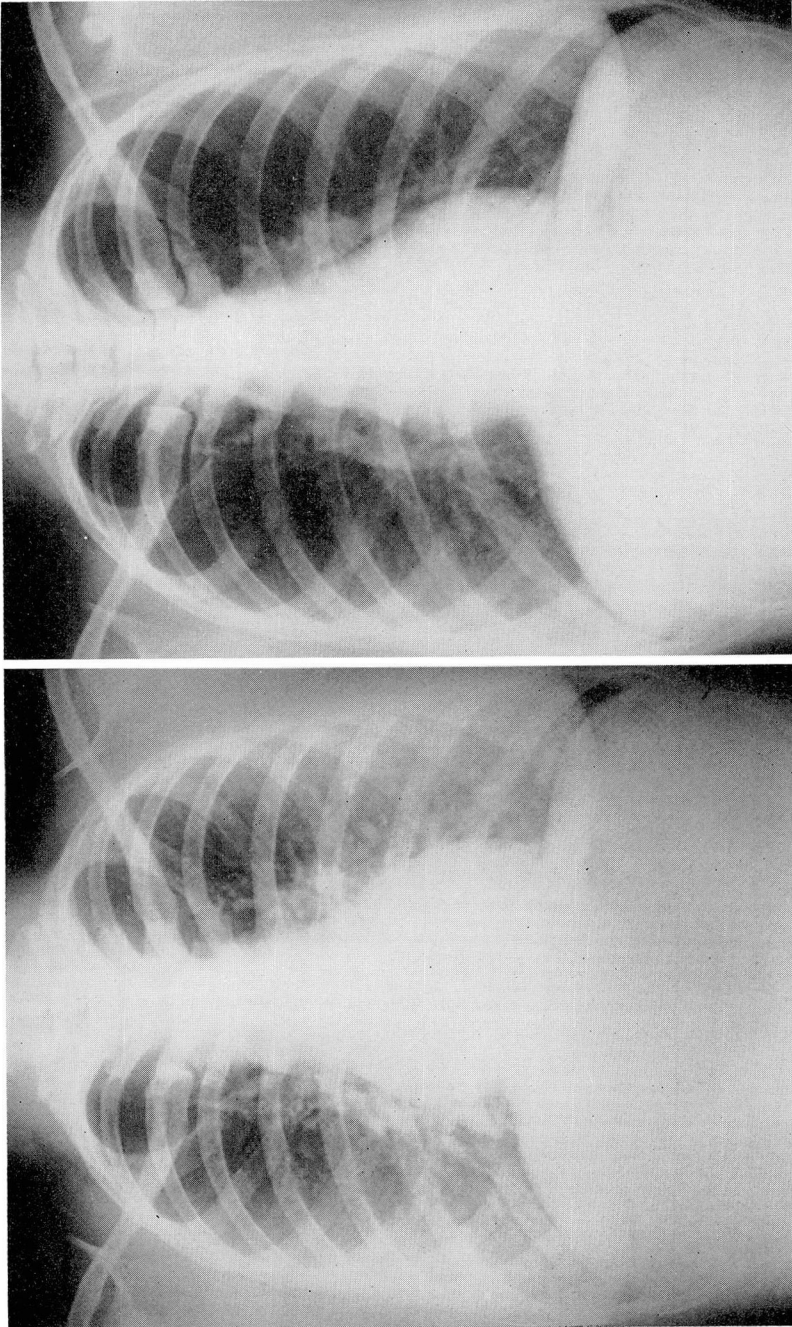
Small doses of thyroid, up to two grains daily, do not appear to have any significant effect upon goiters or cancers. It is necessary to give a full replacement dose of three to four grains daily to obtain favorable results. Presumably such doses of desiccated thyroid furnish so much exogenous thyroid hormone that it is no longer necessary for the thyroid gland to function. The exogenous hormone suppresses the formation of the thyroid-stimulating hormone of the pituitary; and the thyroid, deprived of pituitary stimulation, atrophies. Similar dependency on hormones has been observed in certain cancers of the prostate and breast.

My interest in the dependency of thyroid tumors on pituitary hormones was first awakened eight years ago when I saw a woman with severe hyperthyroidism and an oxyphilic adenocarcinoma (Hürthle cell cancer) of the thyroid that had metastasized to the lungs. Serial roentgenograms of this patient's lungs obtained during the preceding two years showed no increase in the size of the metastatic nodules; in fact, some of them seemed to be getting a little smaller.

I erroneously assumed that the patient's hyperthyroidism was being caused by the cancer, and began treatment with radioactive iodine. Soon the hyperthyroidism was controlled and the patient developed signs of myxedema. At this point the metastatic tumors began to enlarge rapidly, and a few months later the patient died.

In retrospect, it seems clear that the hyperthyroidism had been caused not by the cancer but by hyperfunctioning nonmalignant thyroid tissue. Presumably, the excessive thyroid hormone had suppressed the output of thyroid-stimulating hormone of the pituitary, and this suppression had resulted in an arrest of the growth of the tumor. As soon as the function of the thyroid was destroyed, the resultant deficiency of circulating thyroid hormone stimulated the pituitary. It was the increased output of thyroid-stimulating hormone from the pituitary, that made the cancer grow.

During the next few years I saw several more examples of differentiated thyroid cancers that blossomed and grew rapidly when myxedema had been induced by I¹³¹. The trend of the tumor's growth was promptly reversed when desiccated thyroid was given in doses of three to four grains daily. I now have



A. Metastasis of papillary carcinoma of thyroid to both lungs, most marked in lower lobes. B. (The same case as shown in A.) Roentgenogram taken after four years of treatment with 3 grains of desiccated thyroid daily. No evidence of metastatic carcinoma.

followed five patients with pulmonary metastases of papillary carcinoma treated with desiccated thyroid for from one to five years, and in every case there has been cessation of growth of the carcinoma, as evidenced by improvement in the roentgenographic appearance of the chest or complete disappearance of the tumors both in the neck and in the chest (Figure). Similar results have been reported in England by Balme.³ In two other cases with solitary metastases in bone, there were apparent arrest of the cancer's growth for from one to five years and recalcification during treatment with thyroid and roentgen therapy.

Discussion

For the past three years I have made it a practice to give two to four grains of desiccated thyroid daily to all patients who have had operations for cancer of the thyroid. Since the course of this disease may be extremely slow it is difficult to assess the results. All that can be said at the present time is that there have been no favorable responses to thyroid feeding in patients with highly malignant or undifferentiated cancers of the thyroid. On the other hand, there have been no recurrences of tumors of low malignancy treated with desiccated thyroid even in patients who had only partial removal of extensive papillary carcinomas.

It will take many years to estimate the value of desiccated thyroid in the treatment of low-grade cancers of the thyroid. In the meantime the treatment is inexpensive, harmless, and certainly worth further trial.

To aid in determining the value of treatment with desiccated thyroid in these rare cancers, it would be helpful if those who have had experience with this method would send me summaries of their cases, together with representative slides of the cancers. In this way perhaps we can determine what types of cancer will respond favorably to endocrine therapy.

Summary

Feeding desiccated thyroid in doses of three to four grains daily appears to arrest the growth of papillary carcinomas of the thyroid. In some cases under treatment metastatic nodules in the lungs have disappeared.

References

1. Furr, W. E. and Crile, G., Jr.: Struma lymphomatosa. *J. Clin. Endocrinol. & Metab.* **14**: 79-86 (Jan.) 1954.
2. Greer, M. A. and Astwood, E. B.: Treatment of simple goiter with thyroid. *J. Clin. Endocrinol. & Metab.* **13**: 1312-1331 (Nov.) 1953.
3. Balme, H. W.: Metastatic carcinoma of thyroid successfully treated with thyroxine. *Lancet* **1**: 812-813 (April 17) 1954.