

# BILATERAL THROMBOSIS OF THE INTERNAL CAROTID ARTERY

## *Report of Three Cases*

A. B. EISENBREY, M.D.,\*

A. T. URRUTIA, M.D.\*\*

and

L. J. KARNOSH, M.D.

Department of Neuropsychiatry

SINCE the advent of intracranial angiography the remarkable compensatory capacity of the circle of Willis has been demonstrated in various vascular disorders of the cerebral circulation and particularly in cases of unilateral thrombosis of the internal carotid artery. That patients with bilateral occlusion of this artery could develop collateral circulation sufficient to prevent severe paralysis, blindness and a global aphasia has not been heretofore regarded as a possibility.

It is the purpose of this paper to present case reports of three patients with bilateral thrombosis of the internal carotid artery and to outline some of the clinical features of this condition.

Numerous cases of unilateral thrombosis of this vessel have been reported since arteriography established this circulatory defect as a clinical entity.<sup>1,2,3</sup> The clinical diagnosis in the majority of these cases has been neoplasm, with subdural hematoma or multiple small vascular lesions as secondary considerations. The greatest incidence has been between the ages of 30 and 60 years. Etiologic factors such as thromboangiitis obliterans, syphilis, blood dyscrasias, acute infections and trauma to the neck have been suggested, but in a large autopsy series described by Fisher<sup>1</sup> the cause was found almost without exception to be atherosclerosis.

Early recognition of thrombosis of the internal carotid artery is the exception rather than the rule. The characteristic syndrome of monocular optic atrophy, contralateral homonymous hemianopsia, hemisensory defects and complete hemiplegia is very rarely found. Aphasia, psychiatric disturbances, headaches, visual-field defects and a slowly progressive course are signs that may be associated with the lesion but hardly are considered pathognomonic of either unilateral or bilateral thrombosis.

\*Former Fellow in the Department of Neurological Surgery; now Assistant Resident, Department of Neurosurgery, University Hospitals, Iowa City, Iowa.

\*\*Former Fellow in the Department of Neuropsychiatry; present address Vidrio No. 949, Guadalajara, Jal., Mexico.

The symptoms and signs produced by bilateral occlusion depend on the extent of functioning collateral circulation and the rapidity of onset of the obstruction. The collateral circulation<sup>4</sup> by way of the external carotid artery may be through the external maxillary artery and the external angular artery of the eye to the ophthalmic artery, via anastomoses between the temporal and supra-orbital arteries to the ophthalmic, and by means of intracranial branches of the middle meningeal to the lacrimal and nasociliary arteries, these being branches of the ophthalmic. There is in addition some circulation existing from one side to the other across the midline of the face, oral cavity and scalp. Walsh and Smith<sup>5</sup> state that homolateral blindness is rare with thrombosis of the internal carotid artery because it requires extension of the process into the retinal artery and the excellent collateral circulation in the retrobulbar tissues usually prevents such an involvement. In addition the contribution of the posterior circulation from the basilar artery to the posterior cerebral arteries, to the posterior communicating and posterior choroidal vessels is of great importance, as well as are the smaller communicating channels of the cortex. The usefulness of the anterior communicating artery naturally depends on its capacity and supply from the side having the better volume flow.

Frøvig<sup>6</sup> reported in detail a case of bilateral thrombosis of the common carotid artery in a 20-year-old girl in whom a vertebral artery was hypertrophied and supplied blood to the anterior cerebral vessels, as was demonstrated by angiography. The patient was alive at the time of the report, and resected segments of the carotids revealed complete obstruction, the process being regarded as thromboangiitis obliterans.

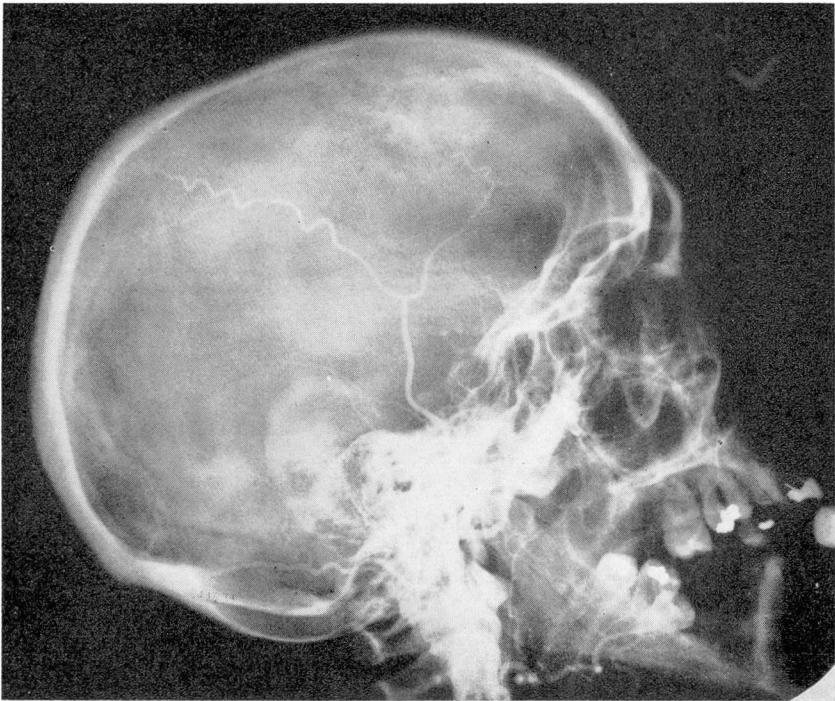
Perhaps the most significant report pertaining to thrombosis of the internal carotid artery is that of Miller Fisher.<sup>1</sup> In a series of 432 autopsies, complete occlusion of one artery was present in 34 and of both arteries in 11. In a review of the histories of these cases the most commonly encountered clinical sign was hemiplegia that developed over one or two days. Signs of cerebral neurologic defect were absent in seven cases of unilateral occlusion, but none of those with bilateral occlusion was free of symptoms. Johnson and Walker<sup>2</sup> in a review of 107 cases (their own and others) of unilateral thrombosis found hemiplegia or hemiparesis in 80 per cent of the cases. The disease was associated with transient episodes of motor or sensory defects in about 40 per cent of the cases and the thrombosis occurred on the left side in 65 per cent.

## CASE REPORTS

**Case 1.** A 44-year-old woman was seen in January, 1955, with a history of illness beginning in May, 1954, when she developed a sudden episode of paraplegia from which she recovered within a few hours. In October, 1954, she developed mental symptoms for which she received electric coma therapy. The mental changes consisted of impairment of memory, inattention and hallucinations. She had headaches, right eye soreness, bilateral numbness of the lower half of the face; apraxia and astereognosis. She complained of a constant odor and blurring of vision. An anomic aphasia and alexia existed. Urgency, frequency and urinary incontinence were present.

The patient was obese with a blood pressure of 170/105. The external ocular movements were normal and without nystagmus. The right pupil was larger than the left. Light and accommodation reactions were normal. Confrontation testing revealed a right homonymous hemianopsia. The retinal veins were prominent but no papilledema was present. There was no sensory or motor weakness of the face. Gait was slow but otherwise normal and no paresis was present. There was hypalgesia in the right arm and leg. Deep pressure and touch sensations were preserved. The biceps, triceps and radial reflexes were hyperactive on the left, while the patellar and Achilles reflexes were increased on the right, and a right ankle clonus was present. The abdominal reflexes were intact. The Babinski, Gordon and Oppenheim signs were absent but the Hoffman was markedly positive bilaterally. Aphasia both receptive and expressive; agraphia, astereognosis, and apraxia of the right hand were demonstrated. In performing the finger-to-nose test there was pronounced tremor in the left hand and to a lesser extent in the right. The patient was unable to perform the heel-to-knee test adequately with either leg. The Holmes rebound phenomenon was present bilaterally. The buccal or snout reflex was not positive.

Routine laboratory studies and roentgenograms of the skull and chest were normal. On February 2, 1955, the patient was taken to surgery and bilateral carotid arteriography was performed under Pentothal anesthesia. Thrombosis of the internal carotid arteries was demonstrated immediately above the bifurcation of both common carotids. Filling



**Fig. 1.** (Case 1). Left carotid arteriogram showing absence of filling of the internal carotid artery and only a slight amount of contrast medium in its siphon. Collateral circulation by way of the left ophthalmic artery could not be clearly demonstrated.

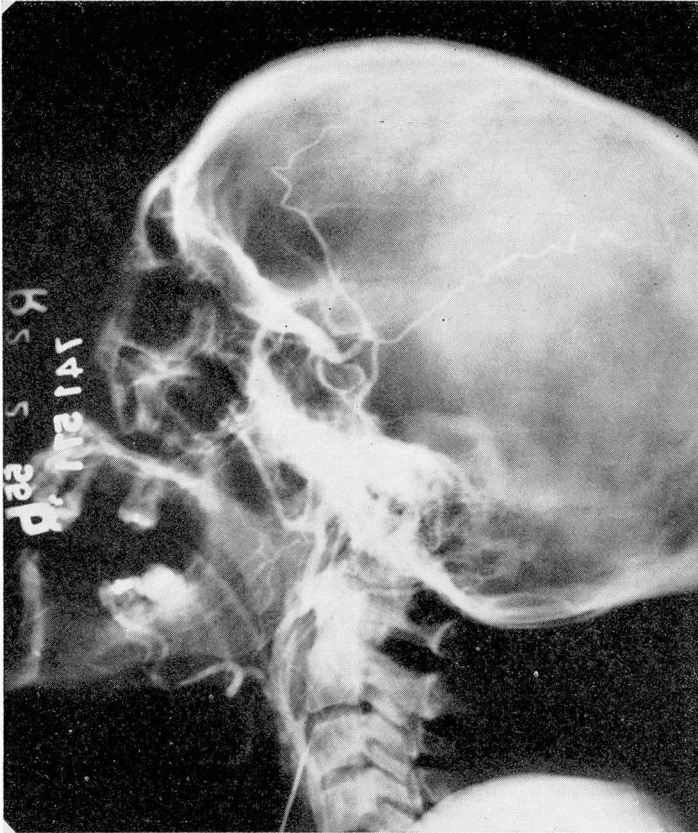


Fig. 2. (Case 1). Right carotid arteriogram showing occlusion of the right internal carotid artery but a well-defined siphon. The ophthalmic artery can be recognized as a fine line in the retrobulbar region.

of both internal carotid arteries was demonstrated in the siphons particularly on the right side and both ophthalmic and external carotid arteries contained contrast medium (Figs. 1 and 2). Bilateral cervical sympathectomy was performed, at which time both internal carotid arteries were found to be firm, nonpulsating, hard, gray-white cords.

Postoperatively the patient responded readily but it was noted that she had developed pronounced weakness of the right arm and leg which had not been present on admission. The deep tendon reflexes were unchanged but a Babinski sign was now present on the right. The patient was discharged from the hospital on February 8; four months later she was seen as an outpatient and there was no progression of her symptoms nor change in the neurologic picture.

**Case 2.** A 55-year-old man was first seen on April 11, 1955, complaining of unsteady gait, weakness in the right leg and "spells" for two years. In November, 1953, he developed a severe occipital headache and retired to bed. His wife noted thick speech and weakness of the right arm and leg. He was given phenobarbital and slept until the follow-

ing day when he had entirely recovered. Since then he had noticed transient spells of weakness of the right arm and leg and transient paresthesias involving part or all of the right face, arm or leg; these episodes lasting from 5 to 35 minutes. Five episodes of right facial weakness had occurred, the most recent being in February, 1955. More recently the patient noted deviation of gait to the right. On several occasions he complained of loss of vision as though "a sheet had been passed in front of the eyes." These visual disturbances lasted up to 10 minutes. There had been some difficulty in counting change and expressive aphasia was manifested by difficulty in selecting the proper word. His writing was intermittently illegible. Two weeks before admission the patient suddenly developed respiratory stridor, cyanosis and epistaxis from the right nostril. There was an involuntary inversion of the right foot. The entire episode endured no more than 10 minutes.

The general physical examination was not remarkable. The blood pressure was 160/78. The neurological studies revealed no cranial nerve defect. Pupillary reactions were normal and visual fields were intact to gross testing. There was no papilledema.

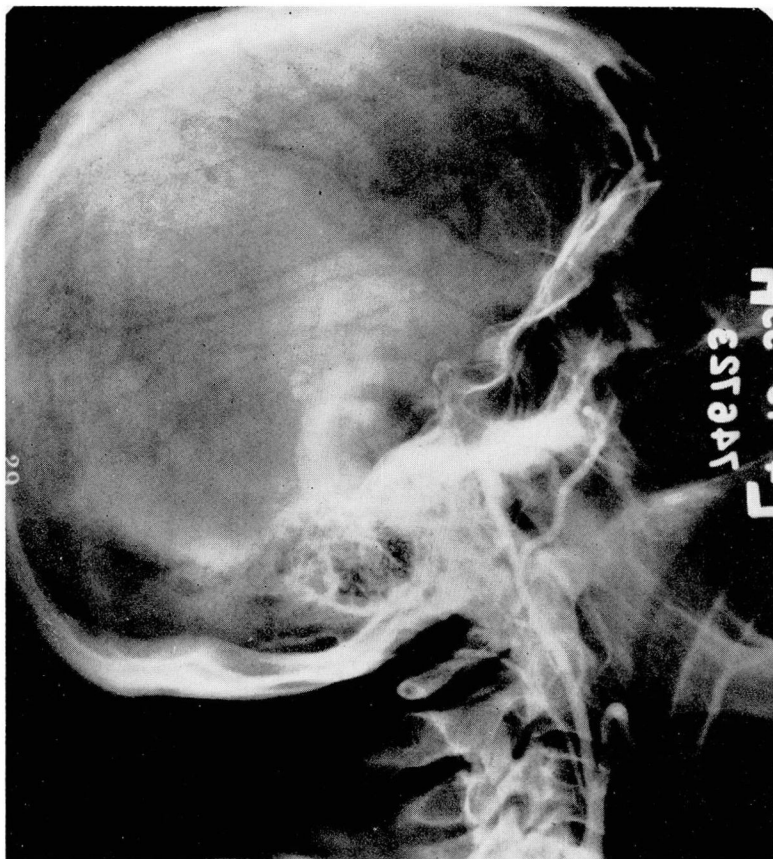


Fig. 3. (Case 2). Left carotid arteriogram demonstrating no patency of the internal carotid artery and little or no evidence of a collateral circulation.

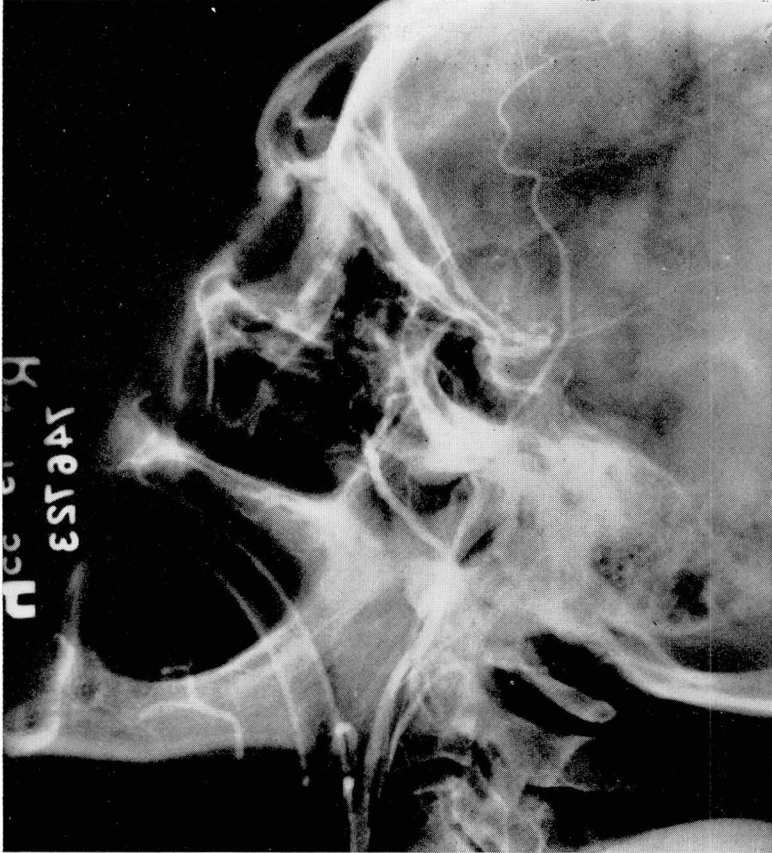


Fig. 4. (Case 2). Right carotid arteriogram showing a well-filled carotid siphon and a collateral blood supply by way of the external maxillary artery and retrobulbar anastomoses. The anterior and middle cerebral arteries can be discerned behind the middle meningeal branches.

No paresis of any muscle group was demonstrated and the gait appeared to be normal. No deficit in touch, pin prick or vibratory sense could be elicited. Position sense was normal, tendon reflexes were symmetrically active and the abdominal reflexes were equal. An equivocal Babinski sign was present on the right. There was no unsteadiness in the Romberg position. Finger-to-nose and heel-to-knee tests were well performed. There were no tremors and the Holmes rebound test was normal.

Routine blood studies and serology were normal. Urinalysis showed a 4 plus sugar. A glucose tolerance test was abnormal but blood sugar levels were controlled by diet. The spinal fluid pressure was 260 (mm., H<sub>2</sub>O); there was one cell per cu. mm., no globulin and 3 mg. of protein. Roentgenograms of the skull and the chest were normal. There were hypertrophic changes in the cervical spine.

Bilateral carotid arteriograms showed thrombosis of both internal carotid arteries with good filling of the external carotids, and of the anastomoses with the ophthalmic

artery and siphon on the right side (Figs. 3 and 4). During bilateral cervical sympathectomy the internal carotids were identified as dense hard cords.

Immediately after surgery it was apparent that the patient had developed a right hemiplegia and aphasia. During the next week he recovered, retaining only a slight nominal aphasia and paresis of the leg. There was, however, considerable apraxia and weakness of the right hand. The Babinski and Hoffman signs were present on the right.

The patient was discharged from the hospital but about one week later he again developed a right hemiplegia which in a 24-hour period had shown some improvement.

**Case 3.** A salesman was first seen at the Cleveland Clinic in 1952, at the age of 55 years, complaining of numbness and pins-and-needles sensations in the hands and feet. In addition, he gave a five-year history of intermittent, dull, aching precordial pain brought on by exertion. On physical examination at that time, he was found to have a mild hypertension of 150/90, mild arteriosclerotic heart disease, and some generalized arteriosclerosis. Six months later, in August of the same year, the patient had one episode of momentary unconsciousness precipitated by coughing and at that time it was believed to be a laryngeal syncope. He was told that he should reduce his activity, use nitroglycerin for the precordial pain, and stop smoking.

He was not seen again until January, 1954, when his complaints were heaviness and numbness in the hands and feet. The patient stated that the complaints had been present intermittently for two years. At the time of admission he stated that 24 hours preceding the onset of weakness in the right leg, he had had numbness and a heavy feeling in the left hand. His face became numb bilaterally and his vision blurred. The patient feared that he had had a stroke. He also stated that during the morning of the day of admission, he had been unable to talk for a few moments and that during recent weeks he had been having memory lapses. His blood pressure was 184/100. Neurological examination revealed an alert, mentally clear patient with intact cranial nerves, a slight weakness of the left hand and arm and an apraxia of the same extremity. There was no sensory deficit. Deep tendon reflexes were slightly hyperactive in the left lower limb. There was no Hoffman or Babinski sign and cerebellar signs were absent. The diagnostic impression was that of multiple, bilateral small cerebral thromboses. The emotional state of the patient was one of facetiousness and exaggerated good feeling suggestive of the "witzelsucht" of forebrain disease. The patient was discharged from the hospital on January 20, 1954, and followed as an outpatient.

On April 15, 1955, the patient was again admitted to the hospital with the complaint of several episodes of weakness in the extremities during the preceding three days. These began with a paresis of the right arm and leg in the early morning hours, which persisted for approximately ten minutes, and prevented his getting to the bathroom. Several more spells, each lasting five to ten minutes, had occurred and were associated with dizziness and with weakness in both legs and arms. He never lost consciousness during any of the episodes. Finally, a spell of generalized weakness and vertigo lasting approximately one-half hour frightened him and prompted his seeking admission to the hospital.

Examination revealed no involvement of the cranial nerves, no weakness and no loss of sensation to touch or pin prick. Deep tendon reflexes were normally active and equal throughout. There was no Babinski sign but a Hoffman was present on the right. The abdominal reflexes were absent. During attacks, the patient claimed inability to move the right arm or leg. The paucity of objective findings, when the patient's complaints were quite pronounced, suggested a hysterical reaction. Later, when the patient became extremely abusive and started to throw articles from his bedside table, the impression was even more firmly established that most of his symptoms were functional. However

two days following these episodes, the patient developed a very obvious spastic paralysis of the left upper and lower extremity. The Babinski and Hoffman signs were present and a positive oral or snout reflex was elicited. The deep tendon reflexes were hyperactive on the left. A slight amimia was present on the right side. Cervical sympathetic blocks produced no change. An electroencephalogram revealed focal dysrhythmias in the right central and parietal area and some abnormalities in the left parietal area.

During the next several days, the patient had frequent episodes of weakness on the right side, associated with feelings of numbness and awkwardness in an arm or leg, or in both. He received several stellate blocks, which did not produce any changes in the symptoms.

On April 29, the patient became quite uncommunicative and was found to have a spastic quadriplegia. The Babinski sign was present bilaterally. He had a nominal aphasia but moved his eyes and protruded his tongue on command. On May 2, bilateral carotid arteriograms revealed thrombosis of both internal carotid arteries. A bilateral cervical sympathectomy was performed. Both internal carotid arteries were nonpulsating and firm, the right less so than the left. The patient did not respond following surgery and remained in decerebrate rigidity until he died on May 25, 1955.

The laboratory studies throughout the patient's visits to the hospital always had been within normal limits. The serology was negative on three occasions. The patient never showed evidence of diabetes or renal disease. Roentgenograms of the chest and skull were normal. Roentgenograms of the lumbar spine revealed some hypertrophic changes. Also noted were calcifications in the abdominal aorta and iliac vessels. Electrocardiograms, taken on several occasions, revealed evidence of old posterior myocardial infarction with no change during the period 1952 to 1955. Postmortem examination revealed complete thrombosis of long standing of the left internal carotid artery in the cervical portion as well as in the siphon. The right internal carotid artery was occluded by an atherosclerotic plaque just above the common carotid bifurcation. There was, however, a small lumen still present at this site which was estimated as being about 10 per cent of normal patency. The middle cerebral artery on the same side was not involved but the right anterior cerebral artery contained several firm red clots.

Both frontal lobes were symmetrically softened on palpation, and section revealed a large area of necrosis in the distribution of both anterior cerebral arteries. There were symmetrical areas of necrosis in the basal ganglia encroaching upon the genu of each internal capsule. Some of the involved areas presented fresh cyst formations and others a translucency indicating lesions of longer standing. Sections through the brain stem demonstrated no gross abnormality. The vertebral, basilar and posterior communicating arteries were widely patent with little or no evidence of atherosclerosis.

### Comment

The cases reported here are obviously inadequate to define fully a syndrome of bilateral internal carotid artery thrombosis if such a syndrome actually exists. However significant findings are demonstrated and an attempt will be made to correlate them.

As stated by Fisher<sup>1</sup> and Frøvig,<sup>6</sup> dementia is a prominent feature. One of our patients (Case 2) did not demonstrate such aberration to his wife or to the examiners because it was either in an inchoate state or was not present at all. This facet of the symptomatology requires a larger series for evaluation. How-



ever it appears from our studies and those of Frøvig that no specific pattern of a psychosis results from the altered blood supply and that the psychotic changes, whatever may be their nature, do not differ from those resulting from unilateral occlusion of the internal carotid artery.

Transient hemiplegia, first appearing on one side and then on the other, or a paraplegia probably is the most telltale of all symptoms in bilateral occlusion. Interestingly enough, hemiplegia first developed in all three of our cases on the right side, lending support to the statement that thrombosis is more common in the left carotid artery. This figure does not consider the incidence of right-handed people in the population or the relative paucity of symptoms in right cerebral lesions. Transient paraplegia of the lower limbs which existed in our first case is consistent with the reduction of blood flow through both anterior cerebral arteries. Frøvig's patient also complained of severe weakness of the lower extremities.

Bilateral visual disturbances of a transient nature occurred in all three patients. These could hardly be attributed to disturbances of the visual cortex which is supplied chiefly by the posterior cerebral circulation; it is possible that these rather ephemeral visual symptoms may be due to the readjustments in the blood supply of the eyeball made necessary by the retrograde blood flow in the ophthalmic arteries.

Transient sensory phenomena such as paresthesias of the face and extremities were present bilaterally in two of our patients and are also to be considered as being suggestive of bilateral occlusion if such sensory disturbances are found on both sides of the body.

Alvarez<sup>7</sup> recently brought to attention the significance of repeated minor episodes of focal cerebral defect producing transitory symptoms and which are regarded as being "little strokes" or vascular spasms prodromal to a permanent cerebral lesion. It is probable that because of the similarity of symptoms in this syndrome to those of thrombosis of the internal carotid artery, either unilateral or bilateral, many cases of the latter condition remained without a correct diagnosis in the pre-arteriographic era.

At present the diagnosis depends on surgery and arteriography, or on post-mortem examination. Experience with palpation of the thrombosed arteries in the neck or pharyngeal wall has been highly unsatisfactory. Actually, manipulation of these vessels during arteriography or cervical sympathectomy may precipitate the development of more neurological defects, as it did in two of our patients.

The frequency of bilateral thrombosis of the internal carotid artery is unknown. We are certain that its presence in the ambulatory patient would hardly have been suspected a few years ago. There is no precise manner of establishing the time of the onset of the occlusions, whether these be unilateral or bilateral, because the symptoms are so variable and fluctuate in most unpredictable fashion.

The one outstanding and highly suggestive clinical evidence for thrombosis of both internal carotid arteries is the presence of evanescent and bilateral signs of defect in motor, sensory and language functions of the cerebral cortex. The frequently overlooked or misinterpreted mental changes are of great importance and should be the subject of a special study in themselves.

The authors recognize that pathologic material was not available to allow a comprehensive study of all the marked changes that take place in cerebral tissues when both internal carotid arteries are occluded by vascular disease. Because of the extreme variability of the caliber and arrangement of the cerebral vessels that provide collateral circulation in and about the circle of Willis in the human being, it is probable that both clinical signs and pathologic changes can never be so stereotyped as to provide a clear syndrome in this disease. The demonstration of occlusion by angiography and the presence of cordlike internal carotid arteries on surgical exposure are sufficient verification of the diagnosis. The more and more frequent application of angiography of the cerebral circulation will probably demonstrate that this vascular disorder is not an infrequent cause of mental and neurological disease.

#### References

1. Fisher, Miller: Occlusion of the carotid arteries; further experiences. *A.M.A. Arch. Neurol. & Psychiat.* **72**: 187-204 (Aug.) 1954.
2. Johnson, H. C. and Walker, A. E.: Angiographic diagnosis of spontaneous thrombosis of internal and common carotid arteries. *J. Neurosurg.* **8**: 631-659 (Nov.) 1951.
3. Moniz, E.: Trombosis y otras obstrucciones de las carotidas. *Manuales de medicina practica.* Barcelona-Buenos Aires: Salvat, 1941, pp. 173.
4. Torkildsen, A. and Koppang, K.: Notes on collateral cerebral circulation as demonstrated by carotid angiography. *J. Neurosurg.* **8**: 269-278 (May) 1951.
5. Walsh, F. B. and Smith, G. W.: Ocular complications of carotid angiography; ocular signs of thrombosis of internal carotid artery. *J. Neurosurg.* **9**: 517-537 (Sept.) 1952.
6. Frøvig, A. G.: Bilateral obliteration of the common carotid artery; thromboangiitis obliterans? Contributions to clinical study of obliteration of carotids and to elucidation of cerebral vascular circulation. *Acta psychiat. et neurol., suppl.* **39**: pp. 3-79, 1946.
7. Alvarez, W. C.: The little strokes. *J.A.M.A.* **157**: 1199-1204 (April 2) 1955.