

UNILATERAL EXOPHTHALMOS AS THE PRESENTING SIGN IN LEUKEMIA

Report of Two Cases

ROSCOE J. KENNEDY, M.D., and MARVIN F. GREEN, M.D.
Department of Ophthalmology

UNILATERAL EXOPHTHALMOS rarely occurs as the initial sign of leukemia, although exophthalmos occasionally develops during the course of leukemia—Reese¹ reports the occurrence in 2 per cent of patients having lymphocytic leukemia. Since it is usually the ophthalmologist who is called upon to determine the cause of exophthalmos, the fact that it may be the presenting sign in unsuspected leukemia is of particular importance to him. The present report describes two unusual cases in which unilateral exophthalmos was the first sign of leukemia. These occurred in two seven-year-old children, a boy and a girl. The exophthalmos was persistent in the boy and intermittent in the girl.

Report of Cases

Case 1. A seven-year-old boy was first examined in the Department of Ophthalmology on November 6, 1952. His parents stated that he had had some protrusion of the right eye for about two weeks, but that his general health had been excellent (Fig. 1 a).

Table 1 gives the results of the ocular examination. No mass was palpable, and bruit was questionable. Examinations of the extraocular muscles and the ocular fundi revealed no abnormalities.

The patient was examined in the Department of Neurological Surgery by Dr. W. James Gardner, and no evidence of intracranial pathology could be found. The examination by Dr. Harold E. Harris of the Department of Otolaryngology disclosed no evidence of mucocele or of other pathologic condition in the sinuses.

Laboratory studies revealed a red blood cell count of 3,700,000 and a white blood cell count of 6,150 per cu. mm.; a negative serology; a hemoglobin content of 9.6 gm. and a blood sugar level of 67 mg. per hundred milliliters. The findings on roentgen study of the chest, sinuses, skull, and optic foramina were normal.

On November 17, 1952, the patient was admitted to the hospital for possible exploration of the orbit. Although the ocular measurements were unchanged at that time, the right eye appeared to be somewhat more prominent than when first examined (Fig. 1 b). At the recommendation of Dr. Robert D. Mercer of the Department of Pediatrics, a bone marrow examination was made preoperatively. The results were suggestive of neuroblastoma or possibly, leukemia; and orbital exploration was not performed. A special blood cell count revealed 56 per cent lymphoblasts, and a diagnosis of acute leukemia was made.

A course of roentgen therapy to the orbits was completed on November 26, 1952 (Fig. 1 c). By December 9, 1952, the anteroposterior measurement of the right eye was 17 mm., a reduction of 4 mm.

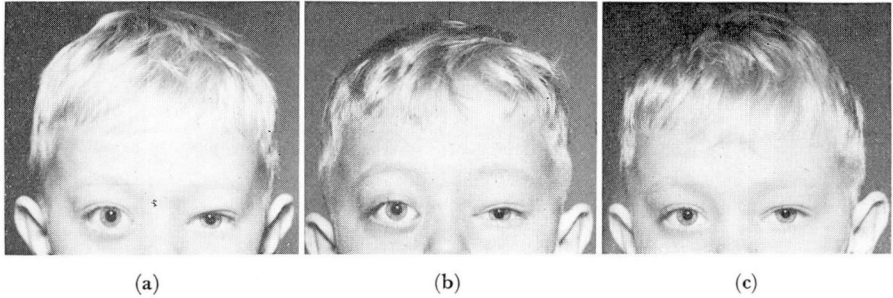


Fig. 1. (Case 1) Photographs of patient taken (a) on November 11, 1952, (b) on November 19, 1952, and (c) on November 26, 1952.

Table 1.—Results of initial ocular examination (Case 1)

	Right eye	Left eye
Visual acuity	6/6	6/6
Fissures	13 mm.	8 mm.
Anteroposterior (Hertel exophthalmometer) measurements	21 mm.	15 mm.

During the next few months the patient was hospitalized a number of times to receive blood transfusions, 4-amino-pteroylglutamic acid, and nitrogen mustard; however, his course was progressively downhill and he died on May 24, 1953, seven months after the initial examination.

Diagnoses from the postmortem examination were: (1) Subacute granulocytic leukemia, evidenced in bone marrow, spleen, liver, lymph nodes. (2) Bronchopneumonia, focal diffuse, leukemic type. (3) Petechial hemorrhages in the heart, pericardium, and stomach. (4) Lipoid depletion in adrenal. (5) Ulcerations of skin of left arm and leg.

Case 2. A seven-year-old girl was first examined here on April 2, 1954. Her parents stated that she had had intermittent slight protrusion of the left eye for about one month: the eye would protrude for a period of eight or nine hours after which it would again be normal. They believed that there was no appreciable protrusion on the day of examination. Her general health had been excellent.

Table 2 gives the results of ocular examination which demonstrated slight exophthalmos of the left eye. No mass was palpable, and no bruit was heard. The ocular fundi were normal.

Table 2.—Results of initial ocular examination (Case 2)

	Right eye	Left eye
Visual acuity	6/15	6/15
corrected to	6/9 with	6/9 with
	+ .25 sph \ominus + 2.25 cyl, ax 95	+ 2.25 cyl, ax 85
Fissures	8 mm.	7 mm.
Anteroposterior (Hertel exophthalmometer) measurements	17 mm.	19 mm.

Examination by Doctor Mercer in the Department of Pediatrics revealed no further abnormalities. Special blood studies revealed a red blood cell count of 4,330,000 per cu. mm.; a hemoglobin content of 11.6 gm. per hundred milliliters; and a white blood cell count of 9,950 per cu. mm., in which were identified 5 per cent blast cells, 6 per cent atypical cells, 3 per cent early cells. A study of the bone marrow revealed a slight increase in blast cells, but an exact diagnosis was not possible. The serology was negative, and the blood sugar level was 91 mg. per hundred milliliters. Findings on urography and on roentgenography of the skull and long bones were normal.

One month later the child's condition was essentially the same, except that the exophthalmos of the left eye was more noticeable with a 3 to 4 mm. difference between the two eyes, and the white blood cell count was 4,600 per cu. mm., consisting of 6 per cent blast and early cells.

Within the next two months (Fig. 2 a) there was no change in the test results, except that roentgenograms revealed haziness of the left ethmoid and maxillary sinuses and a mass that was palpable under the left supraorbital ridge. Biopsy of the mass revealed leukemic infiltration. A course of nitrogen mustard therapy was started; the exophthalmos receded for three months.

On November 4, 1954, 25 per cent blast cells were found in the peripheral blood, and a diagnosis of granulocytic leukemia, subacute type, was made from examination of the bone marrow. Roentgen therapy was then given to the left orbit and the exophthalmos again diminished (Fig. 2 b).

Within three months the white blood cell count had increased to 46,000 per cu. mm., with 72 per cent blast cells. The hemoglobin content was 3.5 gm. per hundred milliliters (Fig. 2 c). The course was progressively downhill and she was hospitalized several times to receive roentgen therapy to the left knee, left ankle, dorsal spine, and ears because of pain. Twice she developed subconjunctival hemorrhages in the right eye. She died on March 1, 1955, 11 months after the initial examination. The final diagnosis was granulocytic leukemia. No autopsy was performed.

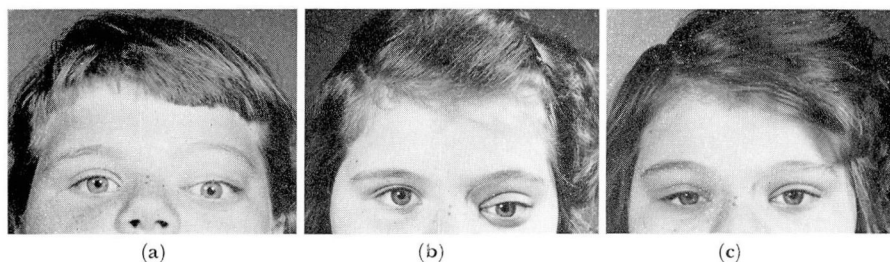


Fig. 2. (Case 2) Photographs of patient taken (a) on June 30, 1954, (b) on November 12, 1954, and (c) on February 1, 1955.

Survey of the Literature

The coexistence of exophthalmos and leukemia is reported every year, both in this country and abroad. Forkner² in 1938 presented a comprehensive historical account of the published literature. Reese and Guy³ in 1933 reported a 69-year-old man who had lymphocytic leukemia in whom unilateral exophthalmos was the presenting complaint. They also reported a 19-year-old man having granulocytic leukemia whose presenting complaint was a five-day history of visual loss in one eye; six days after initial examination the patient developed exophthalmos in the other eye. They stated that exophthalmos as a complication of granulocytic leukemia is exceedingly rare. Cohen⁴ in 1934 reported the case of a patient with lymphocytic leukemia who had a leukemic growth between the globe and the orbit.

O'Brien and Leinfelder⁵ in 1935 reviewed 82 consecutive cases of unilateral exophthalmos. Blood dyscrasias were present in 7 of 51 patients whose exophthalmos was noninflammatory. Apparently two of those with blood dyscrasia had the exophthalmos as the initial sign of the disease.

Kandel⁶ reported three cases of chloroma along with a review of 175 cases in the literature. Chloroma may produce exophthalmos, since it is a variant of granulocytic leukemia characterized by a deposition of greenish-yellow tumor-like masses in the skeleton, especially in the skull and orbital regions, in the lymph nodes, and in the viscera.

Randolph⁷ in 1938 analyzed reports of 71 consecutive patients having unilateral exophthalmos, none of whom had leukemia.

McGavic^{8,9} reported 21 patients with lymphomatous diseases involving the orbit. One of two with leukemia had lesions in the eyelids three years before other parts of the body became involved.

Discussion

Unilateral exophthalmos always presents a difficult diagnostic problem because it is a manifestation common to all space-taking lesions of the orbit.¹⁰

The difficulty is compounded by the more than 75 possible etiologic factors that come into consideration.^{11,12} Seldom if ever can a diagnosis be established after a brief examination, and more often than not the ophthalmologist must call upon the aid of colleagues from other specialties, such as endocrinology, hematology, neurosurgery, otolaryngology, pediatrics, and radiology, if certain etiologic possibilities are to be ruled in or out and the true diagnosis is to be obtained. One of the common causes of unilateral exophthalmos is Graves' disease. This, even without hyperthyroidism, may be differentiated from other causes by the use of the triiodothyronine suppression test described by Werner.¹³ The failure of this drug to suppress the radioiodine uptake confirms the diagnosis of Graves' disease; however, the disease cannot be excluded if there is a significant decrease in the radioiodine uptake such as that which occurred in two of our patients with Graves' disease.

Our two cases reported here demonstrate the importance of hematological consultation in evaluating unilateral exophthalmos and the wisdom of performing complete and repeated blood studies, including examination of the bone marrow. In particular, an accurate differential white blood count may obviate the need for other tests and for what would be useless surgery.

Summary and Conclusions

Unilateral exophthalmos rarely is the presenting sign in leukemia, although exophthalmos occasionally develops during the course of the disease. Reports are presented of two children having leukemia in whom unilateral exophthalmos was the initial sign. In one child the exophthalmos was intermittent, and in the other it was constant. Patients whose presenting sign is exophthalmos should have complete blood studies including examinations of bone marrow, because the findings on these studies may prevent unnecessary orbital exploration.

References

1. Reese, A. B.: Tumors of the Eye. New York, Paul B. Hoeber, Inc., 1951, pp. 574.
2. Forkner, C. E.: Leukemia and Allied Disorders. New York, The Macmillan Company, 1938, pp. 333.
3. Reese, A. B., and Guy, L.: Exophthalmos in leukemia. *Am. J. Ophth.* **16**: 718-720, Aug. 1933.
4. Cohen, M.: Orbital lymphoma in chronic lymphatic leukemia; report of case. *Arch. Ophth.* **11**: 617-624, April 1934.
5. O'Brien, C. S., and Leinfelder, P. J.: Unilateral exophthalmos; etiologic and diagnostic studies in 82 consecutive cases. *Am. J. Ophth.* **18**: 123-132, Feb. 1935.
6. Kandel, E. V.: Chloroma; review of literature from 1926 to 1936 and report of three cases. *Arch. Int. Med.* **59**: 691-704, April 1937.
7. Randolph, M. E.: Analysis of 71 consecutive cases of unilateral exophthalmos. *Am. J. Ophth.* **21**: 169-176, Feb. 1938.
8. McGavic, J. S.: Lymphomatoid diseases involving eye and its adnexa. *Arch. Ophth.* **30**: 179-193, Aug. 1943.
9. McGavic, J. S.: (In Society Transactions) Lymphomatous tumors of eye. *A.M.A. Arch. Ophth.* **52**: 642-645, Oct. 1954.

10. Benedict, W. L.: Surgical treatment of tumors and cysts of orbit; eleventh de Schweinitz lecture. *Am. J. Ophth.* **32**: 763-773, June, pt. 1, 1949.
11. Duke-Elder, S.: *Text-Book of Ophthalmology*. Vol. 5: The Ocular Adnexa. St. Louis, C. V. Mosby Company, 1952, pp. 4631-5713.
12. Spaeth, E. B.: Pathogenesis of unilateral exophthalmos. *Arch. Ophth.* **18**: 107-148, July 1937.
13. Werner, S. C.: Euthyroid patients with early eye signs of Graves' disease. *Am. J. Med.* **18**: 608-612, April 1955.