

# ELECTIVE CARDIAC ARREST BY THE MELROSE TECHNIC

## *Potassium Asystole for Experimental Cardiac Surgery*

WILLEM J. KOLFF, M.D.,  
Division of Research

DONALD B. EFFLER, M.D., LAURENCE K. GROVES, M.D.,  
GERRIT PEEREBOOM, M.D.,\*  
Department of Thoracic Surgery

SHIGETO AOYAMA, M.D.,\*  
Division of Research

and

F. MASON SONES, JR., M.D.  
Department of Cardiovascular Disease

**I**NTRACARDIAC operations would be more easily performed if the heart could be arrested and restarted at will, and if the coronary blood flow could be stopped without damage to the myocardium during the period of arrest. Visualization would be excellent in the quiescent and dry heart, suturing would be much simpler, and air embolism could not occur. This objective has now been achieved in England through the efforts of Melrose, Dryer, Bentall, and Baker.<sup>1</sup> The basic physiological observation was made by Ringer<sup>2</sup> in 1883. Hooker<sup>3</sup> in 1929 suggested that potassium chloride could be used to stop the heart when it is in a state of ventricular fibrillation, and he recommended using calcium chloride to restart the heart beat. Montgomery, Prevedel, and Swan<sup>4</sup> used a similar technic to reverse fibrillation in hypothermic patients. In our experiments with dogs, we followed closely the technic of Melrose and associates in which diastolic asystole is induced with potassium citrate, and we have been able to confirm their results.

### Technic

First, the dog is connected to the heart-lung machine, as described in the preceding article. While the machine is pumping oxygenated blood at a flow rate of 35 ml. per kg. of body weight per minute, the caval and the azygos veins

\* Fellow.

*This work was supported by a grant to Doctor Kolff from the Cleveland Area Heart Society.*

are closed off. Then the aorta is cross-clamped with a ductus clamp 2 or 3 cm. above the heart. In dogs weighing up to 15 kg., 2 ml. of a 25 per cent solution of potassium citrate ( $=\frac{1}{2}$  gm.  $=4.5$  mEq.) is diluted to 20 ml. by aspiration of blood into a syringe. A 22-gauge cannula is inserted into the trunk of the aorta proximal to the ductus clamp and the mixture is injected rather quickly until the heart stops beating, usually within 30 seconds. Eight or twelve cubic centimeters of the mixture often is enough (in adult human patients Melrose recommends 1 gm. of potassium citrate in 50 ml. of blood). The potassium ion stops the heart in diastole and the citrate probably potentiates the effect by reducing the proportion of ionized calcium in the blood.

During cardiac arrest the heart has a low oxygen requirement, consequently occlusion of the aorta and cessation of the coronary flow have no ill effect on it, and the dry heart may be cut, repaired, and sutured. After completion of the intracardiac operation the clamp on the aorta is released. A stream of blood immediately gushes from the sinus venosus and the thebesian veins; it is at first dark in color but soon becomes bright red, and quickly fills the right side of the heart. The first heart beat sometimes comes within 15 seconds. Melrose warns against the use of calcium in attempts to restore normal rhythm, because it tends to stimulate contraction before adequate oxygenation has been attained and may precipitate ventricular fibrillation. Flushing out of the coronary vessels with oxygenated blood from the artificial heart at once washes out excess potassium and at the same time provides oxygenation.

The right ventricle is closed only after an adequate heart beat has been restored. In the meantime the unusually large amount of coronary blood flows out freely; this avoids undue stretching of the muscle fibers, and disposes of potassium-loaded blood. If the heart were prematurely closed the potassium might re-enter the coronary arteries via the lesser circulation on the left side of the heart.

Our technic (above) requires that this and all lost blood be promptly replaced. After three minutes the heart beat usually is strong and regular and the heart may be closed. The venae cavae are released, first the superior, then the inferior. The puncture hole in the aorta sometimes causes troublesome bleeding in heparinized animals.

## Results

In 10 dogs the heart was arrested by potassium citrate for periods of  $\frac{1}{2}$  to 23 minutes. Normal rhythm was restored in all. In one dog the heart had to be massaged after release of the venae cavae to avoid overdistention. Ventricular fibrillation occurred in one dog (experiment no. 135) so that the procedure of potassium asystole was repeated; the heart then resumed a normal rhythm and the dog recovered.

The average interval between releasing of the clamp on the aorta and resumption of cardiac action was 37 seconds. Of the 10 dogs, five recovered

completely. One dog died the night after operation; no anatomical cause for its death could be found, but it was concluded that the animal probably had not been adequately transfused. Four dogs died later from causes not related to the potassium asystole—atelectasis, empyema, pleural effusion. The last three dogs of the series were pups. It is well known that lungs of pups are difficult to handle and are prone to damage and infection. The three seemed to be in perfect health the day after operation.

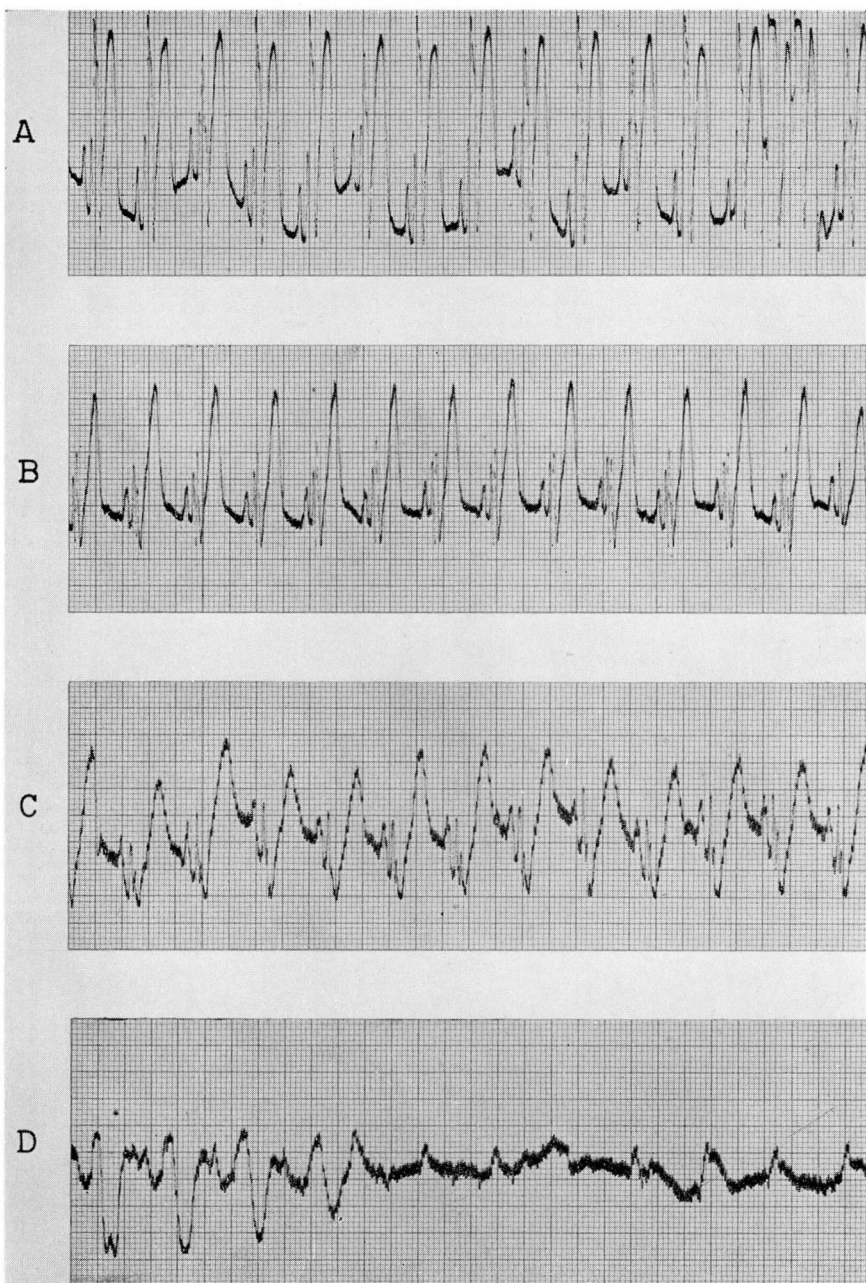
**Changes in serum potassium.** By the above technic, most of the potassium injected into the root of the aorta is flushed out of the coronary circulation and drained from the right ventricle before the heart is closed. This is shown by the pre- and post-arrest concentrations of serum potassium listed in Table 6 of the preceding article. Even if the potassium were to be retained, the rise in serum potassium would not be dangerous, since if the 4.5 mEq. injected were diluted only in extracellular fluid—rather than total body water as is probably the case—the rise in serum potassium would be less than 1 mEq. per liter. However, repetition of potassium arrest without removal of the potassium-laden blood, i.e., with the heart closed, could be dangerous.

**Electrocardiographic changes.** These are demonstrated in Figures 1 and 2. The electrocardiogram sometimes showed continued electrical activity when the heart was apparently motionless; sometimes the auricles continued to beat after the ventricles had stopped. The first beats after release of the clamp usually showed distorted patterns, and auriculoventricular, intraventricular or bundle branch block were common findings. However, these changes were transient when the conductive system was not damaged by the incision.

### Summary and Conclusions

Experimental cardiac asystole was elicited in dogs by the technic of Melrose and associates. Our data fully confirm their observations and show that elective cardiac arrest with potassium citrate greatly facilitates intracardiac operations, when used in conjunction with the artificial heart-lung apparatus with disposable membrane oxygenator described in the previous article.

The procedure was to connect the dog to the heart-lung apparatus, clamp the aorta and inject potassium citrate into the root of the aorta. The injection consisted of a mixture of 2 ml. of 25 per cent potassium citrate in 18 ml. of blood, of which 4 to 20 ml. were required to induce cardiac arrest. The average interval required for the heart to start beating after removal of the aortic clamp was 37 seconds. Ventricular fibrillation occurred in one of the 10 dogs, but repetition of the procedure (potassium arrest and flushing of the coronary circulation) established normal rhythm. In some experiments, the heart distended after release of the aortic clamp, because of residual potassium effect, anoxia or of the extensive myocardial wound. This distention disappeared within 3 to 15 minutes, especially when the animal's circulation was supported by the artificial heart-lung apparatus.



**Fig. 1.** Serial electrocardiograms (lead 2) obtained from a dog during induction of cardiac arrest with potassium citrate.

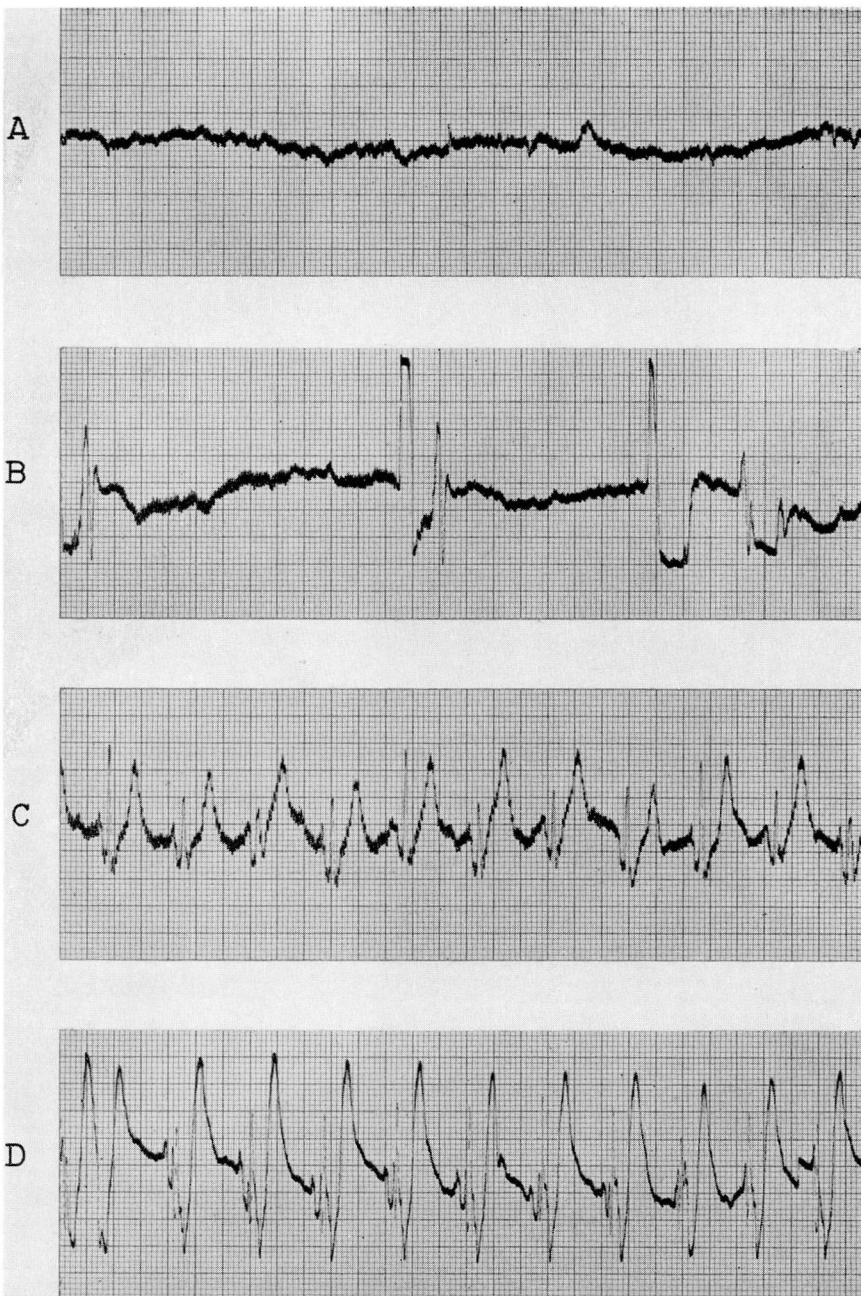**A.** Normal sinus rhythm before pump oxygenator was started.

**B.** Thirty seconds after occlusion of venae cavae. Voltage of QRS complexes is reduced. A.V. conduction is unchanged.

**C.** Thirty seconds after clamping of the ascending aorta above the coronary orifices and infusion of potassium citrate into aorta below the clamp. Prolongation of intraventricular conduction to 0.12 seconds. A.V. conduction is unchanged.

**D.** Forty-five seconds after potassium infusion. There is prolongation of P-R interval and marked widening of QRS complexes, progressing suddenly to ventricular standstill. Broad atypical P waves continue to occur for a few more seconds. A.V. conduction is blocked.





**Fig. 2.** Re-establishment of normal sinus rhythm in the dog shown in Figure 1 by removal of the aortic clamp, allowing perfusion of the coronary arteries with blood from the pump oxygenator. The time required was longer than usual because of an unusually traumatic intracardiac procedure in this instance.

**A.** Aortic clamp removed 24 minutes after cardiac arrest had been induced.

**B.** Coupled ventricular beats from two separate foci occurring three minutes after re-establishment of coronary artery perfusion. A.V. conduction has not yet been established.

**C.** Six minutes after **B**, A.V. conduction has been re-established. Intraventricular conduction has shortened. Ectopic ventricular beats have disappeared.

**D.** Twenty-seven minutes after the aortic clamp had been released the pump oxygenator was disconnected and an effective mechanical heart beat had been re-established. A.V. conduction is not prolonged. Intraventricular conduction is prolonged, due to incision of a large part of the interventricular septum and its surgical closure.

# ELECTIVE CARDIAC ARREST

**Table.** — Observations during elective cardiac arrest induced with potassium citrate in dogs

Experiment No.	Weight in kg.	Amount of K mixture in cc.	Duration of arrest, in min.	Type of operation	Serious arrhythmias	Measures taken to restore normal heart beat	Time interval between release of clamp on aorta and resumption of cardiac action	Comment
126	8.5	6	½ min.	Ventriculotomy	—	—	30 sec.	Died—3 days postop. atelectasis
127	7.7	10	10 min.	Interventricular septal defect	—	—	75 sec.	Recovered
128	6.0	20	5 min.	Interventricular septal defect	—	—	—	Recovered
130	13.2	15	13 min.	Longitudinal split of sternum; ventriculotomy	—	—	15 sec.	Died—8 days postop. empyema
132	10.7	—	22 min.	Auriculotomy and ventriculotomy	—	—	60 sec.	Recovered
133	10.3	—	23 min.	Ventriculotomy	—	Assisted by massage	35 sec.	Died—same night; inadequately transfused
135†	9.0	8	20 min.	Ventriculotomy	Ventricular fibrillation	Heart rearrested with K citrate	20 sec.	Recovered
137 (pup)	4.0	2	15 min.	Ventriculotomy	Transient block	—	42 sec.	Recovered
138 (pup)	3.1	4	15 min.	Ventriculotomy	Transient block	Isopropylarterenol 0.025 mg.	30 sec.	Died—4 days postop. pleural effusion
139 (pup)	3.7	4	15 min.	Ventriculotomy	—	—	27 sec.	Died—3 days postop. pleural effusion

† After the heart had been arrested for twenty minutes and the aortic clamp had been removed, a few beats occurred, after which ventricular fibrillation set in. The heart was allowed to fibrillate for a few minutes with the heart-lung machine going. Then the aorta was clamped again and the heart was arrested again with potassium citrate. Thirty seconds after the clamp had been removed, normal pulsations began. Eleven minutes after the heart had been rearrested the heart beat was strong and regular. The heart-lung machine was used in this case for a period of 46 minutes. The dog recovered.

**References**

1. Melrose, D. G., Dreyer, B., Bentall, H. H., and Baker, J. B. E.: Elective cardiac arrest. *Lancet* **2**: 21-22, July 2, 1955.
2. Ringer, Sydney: Further contribution regarding influence of different constituents of blood on contraction of heart. *J. Physiol.* **4**: 29-42, 1 plate, 1883.
3. Hooker, D. R.: On recovery of heart in electric shock. *Am. J. Physiol.* **91**: 305-328, Dec. 1929.
4. Montgomery, A. V., Prevedel, A. E., and Swan, H.: Prostigmine inhibition of ventricular fibrillation in hypothermic dog. *Circulation* **10**: 721-727, Nov. 1954.