

ANGIOGRAPHY OF THE CORONARY ARTERIES IN DOGS

III. During Perfusion With a Heart-Lung Machine in Combination with Cardiac Arrest in Coronary Artery Surgery

EDWARD W. MILLER, M.D.,* WILLEM J. KOLFF, M.D.,

Division of Research

and

C. ROBERT HUGHES, M.D.

Department of Radiology

TWO previous articles have reported our experience with angiography of the coronary arteries in living dogs: the first¹ described the technic in dogs with normal coronary arteries and the second² showed that surgically produced defects in the coronary arteries could be recognized. This paper describes an extension of the work. Angiography was performed on the animals on the operating table while the circulation was being maintained by a pump-oxygenator and reparative work on the coronary arteries was done. There were three specific aims: (1) to obtain satisfactory diagnostic angiograms of the coronary arteries at the time of operation (which will be mandatory before surgical repair of the coronary arteries of patients can be attempted); (2) to find a contrast medium that might safely be mixed with potassium salts used to produce elective cardiac arrest; and (3) to evaluate roentgenographically the anastomotic or reparative procedure before the chest was closed.

Material and Method

Ten mongrel dogs were used, weighing from 15 to 25 kg. The animals were given morphine sulfate as a preanesthetic and were anesthetized with either thiopental sodium (Pentothal sodium, Abbott) or pentobarbital sodium (Nembutal sodium, Abbott). Procaine hydrochloride (Novocain, Winthrop) was used locally for skin anesthesia and for intercostal block. The heart-lung machine was connected in the usual manner.³ The blood was drawn into the machine from the venae cavae through cannulae inserted through the jugular

This work was supported by a grant from the Cleveland Area Heart Society to Doctor Kolff.

The authors wish to acknowledge the technical assistance of Warner S. Williams, Chief X-Ray Technician, Department of Radiology, and of Gail Smith, student in the Course in X-Ray Technology, Department of Radiology.

**Formerly Special Fellow in the Division of Research.*

and femoral veins and returned through cannulae in both femoral arteries. A roentgen tube was mounted over the table at a target distance of 48 inches.

The animals were placed in the right posterior oblique position and a thoracotomy through the left fourth interspace was performed. Occasionally the fourth rib was removed. Tapes were placed to encircle the two venae cavae and the ascending aorta. A cardiac catheter was passed into the root of the aorta by way of the subclavian artery or one of its branches. After the artificial heart-lung had been started and the venae cavae and the ascending aorta had been occluded by tightening the tapes, 20 ml. of a solution composed of 10 ml. of 90 per cent Hypaque sodium (sodium diacetrizoate, Winthrop), 3 ml. of 25 per cent potassium citrate,⁴ and 7 ml. of 0.95 per cent saline solution, was rapidly injected through the catheter. During the last second of the injection before the heart had completely stopped, the first roentgenogram was made using an exposure of 1/10 second at 70 kilovolts (Fig. 1).

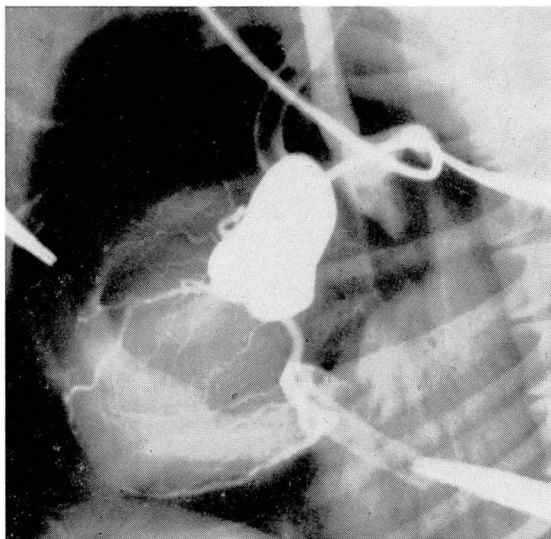


Fig. 1. Angiogram taken at the moment of cardiac arrest with the venae cavae and the aorta occluded with tapes. The cardiac catheter with its tip at the aortic base has been introduced through a branch of the left subclavian artery. All three coronary arteries are well filled.

An operation on the coronary arteries was completed during the period of arrest while the aorta and the subclavian artery remain occluded. An anastomosis between the subclavian artery and a major coronary artery was made either directly or by means of an interposed freeze-dried arterial graft. The cardiac catheter previously used for injection of the contrast Hypaque-potassium mixture was employed as a splint for the suturing. When the anastomosis had been completed the aortic tape and a bulldog clamp occluding the subclavian artery simultaneously were removed so that the coronary arteries were perfused. Usually the heart started to fibrillate. This fibrillation was allowed to continue

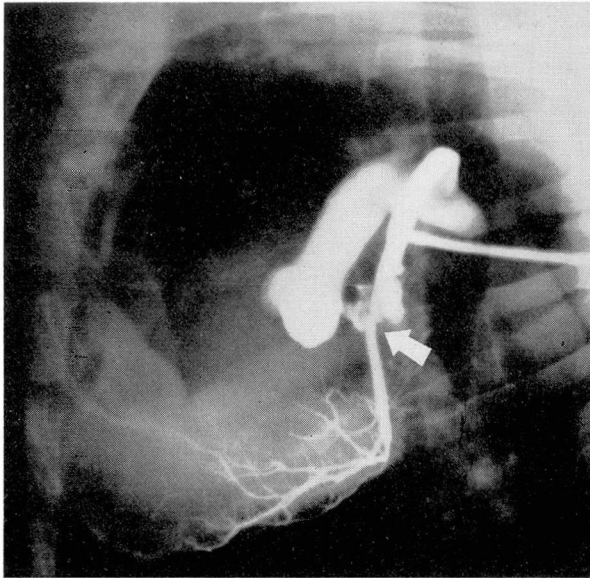


Fig. 2. Angiogram taken after completion of an end-to-end anastomosis between the left internal mammary artery and the left circumflex artery. (The left subclavian artery has been divided distally to the internal mammary and turned downward.) Backflow of the contrast medium fills the aortic arch and base. A small leak at the anastomosis is evident. This leak disappeared when the heparin was neutralized.

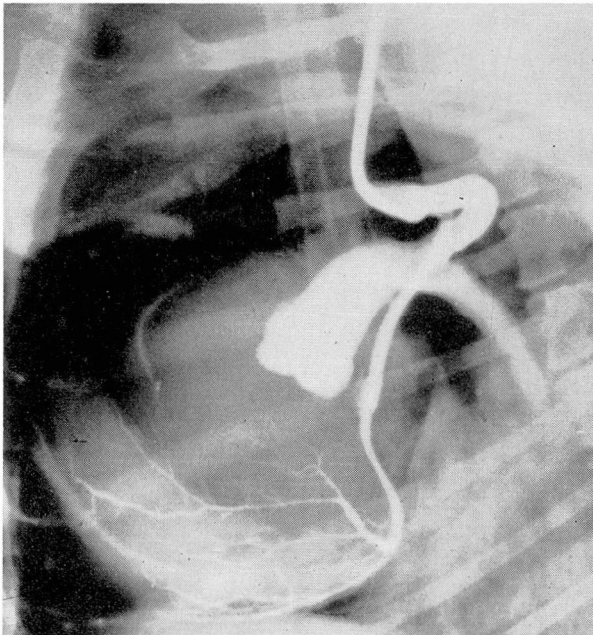


Fig. 3. Angiogram taken after completion of an end-to-end anastomosis between the left subclavian artery and the left circumflex artery, employing an interposed freeze-dried graft.

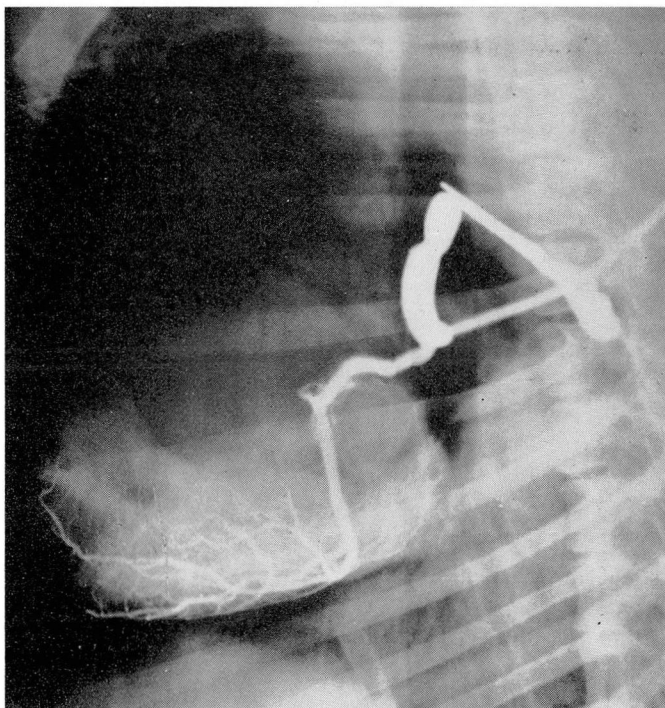

Fig. 4. Angiogram showing same type of anastomosis as that shown in Figure 3. Here the subclavian artery is occluded with a clamp so that no backflow into the aorta is seen.

for 10 minutes, during which time a second arteriogram was made to evaluate the anastomosis. Four to 8 ml. of 90 per cent Hypaque sodium was injected through the cardiac catheter into the subclavian artery and another roentgenogram was made just before the end of the injection. The root of the subclavian artery sometimes was clamped to obtain a more intense image of the anastomosed vessels, otherwise a retrograde flow also would outline the base of the aorta (Figs. 2, 3 and 4) and occasionally the untouched coronary arteries.

After the roentgenogram had been made, the heart was defibrillated using one electric shock or a series of shocks as necessary.* As soon as the dog could support its own circulation, the heart-lung machine was disconnected. If the machine could not be safely disconnected one hour after the defibrillation, the dog was sacrificed and the anastomosis was examined. The surviving dogs were carefully observed and serial electrocardiograms were made.

Results

Satisfactory diagnostic angiograms were obtained in all 10 dogs. After the

*Defibrillator giving a shock of 1 second at 110 volts was made by Frederick Olmsted, Division of Research.

completion of the anastomoses and the simultaneous release of the occlusions of the aorta and of the subclavian artery, ventricular fibrillation occurred in nine dogs; but in each, electroshock arrested the fibrillation and effective heart beats followed. In one dog a normal sinus rhythm was obtained immediately without electroshock and the second injection of contrast medium did not affect the sinus rhythm.

Whether the dogs survived or not seemed to depend on the blood flow through the anastomosis. The duration of cardiac arrest ranged from 36 minutes to 3 hours and 58 minutes; the average time was 82 minutes. In all 10 dogs an effective beat was restored despite cardiac arrest for a period greater than one hour.

Five dogs failed to maintain an adequate blood pressure and were sacrificed. In four dogs this failure resulted from narrowing at the point of anastomosis. In one dog a low rate of perfusion was the most likely cause of myocardial insufficiency. Five dogs survived* and have shown no sign of myocardial damage due to the contrast Hypaque-potassium mixture.

Summary

A technic for coronary angiography in dogs during perfusion with a heart-lung machine is described. An injection of potassium citrate with 90 per cent Hypaque sodium made it possible simultaneously to arrest the heart and to obtain a coronary angiogram. The contrast medium in combination with potassium citrate caused no apparent damage to the myocardium even when the mixture remained in the heart during periods of arrest exceeding one hour. The technic allows films of diagnostic quality to be taken on the operating table at the moment of cardiac arrest, and also after an anastomosis has been performed, in order to evaluate the immediately postoperative anatomic result.

References

1. Hughes, C. R.; Sartorius, H., and Kolff, W. J.: Angiography of coronary arteries in live dog. *Cleveland Clin. Quart.* 23: 251-255, Oct. 1956.
2. Miller, E. W.; Kolff, W. J., and Hughes, C. R.: Angiography of coronary arteries in live dog. II. Detection of abnormalities. *Cleveland Clin. Quart.* 24: 41-48, Jan. 1957.
3. Kolff, W. J.; Effler, D. B.; Groves, L. K.; Peereboom, G., and Moraca, P. P.: Disposable membrane oxygenator (heart-lung machine) and its use in experimental surgery. *Cleveland Clin. Quart.* 23: 67-97, April 1956.
4. Kolff, W. J.; Effler, D. B.; Groves, L. K.; Peereboom, G.; Aoyama, S., and Sones, F. M., Jr.: Elective cardiac arrest by Melrose technic: potassium asystole for experimental cardiac surgery. *Cleveland Clin. Quart.* 23: 98-104, April 1956.

Addendum

After completion of this study, two papers reporting successful angiography of the coronary arteries in a man came to our attention: Di Guglielmo, L., and Guttadauro, M.: Sulla visualizzazione radiologica delle arterie coronarie nel vivente; rassegna di 413 osservazioni. La Radiologia Medica, Anno XL Fasc. 10, Oct. 1954; and Di Guglielmo, L., and Guttadauro, M.: Anatomic variations in coronary arteries; arteriographic study in living subjects. Acta radiol 41: 393-416, May 1954.

*The late results of these grafts have been unsatisfactory: thrombosis occurred at the junction of the subclavian artery with the freeze-dried graft. In one recent experiment, heparinization, for one week following the operation, prevented thrombosis of the suture line.