

PHARYNGOESOPHAGEAL DIVERTICULUM

A Comparison of Results Obtained by Inversion and by Excision

HAROLD E. DUNLAP, M.D.,* GEORGE CRILE, JR., M.D.,

Department of General Surgery

and

LAURENCE K. GROVES, M.D.

Department of Thoracic Surgery

THE objective of treatment of esophageal diverticulum is to relieve the dysphagia and regurgitation with the least risk of mediastinitis, infection of the wound, recurrence of the diverticulum, or injury to laryngeal and sympathetic nerves. Since excision, inversion, or elevation of the diverticulum all relieve the major symptoms, the selection of the type of operation depends upon its safety and prevention of recurrence. We have studied records of a small series of patients treated either by excision or by inversion to determine which of these two methods is the safer and more reliable.

Pathogenesis and Symptoms

Pharyngoesophageal diverticulum is a pouchlike herniation of the pharyngeal mucosa and submucosa through a weak region in the musculature of the distal hypopharynx. This rare condition occurs predominantly in men during the fifth to the seventh decades of life. Its pathogenesis was well understood and described by Stetten¹ and by Jackson and Shallow² in the early part of this century. The predisposing factors are: (1) a structural weakness of the tissues that are located between the oblique fibers of the posterior portion of the inferior constrictor muscle and the transverse fibers of the cricopharyngeus (Fig. 1); (2) a degenerative relaxation of the elastic tissue of the hypopharyngeal wall; this relaxation is said to be aggravated by pressure against the cervical vertebrae;³ and (3) an in-co-ordination of the function of the cricopharyngeus.⁴

The cricopharyngeus is a sphincteric muscle, which Jackson and Shallow² called a "pinchcock," for it occludes the upper esophagus during respiration. During normal swallowing, as the powerful peristaltic wave progresses distally through the constrictor muscles, the cricopharyngeus relaxes in response to a reflex arc that originates in the upper posterior pharyngeal wall, and is transmitted via the pharyngeal plexus, nucleus ambiguus, spinal accessory nerve, ganglion nodosum, and vagus nerve. However, when there is in-co-ordination in the relaxation of the cricopharyngeus in response to this reflex, an increased pharyngeal intraluminal pressure may produce a protrusion of mucosa and submucosa through the weakness just proximal to the obstructing cricopharyngeus.

*Formerly Fellow in the Department of General Surgery; present address: University Hospitals, 800 Northeast 13th St., Oklahoma City, Oklahoma.

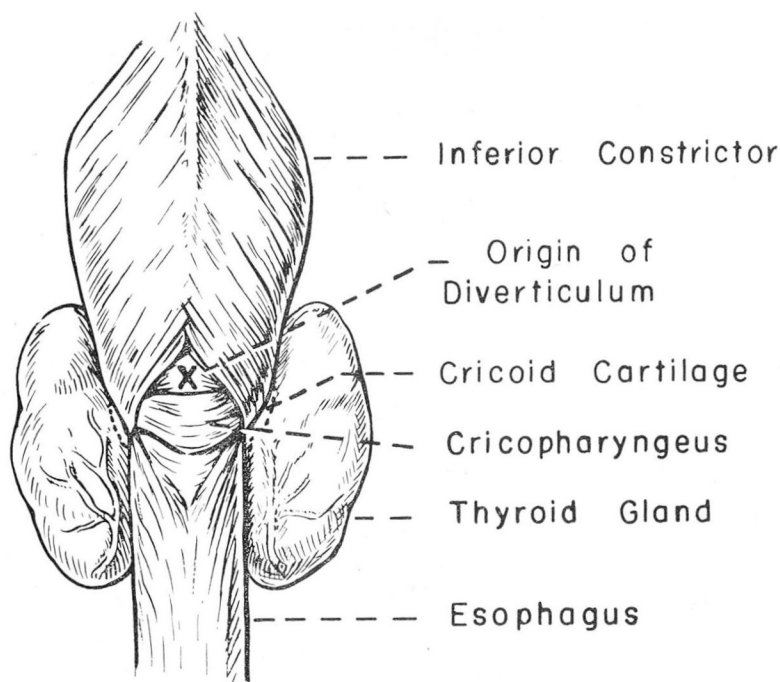


Fig. 1. Diagram illustrating the posterior pharynx and the most common site of origin of a pharyngoesophageal diverticulum.

By the pulsion of repeated swallowing, a small simple sac develops, producing a sensation of obstruction, as by a foreign body, or fullness in the throat which requires clearing of the throat. Large particles of food may “hang up” in the throat. These symptoms are transient and intermittent. The roentgenogram shows a simple midposterior sac at the level of the sixth cervical vertebra, with the orifice of the sac perpendicular to the axis of the esophageal lumen. No regurgitation or dysphagia is present. Lahey and Warren⁵ define this early stage in the formation of the diverticulum as stage I (Fig. 2).

The herniation slowly progresses to stage II; the sac lengthens and its fundus is forced downward into the left side of the neck between the prevertebral and pretracheal fascia. When the pouch becomes dependent it retains swallowed food, and new symptoms result.

As the volume of the sac increases it is accompanied by a sensation of greater fullness in the neck. Dysphagia is absent, but gurgling noises from fluid in the sac often embarrass the patient. Furthermore, when the patient is recumbent the retained food flows into the pharynx and the mouth, where it may be regurgitated, swallowed, or aspirated. Nocturnal regurgitation and aspiration may result in such complications as bronchitis, pneumonia, bronchiectasis, pulmonary abscess, or chronic laryngitis. A roentgenogram after a barium

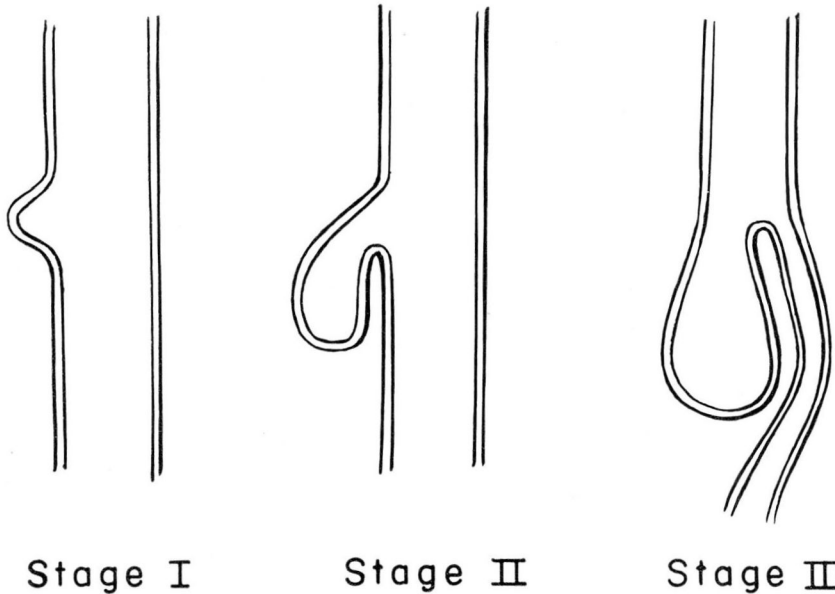


Fig. 2. Stages in the development of a pharyngoesophageal diverticulum (diagrams after Lahey and Warren⁵).

swallow demonstrates a transverse slitlike orifice in the pouch which is perpendicular to the esophageal orifice, and a dependent sac that retains barium.

Usually, after several years, the weight of the material retained in the sac drags its fundus toward the mediastinum. The orifice of the diverticulum now lies in the axis of the pharyngeal lumen, while the esophageal lumen is distorted and becomes perpendicular to the pharyngeal lumen. At fluoroscopy, barium is seen to descend in the pharynx into the diverticulum to fill it, and then to spill over into the proximal esophagus. In this stage III (Fig. 2), swallowing is obstructed, and the chief symptoms are dysphagia and regurgitation of most solid food. Although liquids are tolerated for a time, loss of weight and inanition may ensue. Eventually, complete esophageal obstruction may result. If the pouch enters the mediastinum, symptoms of fullness in the chest, dyspnea, palpitation, suffocation, coughing, and choking may occur. Rarely carcinoma or diverticulitis may occur in the pouch.

Treatment

Evolution of treatment of pharyngoesophageal diverticulum:

1877 *Diverticular-cutaneous fistula* established by Nicoladoni⁶ of Vienna.

1885 *One-stage excision* first successfully performed by Wheeler.⁷

1895 *Inversion* first employed by Girard.⁸

- 1907 *Two-stage excision* to prevent mediastinitis introduced by Goldmann.⁹
- 1910 (Stetten¹ summarized reports of the first 60 treated cases: 16 per cent operative mortality and only 40 per cent primary healing of wounds.)
- 1917 *Diverticulopexy* performed by Hill.¹⁰
- 1921 *Inversion* used by Bevan.¹¹
- 1934 (McClure¹² reported laryngeal obstruction from an inverted sac.)
- 1933-1953 *Two-stage excision* popularized by Lahey,⁵ who proved its safety and reliability in 365 cases.
- 1945 *One-stage excision* proved to be safe and reliable by Harrington,¹³ and in 1947 by Sweet,¹⁴ and by King.³
- 1944 *Inversion* revived by Ross,¹⁵ and in 1951 by Crile and Robnett.¹⁶

Treatment of patients in our series. From 1946 through 1957, two of us (G. C., Jr., and L. K. G.) operated on 37 patients who had pharyngoesophageal diverticula, employing a one-stage excision or an inversion procedure. Eighteen patients were treated with inversion procedures as described by Crile and Robnett.¹⁶ A purse-string suture is placed around the neck of the sac, and just before the sac is inverted an Ewald tube is passed into the esophagus to outline its junction with the sac. Flexing the patient's neck facilitates passage of the tube. The tube is then partially withdrawn and the pouch is inverted into the pharynx. The base of the sac is closed by drawing tight the purse-string suture and the tube is passed again to insure against stricture. The muscularis of the pharynx is closed over the inverted sac with interrupted sutures, and the wound is closed, usually without drainage.

Nineteen patients were treated with one-stage excisions. The technic is a modification of that described by Sweet.¹⁴ An Ewald tube is introduced into the esophagus before the neck of the sac is clamped. The neck of the sac is then progressively excised proximal to a Kocher clamp and is closed with interrupted silk sutures. A second layer of sutures repairs the muscularis. The wound always is drained with a soft-rubber drain for three days. Penicillin and streptomycin frequently are administered until the patient is discharged on the fifth post-operative day.

Results

The 37 patients who were surgically treated have been followed for periods from several months to nine years. Of 18 patients treated with inversion procedures, 12 report excellent results with complete relief of symptoms and no complications (Table 1). Only one patient had a serious complication—a wound infection followed by recurrence of the sac and dysphagia for dry foods. One patient had a small abscess in the wound; one patient reports slight difficulty in swallowing pills and dry food. Two patients, who had large 90-cc. diverticula (5 by 10 cm.), occasionally sense the presence of the inverted sac which they

described as a "tab moving up and down in the throat when belching." Roentgenograms show that one patient had a small (1-cm.) pocket at the site of inversion, but this caused no symptoms.

Table 1.—*Results of treatment for pharyngoesophageal diverticulum by inversion or by excision in 37 patients*

Results*	Surgical procedures, no. of cases	
	Inversion	Excision
Excellent, asymptomatic	12	14
Slight dysphagia	1	2
Intermittent sensation of presence of inverted sac	2	0
Wound abscess	1	1
Wound abscess, recurrence, moderate dysphagia	1	0
Recurrence, symptomatic	0	1
Recurrence (1 cm.), asymptomatic	1	0
Horner's syndrome.	0	1
Recurrent nerve paralysis	0	0
Total	18	19

*No deaths occurred in this series.

Of the 19 patients treated with one-stage excisions, 14 report excellent results; they had uncomplicated postoperative courses and are asymptomatic. One patient had an abscess in the wound. In one patient a recurrence required reoperation. Two patients have difficulty in swallowing pills and dry foods. One patient had a transient Horner's syndrome that affected the right side.

Comment

In all of the patients in this series a one-stage operation was employed. The chief argument for using a two-stage procedure is to avoid mediastinitis. However, the treatment for mediastinitis due to a leak of the cervical esophagus is cervical incision and drainage; thus, if a one-stage excisional repair is drained adequately, this complication is avoided by prophylaxis.

Ross,¹⁵ and Crile and Robnett⁶ described how large inverted sacs will contract, atrophy, and cause little trouble; however, in our small series two patients who had large sacs are conscious of the inverted sacs occasionally when they belch. Therefore, excision is preferable in patients with extremely large sacs. On the other hand, when an extremely small diverticulum is found, the sac often constitutes only a small mucosal "bump," and from a practical point of view, it seems meddlesome to do more than invert such a sac. Sacs of average size can be treated satisfactorily either way.

Summary

It appears that two-stage operations for pharyngoesophageal diverticula are no longer required. Either inversion or excision of the sac is equally safe and satisfactory for most diverticula. However, large sacs are best treated by excision, and small sacs are best treated by inversion.

References

1. Stetten, DeW.: Radical extirpation of pharyngo-oesophageal pressure diverticula. *Ann. Surg.* **51**: 300-319, 1910.
2. Jackson, C., and Shallow, T. A.: Diverticula of oesophagus, pulsion, traction, malignant and congenital. *Ann. Surg.* **83**: 1-19, 1926.
3. King, B. T.: New concepts of etiology and treatment of diverticula of esophagus. *Surg., Gynec. & Obst.* **85**: 93-97, 1947.
4. Negus, V. E.: Pharyngeal diverticula; observations on their evolution and treatment. *Brit. J. Surg.* **38**: 129-146, 1950.
5. Lahey, F. H., and Warren, K. W.: Esophageal diverticula. *Surg., Gynec. & Obst.* **98**: 1-28, 1954.
6. Nicoladoni, K.: Cited in reference 5.
7. Wheeler, W. I.: Cited in reference 1.
8. Girard, C.: Cited in reference 5.
9. Goldmann, E. E.: Cited in reference 5.
10. Hill, W.: Cited in reference 5.
11. Bevan, A. D.: Diverticula of esophagus. *J.A.M.A.* **76**: 285-288, 1921.
12. McClure, R. D.: Pharyngeal or pharyngo-esophageal diverticulum; new operation: inversion and snare. *Am. J. Surg.* **24**: 732-745, 1934.
13. Harrington, S. W.: Pulsion diverticulum of hypopharynx at pharyngo-esophageal junction; surgical treatment in 140 cases. *Surgery* **18**: 66-81, 1945.
14. Sweet, R. H.: Pulsion diverticulum of pharyngo-esophageal junction; technic of one-stage operation; preliminary report. *Ann. Surg.* **125**: 41-48, 1947.
15. Ross, D. E.: Invagination operation for esophageal diverticulum. *Am. J. Surg.* **63**: 3-9, 1944.
16. Crile, G., Jr., and Robnett, A. H.: Treatment of pharyngo-esophageal diverticulum by inversion of sac. *Cleveland Clin. Quart.* **18**: 42-47, 1951.