

SURGICAL TREATMENT OF ESOPHAGEAL ATRESIA AND TRACHEO-ESOPHAGEAL FISTULA IN THE INFANT

LAURENCE K. GROVES, M.D.

Department of Thoracic Surgery

ESOHAGEAL atresia and the associated fistulas between the tracheo-bronchial tree and the esophagus form a highly significant group of congenital anomalies that is regularly seen in hospitals that have many obstetric and newborn patients. Twenty years ago these lesions were considered interesting but hopeless anatomic curiosities; now they are significant because they are curable. Untreated, this group of anomalies is lethal, whereas successful surgery results in a normally functioning upper gastrointestinal tract. Therefore, it is vitally important that the diagnosis be promptly made. At the present time the two commonest reasons for failure of treatment of this anomaly are the presence of other major anomalies and associated prematurity.

Anatomic Considerations

The embryologic aspects of esophageal atresia will not be discussed here, suffice it to say that interruption of esophageal continuity and fistulous communication between the esophagus and the tracheo-bronchial tree are commonly associated, and all of the theoretically possible combinations of esophageal discontinuity and fistula have been seen clinically. The fistula may extend from an upper blind esophageal pouch to the trachea, from the lower end of the esophagus to the trachea, or both esophageal ends may communicate with the respiratory tract. Esophageal discontinuity varies in length and there may be no fistula to the trachea. Conversely, a tracheo-esophageal fistula may be present without an interruption in esophageal continuity; this is the so-called "H" fistula.

In practice, it is important to know that more than 90 per cent of all patients have one basic form of this anomaly: namely, a blind, upper esophageal pouch, with the lower end of the esophagus communicating with the trachea; thus the trachea and the stomach are connected via the distal esophagus (Fig. 1). In our experience, the next most common form of the anomaly is an "H" fistula.

Diagnosis

Infants who have esophageal atresia usually have typical symptoms that are easy to identify. The infants will be "wet," i.e., will seem to have excessive saliva. With esophageal obstruction, they will be unable to swallow saliva and will aspirate it. Similarly in the presence of an "H" fistula, esophageal contents will cross into the respiratory tract and will precipitate respiratory distress. Also,

in most instances gastric secretions can regurgitate into the respiratory tract. The first attempts at feeding may have rather dramatic consequences. These considerations make it obvious that an alert nursing staff in the neonatal nursery will in most instances be able to suspect the diagnosis. Nursing personnel should, for that reason, be thoroughly educated in recognizing the signs of esophageal atresia and tracheo-esophageal fistula.

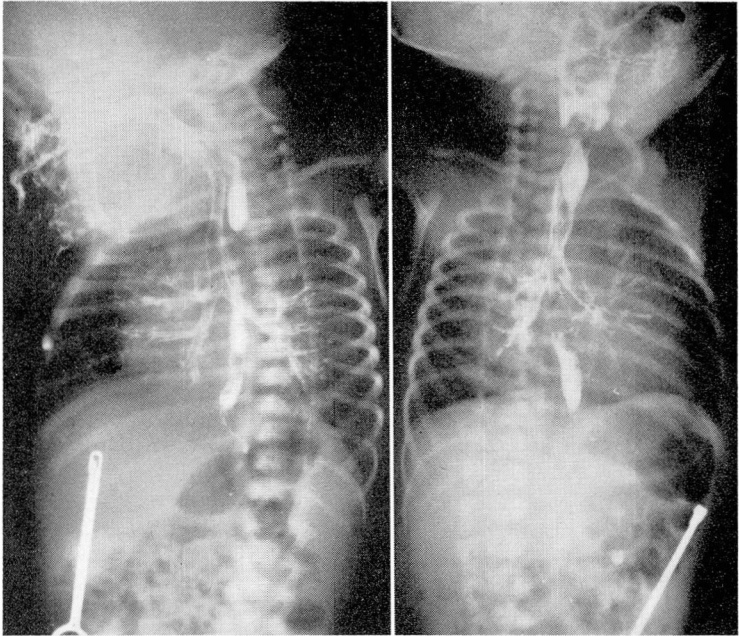


Fig. 1. Roentgen photographs that show evidence of the typical anomaly of esophageal atresia with tracheo-esophageal fistula. The infant in this case had been given more than the usual amount of contrast medium, which resulted in exceptionally clear outlines of the tracheobronchial tree and lower esophageal segment. Note the blind upper esophageal pouch filled with contrast medium; also the lower esophageal segment leaving the mid-tracheal region. There is evidence of considerable gas present in the gastrointestinal tract, which is proof that the distal esophagus communicates with the trachea.

In the usual type of the anomaly the diagnosis is readily confirmed by two procedures: (1) Attempts to pass a catheter into the stomach will be unsuccessful: the tube will "hit bottom" soon after it has passed through the pharynx. (2) If having made this first observation, 1 or 2 ml. of iodized oil are instilled into the catheter, and a roentgenogram is made, the evidence of a blind, esophageal pouch will be present. Frequently this small amount of contrast medium will be sufficient to result in a limited gratuitous bronchogram that demonstrates how easily the infant aspirates when he cannot swallow. Considerable additional information can be obtained from the roentgenograms. In most instances there will be evidence of air in the upper gastrointestinal tract, which proves the presence of the common type of anomaly with communication from the trachea

to the distal esophagus. The tendency for children with this anomaly to aspirate frequently results in pneumonitis, most commonly in the right upper lobe. The severity of the pulmonary changes can be readily assessed from the roentgenograms.

The "H" type of fistula without obstruction sometimes is an extremely difficult diagnosis to make. The fistula is easily overlooked both through the bronchoscope and the esophagoscope. It may be demonstrated by use of contrast medium and roentgenography; however, the presence of contrast medium in both the esophagus and tracheobronchial tree following oral administration of the medium does not indicate necessarily the presence of a fistula (Fig. 2). There

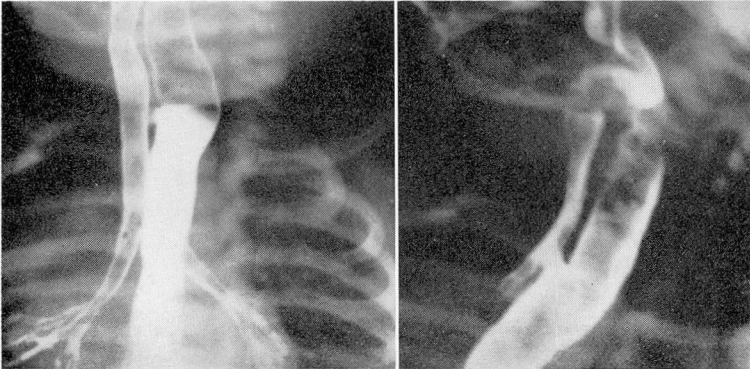


Fig. 2. Roentgen photographs that demonstrate evidence of an "H" fistula. Note that the level of the fistula is above the level of the first rib and thus is actually cervical in location; also, in the view on the right, that the contrast medium not only crossed at the level of the fistula, but also was aspirated through the larynx above.

is a significantly large group of infants with laryngeal and pharyngeal difficulties, usually neurologic, who are prone to aspirate, and whose symptoms may thus be mistaken for those related to fistulas. One of our patients was observed for more than a month before a fistula was conclusively proved by barium swallow and cinefluorography.

Preoperative Preparation

Although esophageal atresia must truly be considered a surgical emergency, it should be stressed that hours consumed in preoperative preparation are well spent. With the usual type of anomaly, the infant will have had no oral intake and, depending upon the time interval since birth, dehydration may be a serious factor. Time also well spent will be that taken to obtain satisfactory toilet of the tracheobronchial tree, and treatment of pneumonitis. However, it must be realized that as long as the condition remains uncorrected, the pulmonary problems will almost surely be self-perpetuating. A valuable maneuver in the preoperative care of the infant is the placement of a catheter on suction in the blind upper esophageal pouch. Continuous evacuation of this pouch in sump-drain fashion will minimize aspiration.

Surgical Technic

Thanks to the visionary surgical pioneering in this field performed by Haight,¹ Ladd,² and others,^{3,4} the direct anatomic correction of this anomaly has become a well-standardized and dramatically effective operative procedure. In a great majority of instances the anatomy is such that a take-down of the fistula and a direct end-to-end esophageal anastomosis are possible, and result in an anatomically and functionally normal swallowing mechanism.

We have currently been employing a conventional, right, posterolateral, transpleural thoracotomy approach through the fourth intercostal space. There usually is no difficulty in identifying the terminal esophagus and its fistulous communication to the trachea. This fistula is divided flush with the trachea, and the tracheal opening is closed with interrupted, fine-silk sutures. One of the postoperative complications has been the re-establishment of a fistulous communication, and for this reason it is wise to cover the site of tracheal closure with a flap of mediastinal pleura or areolar tissue.

Identification of the blind proximal end of the esophagus is facilitated by the dilatation which is usually present, secondary to the obstruction. It frequently saves time to have the anesthetist pass a soft-rubber catheter into the blind pouch, and exert gentle pressure. This readily demonstrates its position and facilitates mobilization.

Approximation of the two ends of the esophagus for anastomosis may be a problem. Usually, upward mobilization and gentle traction on the upper end with multiple stay sutures, thus converting a short, fat pouch into a long, narrow one, will overcome a deficit in length. The upper end, which may be hypertrophied, is mobilized, in preference to the narrow hypoplastic distal end, mobilization of which conceivably could jeopardize the blood supply. The anastomosis is basically one layer of silk (00000 or 000000 atraumatic) interrupted sutures. Occasionally some of the hypertrophied muscle from the upper end is pulled down over the anastomosis as a second layer. One should carefully avoid using excess sutures, lest they endanger the blood supply or create a diaphragmatic obstruction to the minute esophageal lumen.

It is our current practice after a primary anastomotic operation to thread one of the extremely small, modern, plastic catheters through the anastomosis into the stomach. This has been used initially for aspirating purposes and subsequently for feeding. Although we do not use it, gastrostomy must be entirely satisfactory, as other surgeons use it extensively for gastric decompression and feeding.

Unfortunately, occasionally simple, direct anastomosis is not readily feasible such as when the distal esophageal segment is short or entirely absent. Under such circumstances, the stomach can be progressively mobilized up through the esophageal hiatus, a method that probably is preferred if the upper esophageal end is of good length. Although anatomically feasible, it is technically rather formidable to anastomose the infant's stomach to the esophagus in the neck. If a primary anastomosis cannot be readily accomplished, three things must be done at the time of the initial operative procedure: (1) the fistula must be taken

down; (2) the upper esophageal end must be exteriorized in the neck, creating a salivary fistula so that pulmonary aspiration is avoided; (3) a feeding gastrostomy must be established for alimentation. We currently believe that such an infant should then be maintained on gastrostomy feedings for approximately two years, after which time, in a one-stage procedure, the right colon can be substituted for the esophagus through an extrapleural anterior mediastinal tunnel. Insufficient time has elapsed for us to have completed this operative approach for this particular anomaly, but success in applying this approach to caustic esophageal stricture has been so gratifying that we believe that this course will be more satisfactory than will a high thoracic transplantation of the stomach.

Postoperative Care

Specific problems in the postoperative care of the infants are related to management of the indwelling gastric tube, and to feeding. Infants normally are held in an upright position to be burped after feeding, yet in postoperative management this technic usually is forgotten and the infants are left in a horizontal position until the stomach overflows. Aspiration, or gastric dilatation, becomes a hazard. These difficulties can be avoided if great care is taken to keep the gastric tube patent. This is particularly important in the infant who has had an esophageal anastomosis. Vomiting past one of these minute anastomoses is hazardous for the baby—as well as hard on the surgeon's nervous system! Forty-eight hours postoperatively it has been our custom to initiate intermittent feedings through the indwelling tube. Intermittent feeding seems to be more physiologic than does a continuous drip, and the danger of overfilling the infant's stomach is largely avoided. Also, the tube is open between feedings, so that the baby may burp through it and avoid gastric distention. In our experience, a small plastic tube in the esophagus is well tolerated, and we have been in no hurry to remove it. The tube may have some value in preventing immediately postoperative strictures. However, if the child can swallow around the tube a week after surgery, it should be removed.

The distal limb of the anastomosis is always of extremely small caliber. It is remarkable how it dilates as soon as normal swallowing is restored. However, the anastomosis itself can be no bigger than the distal limb, and it is not surprising that anastomotic strictures frequently occur. We know of no way of predicting in which infant a stricture will develop, and for this reason we now believe that all of these surgically treated infants should have the caliber of the anastomosis checked not less than two weeks postoperatively. This is readily done by passing relatively stiff urethral rubber catheters, starting at approximately size number 10 French. If graduated catheters up to size numbers 16 or 18 can be passed, there seems to be little chance of future stricture. However, it is much easier to prevent a stricture than to dilate a well-established one, and we repeat the same procedure several weeks later, at the time of the first examination after discharge from the hospital. An established stricture usually can be

treated successfully from above; however, at least the first few dilatations should be done under direct vision, treatment that will not be discussed here.

Summary and Conclusions

Esophageal atresia and tracheo-esophageal fistula are related anomalies that occur fairly often in newborn infants. It is stressed that these lesions are surgically curable, congenital defects and, therefore, early diagnosis and prompt treatment are extremely important. The diagnosis can be readily suspected by mere observation of the infant, and nursing personnel should be thoroughly indoctrinated in this regard.

References

1. Haight, C., and Towsley, H. A.: Congenital atresia of esophagus with tracheoesophageal fistula. *Surg., Gynec. & Obst.* **76**: 672-688, 1943.
2. Ladd, W. E.: Surgical treatment of esophageal atresia and tracheoesophageal fistulas. *New England J. Med.* **230**: 625-637, 1944.
3. Gross, R. E.: *The Surgery of Infancy and Childhood: Its Principles and Techniques.* Philadelphia: W. B. Saunders Co., 1953, 1000 pp., p. 75.
4. Haight, C.: Some observations on esophageal atresias and tracheoesophageal fistulas of congenital origin. *J. Thoracic Surg.* **34**: 141-172, 1957.