

## NONCHROMAFFIN PARAGANGLIOMA OF THE GLOMUS JUGULARE

### Review of the Literature and Report of Six Cases

WILLIAM A. HAWK, M.D., and LAWRENCE J. McCORMACK, M.D.

Department of Anatomic Pathology

THE uncommon neoplasm of the temporal bone known as the "glomus jugulare tumor," "chemodectoma" or "non-chromaffin paraganglioma" of the glomus jugulare has been widely discussed in medical literature since the true nature of this neoplasm was recognized by Rosenwasser.<sup>1</sup>

The prior recognition that nonchromaffin paraganglionic structures existed in the region of the temporal branch of the jugular bulb is credited to Guild.<sup>2,3</sup> Zettergren and Lindström<sup>4</sup> confirmed the observation of Guild,<sup>3</sup> who described the glomus jugulare as being composed of one or more "jugular bodies," the average number being about three per ear. He stated that the sites of more than half of these jugular bodies are the adventitia of the dome of the jugular bulb and the portion of Jacobson's or Arnold's nerves in the jugular fossa. In one fourth of the patients, glomic bodies were in the mucosa of the cochlear promontory in association with the tympanic plexus of Jacobson's nerve. In one fifth of the patients, jugular bodies were in the tympanic canaliculus, and in other patients they were in the descending facial canal.

The normal histologic appearance of the glomus jugulare is generally considered to be similar to that of the carotid body.<sup>2, 3, 5</sup> Guild<sup>2, 3</sup> found that using material from the temporal bone impeded the study of the cytologic details because extensive decalcification first was necessary. He described the structure as an aggregate of capillary or precapillary sized blood vessels arranged in coils or loops about nests of epithelioid cells; venules, in contrast, were straight. A fibrous capsule surrounded the entire structure, and fibrous septa continuous with the capsules were in the larger glomera. Furthermore, he noted variation in the proportion of epithelioid and vascular elements in the several glomera in one patient. In some glomera the epithelioid cells predominated; whereas, in others the vascular elements were most prominent. However, within a given ear with more than one glomic structure the histologic appearances of the glomera were likely to be the same. Nonmedullated nerve fibres supplied the glomic structure and were between the epithelioid cells. The size of the nerve entering the structure was unusually large for the size of the structure innervated, but the type of nerve ending was indeterminate. The chromaffin reaction of the epithelioid cells was negative.

Huppler, McBean, and Parkhill<sup>6</sup> may have disclosed a physiologic function of the glomus jugulare. Their provocative case supports the assumption that the behavior of the glomus jugulare is similar to that of the better-known members of the nonchromaffin paraganglia, the carotid and aortic bodies. The patient had

episodes of dizziness and "blacking out" initiated by coughing, sneezing, yawning, and breathing deeply in succession several times. They point out that at high altitudes the normal person constantly overbreathes and thus decreases his carbon dioxide tension and buffer base. The patient with the apparently functioning tumor chronically had to overbreathe; as a consequence he was subject to symptoms of hyperventilation—the "blacking-out" episodes.

The similarity of structure, innervation, and neoplasms of the glomus jugulare to those of other nonchromaffin paraganglionic members of the chemoreceptor system, i.e., carotid and aortic bodies, paraganglion intravagale or juxtavagale, and paraganglion ciliare, warrants inclusion of the jugular bodies in this system.<sup>7-11</sup> The embryogenesis, physiologic functions, and histologic features of the carotid and the aortic bodies have been well delineated,<sup>12-32</sup> and just as these structures arise in close association with the cranial nerves and branchial arches so apparently does the glomus jugulare. Histologically there appear to be no significant differences among other members of the chemoreceptor system. The rare, functioning neoplasms of the glomus jugulare tend to confirm similar physiologic functions.

Tumors of the glomus jugulare have been recognized in six patients at the Cleveland Clinic, two of whom eventually died, and were studied at necropsy. These patients had most of the clinical and pathologic features characteristic of these neoplasms.

### Case Reports

**Case 1.** A 28-year-old white woman was first examined here in March, 1940, because of ataxic gait, and mild vertigo. About three years previously (July, 1937) she noted the onset of an imminent dysphasia associated with loss of fluids through the nose, and the sensation of obstruction at the cricoid level; this condition became severe when she was tired or nervous. About January, 1939, she began to have persistent hoarseness. Six months later (June, 1939) she commenced to have frequent nausea and vomiting, and deafness in the left ear. Apparently intermittent tinnitus had been present since 1937. At no time did she have headaches.

Otolaryngologic examination disclosed a red and thickened area in the posterior portion of the left tympanic membrane, which had the gross appearance of granulation tissue. There was severe loss of hearing in the left ear. The left vocal cord was in the cadaveric position and did not move during phonation. Neurologic examination disclosed nystagmus on lateral gaze bilaterally. The left corneal reflex was absent, but no extraocular palsies were noted. The left side of the tongue was atrophic and upon protrusion was deflected to the left. There was paralysis of the left side of the palate and pharynx with anesthesia of the left posterior pharyngeal wall. The left sternocleidomastoid and rhomboid muscles were atrophied and weak. The abdominal reflexes were absent. The gait was unsteady and the Romberg's sign was present as evidenced by a slight swaying. Roentgen examination of the skull showed inconclusive evidence of changes in the mastoid area, and no abnormalities of the petrous bones.

The patient was admitted to the hospital and an aspiration biopsy of the left middle

ear was attempted. One week later a suboccipital craniectomy was performed. At operation a soft, gray-and-reddish irregular mass of tissue was observed along the left side of the medulla. The surgeon palpated a loss of part of the left petrous bone. Neoplastic tissue appeared to have grown through the occipital bone to involve the overlying muscles. A biopsy specimen was taken and the pathologic diagnosis was hemangioendothelioma. A subsequent review reclassified this neoplasm as a non-chromaffin paraganglioma of the glomus jugulare.

After the operation the patient was given irradiation therapy of 5,550 r to the neoplastic area. The neurologic defects remained substantially the same, though the gait, swallowing, and phonation improved. She had experienced no increase in severity of symptoms when last seen in 1948.

**Case 2.** A 48-year-old white woman was first examined here in September, 1950, because of almost total loss of hearing. Six years previously (1944) a mass and tinnitus developed in the right ear. A biopsy specimen was studied in 1945 and was reported to be a hemangioma. Following the biopsy there was considerable foul-smelling purulent discharge from the external auditory canal. The patient was given irradiation therapy; the size of the aural mass decreased considerably. During the next five years loss of hearing in the right ear increased notably, and by 1950 it was almost complete.

Physical examination here disclosed a large polypoid tumor that filled the right external auditory canal. The mass was lobulated, firm, crusted by a purulent exudate. A biopsy specimen was studied; the pathologic diagnosis was nonchromaffin paraganglioma. The patient was returned to her family physician with the advice to have further radiation therapy. She has not been examined since.

**Case 3.** A 62-year-old white man was first examined here in April, 1950, because of poor physical balance of two years' duration. This difficulty was first noted when, after walking up a grade, he suddenly "blacked out" and remained unconscious for several moments. Since that episode his balance was poor, he walked as though he were drunk, and he sometimes staggered or fell to the left. Coughing or sneezing occasionally precipitated such episodes. In addition, he had a roaring sensation in the left ear, and soreness gradually developed in the left temporoparietal area. For a period of about four months he had episodes of vague soreness in the shoulders and weakness in both arms; these lasted about 30 minutes and occurred weekly. Two weeks prior to examination here the soreness became worse; he noticed weakness of the left side of the mouth, difficulty in closing the left eyelid, some dysphasia, and difficult articulation; there was considerable deafness of the left ear since the onset.

Thirty years previously he had sustained an injury to the head. A review of the systems revealed some recurrent episodes of epigastric distress which apparently were well controlled by diet. A renal calculus had been removed in 1945 and more recently the patient had nocturia.

At physical examination the blood pressure was 160/94 mm. of Hg. The left palpebral fissure appeared widened and showed weakness on closing. The tympanic membranes were normal. Palpation of the abdomen disclosed a firm smooth mass on the right side. Neurologic examination revealed nystagmus, bilateral weakness of the left eyelid and the mouth, marked diminution in hearing in the left ear, and tinnitus described as "a puffing train." The Romberg's sign was present, and deviation of the gait to the left was noted. There were no other significant physical or neurologic findings..

Roentgen studies showed evidence of erosion of the superior portion of the left petrous ridge and the region of the external auditory canal. An encephalogram and arteriograms were reported as showing normal findings.

A left suboccipital craniotomy was performed. From the lateral wall of the temporal bone just above the porus acusticus internus a cherry-sized nodule of soft, cystic, reddish tissue protruded externally to the dura and above the jugular bulb. The mass pulsed with heartbeats. A biopsy specimen was obtained and confirmed the clinical impression. Brisk hemorrhage ensued, which was controlled with difficulty. As it was impossible to remove the tumor, the vestibular portion of the eighth nerve was sectioned and the procedure was terminated.

The patient made a good postoperative recovery. Since the neoplasm could not be completely removed, a course of radiation therapy was given: 2,000 r in air was given to each of three portals. The left facial weakness remained, but the staggering gait was greatly decreased. The tenderness in the shoulders and the transient dizziness persisted.

In February, 1951, a tarsorrhaphy was performed on the left eyelid. Some return of function of the seventh cranial nerve was noted, particularly of the left frontal and superorbital muscles. The patient continued to improve until January, 1953. Examination at that time disclosed in the scalp above the left ear a swelling that pulsed synchronously with heartbeats. The seventh cranial nerve palsy was then complete, but no other new neurologic findings were noted. A roentgenogram of the skull showed evidence of further destruction of the squamous and the petrous portions of the left temporal bone. For the first time the left tympanic membrane bulged and the landmarks were lost. Further radiation therapy was given at another hospital, and when last seen in March, 1954, there was further enlargement of the mass above the left ear.

**Case 4.** A 34-year-old white woman was first examined here in July, 1951, because of loss of hearing in the left ear of approximately four years' duration. In December, 1950, she was examined by a physician who discovered a mass in the left auditory canal; part of the mass was excised. There was no improvement in her hearing.

Examination here disclosed a large, polypoid, pedunculated, epithelial-covered mass in the left external auditory canal. There was a notable conduction type of deafness of the middle ear. An aural polypectomy was performed, but the lesion could not be entirely removed. One month later a radical mastoidectomy was performed; neoplasm filled the entire middle ear and extended through the aditus into the antrum. Apparently complete removal was possible. Microscopic sections of this tissue showed it to be identical to that of the lesion removed from the external auditory canal; a diagnosis of nonchromaffin paraganglioma was made.

There was no recurrence of the lesion for one year after radical removal, but, upon examination nearly four years postoperatively, in April, 1955, there was a suggestion of recurrence as a small zone of reddish discoloration in the operative site. A biopsy specimen of this material in February, 1958, was diagnosed as recurrent neoplasm.

**Case 5.** A 49-year-old white woman was first examined here in March, 1952, because of tinnitus of four years' duration of the right ear. Previously she had consulted her family physician who diagnosed the condition as chronic tonsillitis; she underwent a tonsillectomy and was unimproved. In April, 1951, she experienced some loss of hearing and a right aural polyp was discovered. A polypectomy was performed and complete loss of hearing in that ear ensued. In October, 1951, a transient right facial

weakness developed and lasted for two weeks. At the same time there was some pain in the right eye, which persisted and was present at the time of her examination here. In March, 1952, the facial weakness again returned, and with it the inability to close the right eye. Headaches, diplopia, or equilibratory disturbances were absent.

Physical examination here disclosed a complete loss of hearing in the right ear. No caloric response could be elicited. The right tympanic membrane was largely replaced by scar tissue. Neurologic examination disclosed hypesthesia of the right trigeminal nerve in all divisions. Palsies of the seventh through the twelfth cranial nerves with right lingual atrophy were noted. A roentgenogram of the skull showed evidence of only some clouding of the mastoid air cells on the right, interpreted as a chronic mastoiditis.

A right suboccipital craniotomy was performed in June, 1952. A neoplastic mass lay along the floor of the posterior fossa. A frozen section of a biopsy specimen was reported as a nonchromaffin paraganglioma. The neoplasm could not be excised and the operative procedure was terminated. The patient remained unconscious until the fourteenth postoperative day when, despite supportive measures, death occurred from bronchopneumonia.

*Necropsy findings.* At necropsy, extensive involvement of the right temporal bone was present. Protruding from the internal auditory meatus was a polypoid, firm, reddish, slightly granular mass that was 1 cm. in diameter (*Fig. 1*). Beneath the mass was a

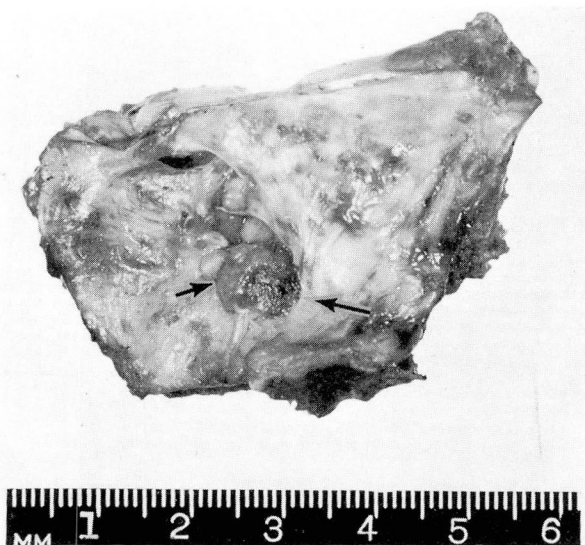

Fig. 1. Case 5. Photograph of the petrous portion of the temporal bone showing mass of neoplastic tissue protruding through the internal auditory canal.

large conglomeration of soft gray-yellow tissue that partially displaced and had destroyed the petrous portion of the temporal bone and the medial portion of the mastoid process, almost at the level of the styloid process (*Fig. 2*). A tongue of tissue extended anteriorly and extradurally to the region of the pituitary fossa, but did not encroach



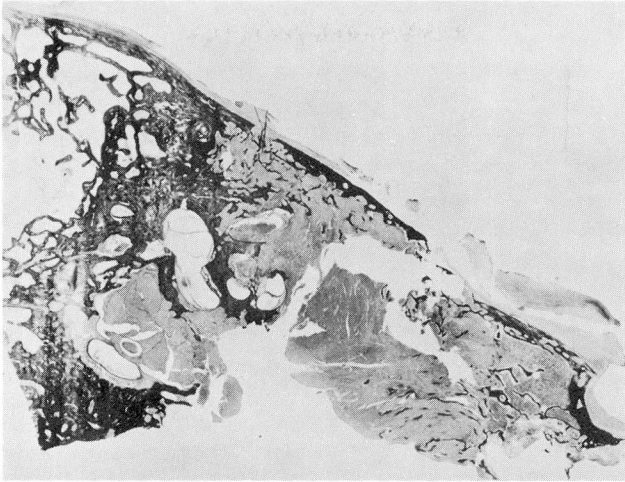


Fig. 2. Case 5. Photomicrograph of a celloidin mount of the coronal section of the petrous portion of the temporal bone showing neoplastic invasion of the petrous ridge and the mastoid air cells.

upon it. Caudally, at the exit of the jugular foramen, the tumor surrounded the jugular bulb and the jugular vein for a distance of 1.0 cm.

Sections of the neoplasm removed for biopsy, and at necropsy, showed the tumor to be comprised of small-sized polyhedral and spindle cells with hyperchromatic oval to elongated nuclei and granular acidophilic cytoplasm (Fig. 3). The cell margins often were indistinct. In some areas the neoplastic cells were arranged in cords and ill-defined masses; in other areas an alveolar arrangement was comprised of well-defined cell nests. Numerous capillary-sized endothelial-lined spaces were present, and were separated from the conglomerations of neoplastic cells by delicate bands of connective tissue (reticulum) (Fig. 4). Rather broad septa of hyalinized connective tissue traversed the tumor, often isolating nodular areas of the neoplasm. Mitotic figures were not seen. Zones of necrosis and rare zones of calcification were present.

**Case 6.** A 56-year-old white man was first examined here in October, 1953. He had been in apparently good health until three months before, when he noticed gradual loss of vision in the left eye, drooping of the left eyelid, and increasing headache. Shortly after the onset he became dizzy and acquired a staggering gait; early in October he noted difficulty in swallowing, also slurring of speech.

Physical examination disclosed a dilated, fixed, left pupil, absence of left corneal reflex, and presence of palsy of the left oculomotor nerve. There was hypalgesia of the left fifth cranial nerve, weakness of the facial nerve, decreased hearing bilaterally, and an inability to swallow. Babinsky's, Gordon's, and Hoffmann's signs were present bilaterally, and the abdominal reflexes were absent bilaterally. Romberg's sign was present as evidenced by a gait that was notably ataxic. The spinal fluid pressure was 110 mm. of water. Analysis of the fluid showed: a faint trace of globulin, a negative serologic test, and a normal colloidal gold curve. Roentgen examination of the skull

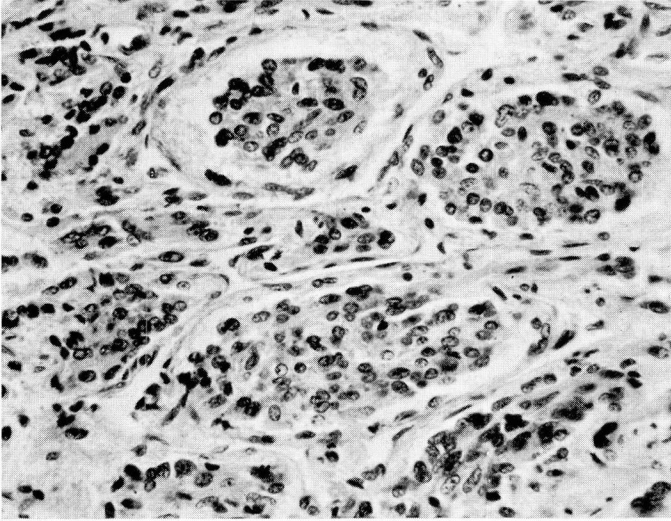


Fig. 3. Case 5. Photomicrograph of neoplasm showing the well-defined nests of the glomerular cells separated by abundant vascular network. Hematoxylin-eosin—methylene blue stain; magnification X 250.

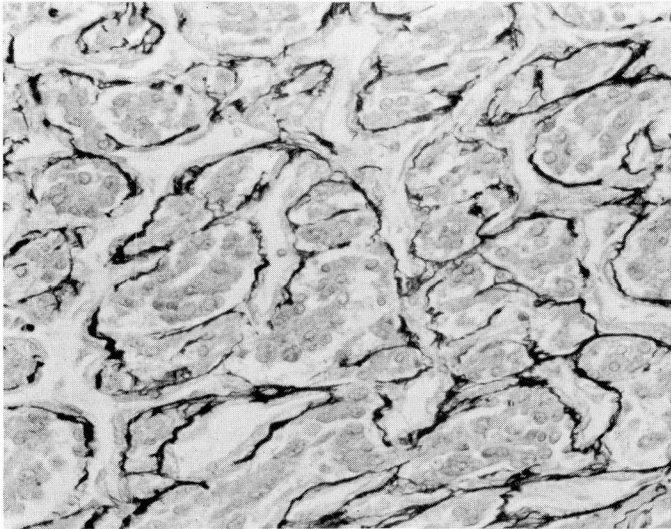


Fig. 4. Case 5. Photomicrograph of neoplasm showing argyrophilia of capillary basement membranes. The cellular aggregates are not a part of the vascular channels. Wilder's reticulin stain; magnification X 250.

disclosed evidence of widening of the left internal auditory canal, of destruction of bone along the left petrous ridge, and of erosion of the dorsum sellae.

On October 30, 1953, a right suboccipital craniotomy was performed. When the pontine cistern was entered, a lobular, vascular mass the size of a small cherry was disclosed above and anterior to the auditory nerve well forward of the petrous apex. The surrounding dura was extremely vascular, as was the tumor. The mass appeared to arise from the apex of the petrous bone approximately at the point where the trigeminal nerve should have crossed, but the nerve itself was nowhere in evidence. The patient failed to rally from the operative procedure and died on the ninth postoperative day.

*Necropsy findings.* At necropsy, a cherry-sized polypoid mass was seen at the apex of the petrous ridge along with destruction of the medial 2 cm. of the structure. The tumor surrounded the fifth cranial nerve at that site, and extended laterally into the mastoid air cells. There were no other significant gross findings. Microscopically the specimens of tissue removed at operation and at necropsy showed identical histologic structures. The neoplasm was formed by cells that were somewhat spindly, or sharply curved. The nuclei were vesicular, hyperchromatic, and somewhat irregular in outline. The cytoplasm was scanty, granular, and acidophilic. Mitosis was prevalent. The neoplastic cells were arranged principally in solid masses that were traversed by numerous endothelial-lined vascular channels, usually of capillary size but occasionally one was larger. Reticulum stains outlined numerous small-sized vascular channels, and revealed delicate reticulum fibers extending into the neoplasm from the vascular channels. The neoplastic cells were closely related to the vascular channels but were separate from them.

#### Clinical Features

Nonchromaffin paragangliomas occur in women three times as often as in men. The age of onset in both sexes ranged from 17 years to 85 years, with an average age of approximately 47 years. In general, the duration of symptoms before diagnosis is long, averaging about seven years, within a range of about six months<sup>33, 34</sup> to more than 20 years.<sup>35-40</sup> One hundred and ninety published cases<sup>1,2,5,6,8,9,14,15, 33-101</sup> with abstracts of 165 of these cases are available to us. These and our own six cases are the basis of an assessment of the clinical features. The symptoms and findings associated with these neoplasms are variable, but may be classified into three groups: (1) principally otic, (2) otic and neurologic, and (3) (the smallest group) primarily neurologic. In a slightly different fashion, Bickerstaff and Howell<sup>68</sup> classified 90 reviewed cases into four groups based on the order of appearance of symptoms; i. e., Group I (49 cases), aural symptoms only; Group II (20 cases), neurologic symptoms developing many years after aural involvement; Group III (17 cases), neurologic and aural symptoms developing concurrently; and Group IV (4 cases), neurologic involvement before aural symptoms.

The clinical features most commonly noted are the presence of an aural polyp, loss of hearing, otorrhea, facial nerve palsy, and pain. The lesions affect the right side about as often as the left: in 145 cases the side that was affected was recorded,



and the right side was involved 69 times, the left 76. In most instances, tinnitus was an associated symptom, variably described as roaring, blowing, or pulsating, and often synchronous with the pulse rate. Polypoid masses were observed in the external auditory canal in 106 patients, and bluish or reddish discolorations of the tympanic membrane often associated with bulging of the tympanic membrane in other patients. Capps<sup>71</sup> has published excellent colored plates of the appearance of the tympanic membrane at various stages of the disease. In a few patients, spontaneous bleeding occurred presumably as a result of ulceration; in all patients in whom biopsy was attempted, some measure of hemorrhage was encountered. A bruit was heard over the mastoid process in a few patients. A discharge, usually similar to that in recurrent otitis media, or of a watery character, was observed in 63 patients. Pain in the ear was noted in 33 patients and was usually referred to the involved ear. In two of these the pain was somewhat similar to that recorded for tic douloureux.<sup>33, 37</sup> Pain, however, more often occurred late in the disease and generally was dull in character. Several patients remarked that their ears felt "stuffed up." Roentgen findings have been described in almost all cases. These usually include evidence of erosion of the petrous portion of the temporal bone, sclerosis of the mastoid air cells, and enlargement of the jugular foramen.<sup>65, 74, 95</sup>

Approximately 50 per cent of the cases analyzed reported neurologic signs and symptoms usually in the form of cranial nerve palsies. Henson, Crawford, and Cavanagh<sup>48</sup> reported an incidence of 40 per cent in the 77 cases they analyzed, and Bickerstaff and Howell<sup>68</sup> found 65 per cent cranial nerve palsies in their 90 cases. In most of the patients the neurologic symptoms developed after the aural signs and symptoms. The cranial nerves involved were usually the seventh through the twelfth on the affected side, though the fifth and sixth nerves occasionally were involved; of 171 patients, 17 had involvement of the fifth nerve, 15 of the sixth nerve. Figi and Weisman<sup>98</sup> describe one patient whose third through the twelfth cranial nerves were affected. In the collected cases, the facial nerve was involved 65 times, the glossopharyngeal nerve 40 times, the vagus 40 times, the spinal accessory nerve 29 times, and the hypoglossal nerve 36 times. These statistics are not in agreement with those of Henson, Crawford, and Cavanagh<sup>48</sup> who reported a considerably higher incidence of involvement of the ninth through the twelfth cranial nerves. However, a good proportion of the patients considered were seen during the aural aspect of the disease, and perhaps were prevented from having further immediate progression of the disease. Siekert<sup>97</sup> catalogued the neurologic abnormalities in 33 patients with paragangliomas of the glomus jugulare. He found that the facial nerve was involved in 27 patients, and other neurologic defects were present in 14.

Henson, Crawford, and Cavanagh<sup>48</sup> state that the earliest neurologic symptoms are dryness and stiffness of the tongue, a sense of pharyngeal irritation, dysphasia, and aphonia. Such symptoms were observed in part in one of our patients (case 1). They also point out that the hypoglossal nerve often is involved before the

ninth, tenth, and eleventh cranial nerves are. Nystagmus has been described frequently and may be vertical, horizontal, or even rotatory as in our case 5. Ataxia has been a frequent symptom and was present in three of our patients. In one patient (case 3) it was completely alleviated by sectioning the vestibular portion of the eighth cranial nerve.

Less common and unusual symptoms may be observed. In one patient (case 6) the presenting complaint was gradual loss of vision in the left eye and drooping of the left eyelid. Episodes of dizziness and syncope were presenting complaints (case 3), precipitated by coughing, sneezing, hyperventilation and physical exertion. Huppler, McBean, and Parkhill<sup>6</sup> described a patient with similar difficulties and, as for our patient, relief was obtained by radiation therapy. Pyramidal tract signs have also been observed, though they are uncommon.<sup>33, 37, 48, 54</sup> Papilledema is an extremely rare phenomenon, and was noted in three cases.<sup>42, 85, 96</sup> In Zacks<sup>9</sup> second case the papilledema was associated with personality changes and dysphagia. Hemianopsia has been reported but rarely.<sup>91</sup>

Although this disease may have protean manifestations, a history of increasing deafness, chronic recurrent discharge from the external auditory canal, the appearance of cranial nerve palsy, and the presence of a polypoid mass in the auditory canal and protruding through the tympanic membrane should arouse a high index of suspicion for the diagnosis of a neoplasm of the glomus jugulare.

Of interest is the observation that neoplasms of the glomus jugulare may show a familial tendency. According to Winship and Louzan,<sup>50</sup> Bartels published an exhaustive study of the disease entity and described not only a familial tendency but a multicentricity of lesions occurring in members of the same family. Seven persons of one family, including three generations, had neoplasms of the glomus jugulare, of the carotid body, or of both structures. Three sisters had tumors of the glomus jugulare, and died as the result of the disease;<sup>47</sup> and other reports of familial occurrence have been published.<sup>50</sup>

### Pathologic Features

Grossly, the tumors of the glomus jugulare vary; often they are polypoid and fill the entire middle ear. Characteristically, they slowly expand and, depending upon their origin, they may extend outward into the external auditory canal, or may grow through the petrous pyramid or the internal auditory canal. After extension into the cranial vault, they most often grow extradurally (cases 1, 5, and 6), but may extend through the dura.<sup>34, 46, 48, 57, 73, 94, 95</sup> The tumors may grow forward toward the clinoid processes or posteriorly into the posterior fossa (cases 1, 3, and 5). In one patient the jugular foramen was completely closed by the tumor,<sup>48</sup> and in another patient the tumor arose in the jugular foramen.<sup>62</sup> Contiguous structures are obviously encroached upon and symptoms vary according to the fortuitous location of the expanding neoplasm. Within the middle ear itself the destruction of adjacent bone easily permits extension into the mastoid; one

tumor extended into the nasopharynx.<sup>55</sup>

Grossly, the cross sections of the neoplasms are variable. One tumor was described as grayish-brown and spongy with a few calcareous deposits;<sup>33</sup> another was grayish-white, smooth and polypoid;<sup>55</sup> in two of our patients the tumors were smooth, firm, and grayish-pink. Most of the descriptions emphasize the marked similarity to granulation tissue.

The microscopic appearance of these neoplasms is pathognomonic. There is a high degree of vascularity. The blood vessels are thin-walled, of capillary size, composed of a single layer of endothelium, and supported by delicate reticulum. Conglomerate masses of "epithelioid cells" are arranged in close proximity to the blood vessels and thus form an alveolar arrangement in some areas. These cells are polygonal or round, with pale-staining acidophilic cytoplasm that usually contains fine acidophilic granules. The cell boundaries often are indistinct, as exemplified in our case 3. Phosphotungstic acid-hematoxylin stain reveals a small amount of collagen between the individual nests of neoplastic cells. Lattes and Waltner<sup>5</sup> pointed out that silver stains for reticulin show an argentophilic framework composed of delicate reticulin fibers that branch from the subendothelial membranes of the vessels and surround nests of neoplastic cells. In only one of our cases (case 6) was mitosis prevalent; this is an uncommon finding. The chromaffin reaction has been reported as negative by those who have done it.<sup>5,42,56</sup> Lattes and Waltner<sup>5</sup> found a few axons between tumor cells. Zak<sup>42</sup> reported negative reactions of the neoplasm in regard to alkaline phosphatase and acid phosphatase, and to lipase. Zacks<sup>9</sup> found cholinesterase, phospholipids, and small amounts of neutral fat in the neoplastic cells but no glycogen.

Malignancy is a rare feature of these neoplasms, but though they are regarded as benign, anatomically they are potentially lethal. A few well-documented cases of malignancy have been reported;<sup>5,47,48,56,74,76</sup> metastasis occurred to the jugular lymph nodes, liver, lung, and bone, and the lesions were identical with those of the primary tumor in the middle ear.

Multicentric involvement of the various nonchromaffin paraganglia has been reported.<sup>5,9,15,49,61,100</sup> Kipkie,<sup>49</sup> it is believed, reported the first instance of a tumor of the glomus jugulare occurring in conjunction with a carotid body tumor on the contralateral side; Lattes and Waltner<sup>5</sup> reported a similar case, and Zacks<sup>9</sup> recently reported a case of nonchromaffin paragangliomas involving the carotid body, glomus jugulare, and retroperitoneum. Lattes<sup>15</sup> reported two cases of multicentric lesions of the chemoreceptor system, neither of which involved the glomus jugulare. McNeill and Milner<sup>93</sup> treated a patient who had bilateral neoplasms of the glomus jugulare; the type of neoplasm of the right ear was not histologically confirmed. Zak<sup>42</sup> considers Von Hippel-Lindau's disease as an example of multicentric neoplasia, and evolved a new concept that glomic tissue is the origin for cerebellar angioblastoma, Von Hippel-Lindau's disease, and related supertentorial neoplasms.

## Prognosis and Treatment

In reviewing the cases, we have a distinct impression that many patients are apparently free of gross evidence of disease for variable periods of a few months to several years. There are many instances in which the course of the disease extends over a period of many years.<sup>5,36-40,47,57,77,89,92</sup> In one patient there was no evidence of recurrence 17 years after radical mastoidectomy and radium implantation.<sup>47</sup> However, the disease is a slowly progressive one as indicated in our patients by the average duration of symptoms, which is 7.4 years after operation. For the most part, follow-up information is too recent postoperatively to allow accurate prognostication at this time. Perhaps the reason that the prognosis in regard to these lesions is so poor is because symptoms arise from the slow, expansile growths and, when the symptoms are of sufficient severity that the patient seeks medical aid, the tumor has already enmeshed itself within the architectural intricacies of the temporal bone, making removal difficult if not impossible.

The treatment of these neoplasms, expressed in general terms, has been surgical, radiative, either with roentgen ray or radium; some have been merely followed. Whenever possible, surgical removal of the tumor has been attempted, and has met with some measure of success when the lesion was largely confined to the middle ear.<sup>5,35,38,44,47,76,99</sup> Radical mastoidectomy has been most frequently employed. Shambaugh<sup>99</sup> has described a technic for hypotympanotomy when the lesion is limited to the hypotympanum and the tympanic cavity. In a number of instances this operation has been combined with a course of radiation therapy. Many patients have gone two years or more without recurrence.<sup>5,34,39,44,47,64,95</sup> Radiation alone has been employed less frequently and with some measure of success.<sup>5,34,39,47</sup> Stewart, Ogilvie, and Sammon<sup>92</sup> believe that irradiation causes endothelial proliferation within the vessels of the tumor, and that the resulting decrease in vascularity reduces the size of the tumor. They doubt that there is any marked effect on the neoplastic cells per se. Alexander, Beamer, and Williams<sup>37</sup> treated a patient with 2,080 r in air through each of two occipital portals, and six weeks later administered an additional 9,000 r through a right occipital portal. Two years later the patient was significantly improved. Angiograms taken after the first course of roentgen therapy and again eight months later showed less vascularity of the tumor. Riemenschneider, and associates<sup>65</sup> expressed pessimism concerning the value of radiation therapy for this disease. When neurosurgical procedures have been necessary the mortality has been high. In only one patient was the entire intercranial neoplasm successfully removed.<sup>37</sup>

Our own experience parallels much of that mentioned. Two patients (cases 1 and 3) were treated essentially by roentgen therapy after the suboccipital craniotomies had accomplished little more than providing histologic proof of the type of tumor. In the one patient (case 3) a division of the vestibular portion of the eighth cranial nerve was beneficial. There has been no progression of the disease for eight years in one patient (case 1), though she still has residual tumor. Case



3 illustrates the slow, relentless progression of the neoplasm for four years after roentgen therapy.

In one patient (case 4) only, a radical mastoidectomy was performed. Five years after surgery a small reddish discoloration developed in the mastoid cavity; it slowly grew larger, and in February, 1958, it was removed and was found to be a recurrence.

In general, the prognosis must be considered guarded, but there is the optimistic note that with early diagnosis treatment may be helpful. When surgical removal is possible this would seem to be best, particularly when the lesion appears to be confined to the middle ear and to the adjacent mastoid. Irradiation therapy is of some value when surgical removal cannot be complete. Occasionally neurosurgical procedures may be necessary.

One additional therapeutic note is worthy of mention. Ligation of the external carotid artery and jugular vein may relieve the bruit.<sup>33,36</sup> Ligation of the external carotid artery alone has been beneficial;<sup>40,95</sup> in one patient the common carotid was ligated but death ensued because of cerebral infarction.<sup>40</sup>

In a series of 167 cases (161 previously published<sup>5,9,33,38,42,46,48,56,61,62,68,71-76,89,91,92,95,99</sup> and our six), 32 patients died, including two of our patients (cases 5 and 6). Eleven of the patients died postoperatively after craniotomy, and three after procedures in the mastoid and the middle ear. The deaths were due to postoperative surgical complications. In no patient was it possible to remove all of the neoplasm, and in all patients the marked vascularity of the tumor was a severe obstacle, and in almost all, intracranial extension was present. Nineteen patients survived the postoperative period but died later, 13 patients from causes directly concerned with the neoplasm itself.

The 32 deaths offer only an indication of the role of these neoplasms in causing fatality. The intracranial extension of the tumor would appear to be the major cause of death. Neurosurgical postoperative mortality is high, probably because of the extremely difficult technical problems encountered, involving both the great vascularity of the neoplasm and the anatomic relationships.

Four patients died apparently as a result of metastatic disease, although metastatic disease was present at the time of death in six patients, secondary deposits of neoplasm were found in the liver, lungs, spleen, and bones. Intracranial extension of the neoplasm accounted for six deaths.<sup>5,33,38,42,61,75</sup> Poppen and Riemen-schneider's<sup>33</sup> patient survived four years and eight months after the onset of symptoms; at necropsy a large, friable mass displaced the cerebellum and medulla, filled the middle ear and the mastoid air cells, and extended forward to the posterior clinoid process into the petrous ridge and the pharynx. Zak's<sup>42</sup> second patient died of respiratory distress secondary to displacement and deformity of the pons and the medulla by the neoplasm, which had grown through the jugular foramen. Three other patients died of the effects of the disease, although the exact mechanisms causing death could not be determined.<sup>92,93,100</sup> Cerebral

abscess, secondary to middle ear disease, accounted for two deaths.<sup>42,97</sup> Six patients with the disease died, but of other causes, such as cerebral hemorrhage, cerebral infarct, and bronchopneumonia.<sup>9,18,22,38,40,68</sup>

### Summary and Conclusions

Six cases of nonchromaffin paraganglioma of the glomus jugulare are presented. In two patients (case 2 and 4) the signs and symptoms of the disease were aural only. The presence of an aural polyp, marked loss of hearing, and tinnitus were the principal clinical features. In one patient (case 4), even though complete removal appeared to be possible, recurrent neoplasm developed after several years. The neural aspects of the disorder are exemplified in the other four cases; two of the patients died and necropsy was performed. Cranial nerve palsies involving the fifth through the twelfth cranial nerves occurred in three patients (cases 1, 5, and 6). One patient (case 6) in addition had a third cranial nerve palsy. The necropsy findings in cases 5 and 6 illustrate the extensive destruction of the petrous portion of the temporal bone, the extradural extension of the neoplasms, and the encroachment upon vital structures of the posterior fossa.

One hundred and ninety cases in the literature are available to us, and of this group, 165 case abstracts have been examined in addition to those of our own six cases.

### References

1. Rosenwasser, H.: Carotid body tumor of middle ear and mastoid. *Arch. Otolaryng.* 41: 64-67, 1945.
2. Guild, S. R.: Hitherto unrecognized structure, glomus jugularis, in man. *Anat. Rec.* 79 (suppl. 2): 28, 1941.
3. Guild, S. R.: Glomus jugulare, nonchromaffin paraganglion, in man. *Ann. Otol. Rhin. & Laryng.* 62: 1045-1071, 1953.
4. Zettergren, L., and Lindström, J.: Glomus tympanicum. Its occurrence in man and its relation to middle ear tumours of carotid body type. *Acta path. et microbiol. scandinav.* 28: 157-164, 1951.  
Zettergren, L., and Lindström, J.: Glomus tympanicum: its occurrence in man and its relation to middle ear tumors of carotid body type. Pp. 307-308 in *The 1951 Year Book of the Eye, Ear, Nose and Throat*, edited by J. R. Lindsay. Chicago: The Year Book Publishers Inc., 1952, 456 pp.
5. Lattes, R., and Waltner, J. G.: Nonchromaffin paraganglioma of middle ear (carotid-body-like tumor; glomus-jugulare tumor). *Cancer* 2: 447-468, 1949.
6. Huppler, E. G.; McBean, J.B., and Parkhill, Edith M.: Chemodectoma of glomus jugulare: report of case with vocal cord paralysis as presenting finding. *Proc. Staff Meet. Mayo Clin.* 30: 53-58, 1955.
7. LeCompte, P. M.: Tumors of carotid body and related structures (chemoreceptor system). Sec. 4, Fasc. 16, *Atlas of Tumor Pathology*. Washington, D.C.: Armed Forces Inst. Path., 1951, 40 pp.
8. Flynn, T. F., Jr.; Smith, J. J., and Luongo, R.: Nonchromaffin paraganglioma of middle ear; report of case. *A.M.A. Otolaryng.* 61: 231-234, 1955.

9. Zacks, S. I.: Chemodectomas occurring concurrently in neck (carotid body), temporal bone (glomus jugulare) and retroperitoneum; report of case with histochemical observations. *Am. J. Path.* 34: 293-301, 1958.
10. Fisher, E. R., and Hazard, J. B.: Nonchromaffin paraganglioma of orbit. *Cancer* 5: 521-524, 1952.
11. Hollinshead, W. H.: *Anatomy for Surgeons: Volume 1; The Head and Neck*, p. 182-183. New York: Paul B. Hoeber, Inc., 1954, 560 pp.
12. Boyd, J. D.: Development of human carotid body. *Contr. Embryol. Carnegie Inst.* 26: 3-31, 1937.
13. Hammond, W. S.: Development of aortic arch bodies in cat. *Am. J. Anat.* 69: 265-293, 1941.
14. Smith, Christianna: Origin and development of carotid body. *Am. J. Anat.* 34: 87-131, 1924.
15. Lattes, R.: Nonchromaffin paraganglioma of ganglion nodosum, carotid body, and aortic-arch bodies. *Cancer* 3: 667-694, 1950.
16. Kohn, A.: Über den Bau und die Entwicklung der sogenannten Carotisdrüse. *Arch. mikr. Anat.* 56: 81-148, 1900.
17. Dripps, R. D., Jr., and Comroe, J. H., Jr.: Clinical significance of carotid and aortic bodies. *Am. J. M. Sc.* 208: 681-694, 1944.
18. Schmidt, C. F., and Comroe, J. H., Jr.: Functions of carotid and aortic bodies. *Physiol. Rev.* 20: 115-157, 1940.
19. Hollinshead, W. H.: Chromaffin tissue and paraganglia. *Quart. Rev. Biol.* 15: 156-171, 1940.
20. Hollinshead, W. H.: Cytological study of carotid body of cat. *Am. J. Anat.* 73: 185-213, 1943.
21. de Castro, F.: Ueber die Struktur und Innervation des Glomus caroticum beim Menschen und bei den Säugetieren; anatomisch-experimentelle Untersuchungen. *Zschr. ges. Anat.* 89: 250-265, 1929.
22. Watzka, M.: Vom Paraganglion caroticum. *Verh. Anat. Ges.* 42: 108-120, 1934.
23. Maximow, A. A., and Bloom, W.: *A Textbook of Histology*, pp. 248-249. Philadelphia: W. B. Saunders Co., 7th ed., 1957, 628 pp.
24. Patton, B. M.: *Human Embryology*, pp. 541-544. New York: The Blakiston Co., Inc., 2d ed., 1953, 798 pp.
25. Jordan, H. E., and Kindred, J. E.: *Textbook of Embryology*, pp. 387-391. New York: D. Appleton-Century Co., 4th ed., 1942, 613 pp.
26. Arey, L. B.: *Developmental Anatomy; A Textbook and Laboratory Manual of Embryology*, pp. 473-474. Philadelphia: W. B. Saunders Co., 5th ed., 1946, 616 pp.
27. de Winiwarter, H.: Origine et développement du ganglion carotidien; appendice: participation de l'hypoblaste à la constitution des ganglions craniens. *Arch. de biol., Paris* 50: 67-94, 1939.
28. Hollinshead, W. H., and Sawyer, C. H.: Mechanisms of carotid body stimulation. *Am. J. Physiol.* 144: 79-86, 1945.
29. Hollinshead, W. H.: Effects of anoxia upon carotid body morphology. *Anat. Rec.* 92: 255-261, 1945.
30. Comroe, J. H., Jr.: Location and function of chemoreceptors of aorta. *Am. J. Physiol.* 127: 176-191, 1939.

NONCHROMAFFIN PARAGANGLIOMA OF THE GLOMUS JUGULARE

31. Bernthal, T., and Weeks, W. F.: Respiratory and vasomotor effects of variations in carotid body temperature; study of mechanism of chemoreceptor stimulation. *Am. J. Physiol.* 127: 94-105, 1939.
32. Schmidt, C. F.; Comroe, J. H., Jr., and Dripps, R. D., Jr.: Carotid body reflexes in dog. *Proc. Soc. Exper. Biol. & Med.* 42: 31-32, 1939.
33. Poppen, J. L., and Riemenschneider, P. A.: Tumor of carotid body type presumably arising from glomus jugularis. *A.M.A. Arch. Otolaryng.* 53: 453-459, 1951.
34. Lewis, J. S., and Grant, R. N.: Nonchromaffin paraganglioma of middle ear (glomus jugulare tumor). *A.M.A. Arch. Otolaryng.* 53: 406-410, 1951.
35. Capps, F. C. W.: Two cases of haemangeio-endothelioma of middle ear. *J. Laryng. & Otol.* 59: 342-346, 1944.
36. Mattick, W. L., and Burke, E. M.: Glomus jugulare tumors. *Laryngoscope* 62: 311-322, 1952.
37. Alexander, E., Jr.; Beamer, P. R., and Williams, J. O.: Tumor of glomus jugulare with extension into middle ear; (nonchromaffin paraganglioma or carotid-body-type tumor). *J. Neurosurg.* 8: 515-523, 1951.
38. Black, J. I. M.: Tympanic body tumours. *J. Laryng. & Otol.* 66: 315-320, 1952.
39. Williams, H. L.; Childs, D. S., Jr.; Parkhill, E. M., and Pugh, D. G.: Chemodectomas of glomus jugulare (nonchromaffin paragangliomas) with especial reference to their response to roentgen therapy. *Ann. Otol. Rhin. & Laryng.* 64: 546-566, 1955.
40. Birrell, J. H. W.: Jugular body and its tumour. *Australian & New Zealand J. Surg.* 24: 195-206, 1955.
41. Le Compte, P. M.; Sommers, S. C., and Lathrop, F. D.: Case reports. Tumor of carotid body type arising in middle ear. *Arch. Path.* 44: 78-81, 1947.
42. Zak, F. G.: Expanded concept of tumors of glomic tissue. *New York J. Med.* 54: 1153-1165, 1954.
43. Mattick, W. L., and Mattick, J. W.: Some experiences in management of cancer of middle ear and mastoid. *A.M.A. Arch. Otolaryng.* 53: 610-621, 1951.
44. Lundgren, N.: Tympanic body tumours in middle ear; tumours of carotid body type. *Acta otolaryng.* 37: 367-379, 1949.
45. Berg, N. O.: Tumours arising from tympanic gland (glomus jugularis) and their differential diagnosis. *Acta path. et microbiol. scandinav.* 27: 194-221, 1950.
46. Dockerty, M. B.; Love, J. G., and Patton, M. M.: Nonchromaffin paraganglioma of middle ear; report of case in which clinical aspects were those of brain tumor. *Proc. Staff Meet. Mayo Clin.* 26: 25-32, 1951.
47. Winship, T.; Klopp, C. T., and Jenkins, W. H.: Glomus-jugularis tumors. *Cancer* 1: 441-448, 1948.
48. Henson, R. A.; Crawford, J. V., and Cavanagh, J. B.: Tumours of glomus jugulare. *J. Neurol. Neurosurg. & Psychiat.* 16: 127-138, 1953.
49. Kipkie, G. F.: Simultaneous chromaffin tumors of carotid body and glomus jugularis. *Arch. Path.* 44: 113-118, 1947.
50. Winship, T., and Louzan, J.: Tumors of glomus jugulare not associated with jugular vein. *A.M.A. Arch. Otolaryng.* 54: 378-383, 1951.



51. Horn, R. C., Jr., and Stout, A. P.: Granular cell myoblastoma Surg. Gynec. & Obst. 76: 315-318, 1943.
52. Fuller, R. H.: Tumor of glomus jugularis; report of case. U. S. Nav. M. Bull. 49: 1141-1144, 1949.
53. De Lisa, D. A.: Tumor of glomus jugularis. Arch. Otolaryng. 51: 924-927, 1950.
54. Alexander, E., Jr., and Adams, S.: Tumor of glomus jugulare; follow-up study two years after roentgen therapy. J. Neurosurg. 10: 672-674, 1953.
55. Weille, F. L., and Lane, C. S., Jr.: Surgical problems involved in removal of glomus-jugulare tumors. Laryngoscope 61: 448-459, 1951.
56. Tamari, M. J.; McMahon, R. J., and Bergendahl, E. H.: Carotid body-like tumors of temporal bone, with particular reference to glomus-jugulare tumors. Ann. Otol. Rhin. & Laryng. 60: 350-364, 1951.
57. Cleary, J. A.: Nonchromaffin paraganglioma (glomus jugulare tumor) of middle ear. A.M.A. Arch. Otolaryng. 56: 378-384, 1952.
58. Brown, K. B.: Nonchromaffin paraganglioma of middle ear. Ann. Otol. Rhin. & Laryng. 60: 692-694, 1951.
59. Perez-Toledo, A., and Taveras, J. E.: Glomus jugulare tumor; report from Puerto Rico. A.M.A. Arch. Otolaryng. 60: 49-54, 1954.
60. Strong, M. S.: Glomus jugulare tumor of middle ear; clinical note. A.M.A. Arch. Otolaryng. 60: 145-148, 1954.
61. Garvey, J. L., and Claudon, D. B.: Nonchromaffin paraganglioma of middle ear and abdomen. Neurology 3: 621-626, 1953.
62. Albernaz, J. G., and Bucy, P. C.: Nonchromaffin paraganglioma of jugular foramen. J. Neurosurg. 10: 663-671, 1953.
63. Land, R. N.: Glomus jugularis tumor of middle ear; case report. Radiology 59: 70-76, 1952.
64. Barton, R. T., and Thee, E. J., Jr.: Nonchromaffin paraganglioma; report of three cases. J.A.M.A. 151: 619-621, 1953.
65. Riemenschneider, P. A., and others: Roentgenographic diagnosis of tumors of glomus jugularis. Am. J. Roentgenol. 69: 59-65, 1953.
66. Block, M. A.; Dockerty, M. B., and Waugh, J. M.: Nonchromaffin paraganglioma; report of case. Cancer 8: 97-100, 1955.
67. Smetana, H. F., and Scott, W. F., Jr.: Malignant tumors of nonchromaffin paraganglia. Mil. Surgeon 109: 330-349, 1951.
68. Bickerstaff, E. R., and Howell, J. S.: Neurological importance of tumours of glomus jugulare. Brain 76: 576-593, 1953.
69. Towson, C. E., and McNelis, F. J.: Tumor of glomus jugulare; report of case. A.M.A. Arch. Otolaryng. 59: 152-158, 1954.
70. Davol, R. T.: Glomus jugularis tumor of middle ear; report of early case. A.M.A. Arch. Otolaryng. 62: 436-437, 1955.
71. Capps, F. C. W.: Glomus jugulare tumours in middle ear. J. Laryng. & Otol. 66: 302-314, 1952.

72. Magarey, F. R.: Tumours of glomus jugulare. *J. Laryng. & Otol.* **66**: 321-326, 1952.
73. Bennett, Maxine; ZuRhein, Gabriele M., and Bast, T. H.: Glomus jugulare tumor with intracranial extension; report of case exhibiting ossifying obliterative labyrinthitis. *A.M.A. Arch. Otolaryng.* **66**: 257-265, 1957.
74. Hoople, G. D.; Bradley, W. H.; Stoner, L. R., and Brewer, D. W.: Histologically malignant glomus jugulare tumor; case report. *Laryngoscope* **68**: 670-675, 1958.
75. Marinho, R., and Torres, E. T.: Glomus jugularis tumor (nonchromaffin paraganglion of middle ear). *Laryngoscope* **67**: 88-92, 1957.
76. Rosenwasser, H.: Metastasis from glomus jugulare tumors; discussion of nomenclature and therapy. *A.M.A. Arch. Otolaryng.* **67**: 197-203, 1958.
77. Capps, F. C.: Chemodectoma or tumor of glomus jugulare and tympanic bodies. *A.M.A. Arch. Otolaryng.* **67**: 556-559, 1958.
78. Arnvig, J.: Two cases of nonchromaffin paraganglioma in middle ear. *Ann. Otol. Rhin. & Laryng.* **66**: 399-405, 1957.
79. Khanolkar, V. R.: Granular cell myoblastoma. *Am. J. Path.* **23**: 721-739, 1947.
80. Holesh, S.: Diagnosis of tumours of glomus jugulare. *Lancet* **1**: 169-170, 1955.
81. Rosen, S.: Glomus jugulare tumor of middle ear with normal drum; improved biopsy technique. *Ann. Otol. Rhin. & Laryng.* **61**: 448-451, 1952.
82. Gibson, D. M., and Proud, G. O.: Glomus jugulare tumor. *J. Kansas M. Soc.* **52**: 581-583, 1951.
83. Aquino, J. A.: Glomus jugular tumors. *A.M.A. Arch. Otolaryng.* **65**: 263-268, 1957.
84. Hierons, R., and Meadows, S. P.: Glomus jugulare tumour presenting with papilloedema and obscurations of vision. *Proc. Roy. Soc. Med.* **47**: 298-299, 1954.
85. Amman, W. C.: Case of nonchromaffin paraganglioma. *A.M.A. Arch. Otolaryng.* **58**: 738-739, 1953.
86. Rosenwasser, H.: Glomus jugularis tumor of middle ear (carotid body tumor, tympanic body tumor, nonchromaffin paraganglioma). *Laryngoscope* **62**: 623-633, 1952.
87. Salkeld, C. R.: Case of glomus jugulare tumour. *J. Laryng. & Otol.* **67**: 291-292, 1953.
88. Ballantyne, J. C.: Glomus jugulare tumour—report of case. *J. Laryng. & Otol.* **67**: 293-296, 1953.
89. Bast, T. H.: Ossification of labyrinth in case of glomus jugulare tumor. *A.M.A. Arch. Otolaryng.* **66**: 739; discussion, 739-740, 1957.
90. Brown, L. A.: Glomus jugulare tumor of middle ear. Clinical aspects. *Laryngoscope* **63**: 281-292, 1953.
91. Crue, B. L., and others: Syndrome of jugular foramen. *A.M.A. Arch. Otolaryng.* **63**: 384-391, 1956.
92. Stewart, J. P.; Ogilvie, R. F., and Sammon, J. D.: Tumours of glomus jugulare and paraganglion juxtavagale of ganglion nodosum. *J. Laryng. & Otol.* **70**: 196-239, 1956.
93. McNeill, K. A., and Milner, G. A. W.: Bilateral tumour of glomus jugulare. *J. Laryng. & Otol.* **69**: 430-431, 1955.

94. Chambers, W. R.: Tumor of glomus jugulare resembling brain tumor. *J. Internat. Coll. Surgeons* 22: 691-694, 1954.
95. Hooper, R. S.: Glomus jugulare tumour; clinical and radiological features. *J. Fac. Radiologists* 7: 77-89, 1955.
96. Simpson, I. C., and Dallachy, R.: Review of tumours of glomus jugulare with reports of three further cases. *J. Laryng. & Otol.* 72: 194-226, 1958.
97. Siekert, R. G.: Neurologic manifestations of tumors of glomus jugulare, chemodectoma, non-chromaffin paraganglioma or carotid-body-like tumor. *A.M.A. Arch. Neurol. & Psychiat.* 76: 1-13, 1956.
98. Figi, F. A., and Weisman, P. A.: Cancer and chemodectoma in middle ear and mastoid. *J. A. M. A.* 156: 1157-1162, 1954.
99. Shambaugh, G. E., Jr.: Surgical approach for so-called glomus jugulare tumors of middle ear. *Laryngoscope* 65: 185-198, 1955.
100. Conley, J. J.: Multiple paragangliomas in head and neck; case report. *Ann. Otol. Rhin. & Laryng.* 65: 356-360, 1956.
101. Bradley, W. H., and Maxwell, J. H.: Neoplasms of middle ear and mastoid; report of 54 cases. *Laryngoscope* 64: 533-556, 1954.