

CORTICOSTEROIDS* ADMINISTERED INTRADURALLY FOR RELIEF OF SCIATICA

ARJUN D. SEHGAL, M.B., B.S.,† and W. JAMES GARDNER, M.D.

Department of Neurological Surgery

IT has been shown that 58 per cent of patients with sciatica due to extradural adhesions may be benefited by hydrocortisone in one per cent procaine hydrochloride solution injected into the epidural space via the sacral hiatus.¹ This injection is accompanied by straight-leg raising exercises designed to mobilize the nerve roots. When this extradural treatment fails, or in cases where the causative lesion is known or presumed to be in the subarachnoid space, we have injected corticosteroids intradurally by lumbar puncture. The early results have been encouraging.

Material

Thirty-six patients with sciatica have received intradural (subarachnoid) injections of corticosteroids. The average duration of sciatica was three and one-half years, and all required analgesics for pain. Twenty-nine patients had one or more myelograms prior to the treatment, and in five a second myelogram was followed by an immediate and continuing increase of pain. Twenty-eight patients had undergone one or more laminectomies, twenty-five had received extradural injections of hydrocortisone in procaine, two had received corticotropin (ACTH) intravenously, and five had received corticosteroids orally—all with little or no benefit. In eight patients, arachnoiditis was confirmed at operation before the intradural injections were given.

After a preliminary trial of corticosteroids in other forms, methylprednisolone acetate‡ was selected as the least irritating and longest acting preparation for subarachnoid administration.

Method

With the patient lying on his side, lumbar puncture is performed, and from 40 to 80 mg. of methylprednisolone acetate is injected (*Fig. 1*). If the patient's pain is aggravated by straight-leg raising, 50 mg. of procaine hydrochloride crystals in 3 or 4 ml. of cerebrospinal fluid is then injected. The patient is turned on his back, and straight-leg raising exercises with jugular compression (*Fig. 2*) are carried out in an effort to mobilize the nerve roots and to disseminate further the therapeutic agent. After three hours the patient is discharged to his home and is advised to resume normal activity. In instances in which there is only partial relief of pain, the injection may be repeated.

* *The drugs used in this study were kindly supplied in part by The Upjohn Company, 301 Henrietta Street, Kalamazoo 99, Michigan.*

† *Fellow in the Department of Neurological Surgery.*

‡ *Depo-Medrol (methylprednisolone acetate in sodium chloride), The Upjohn Co.*

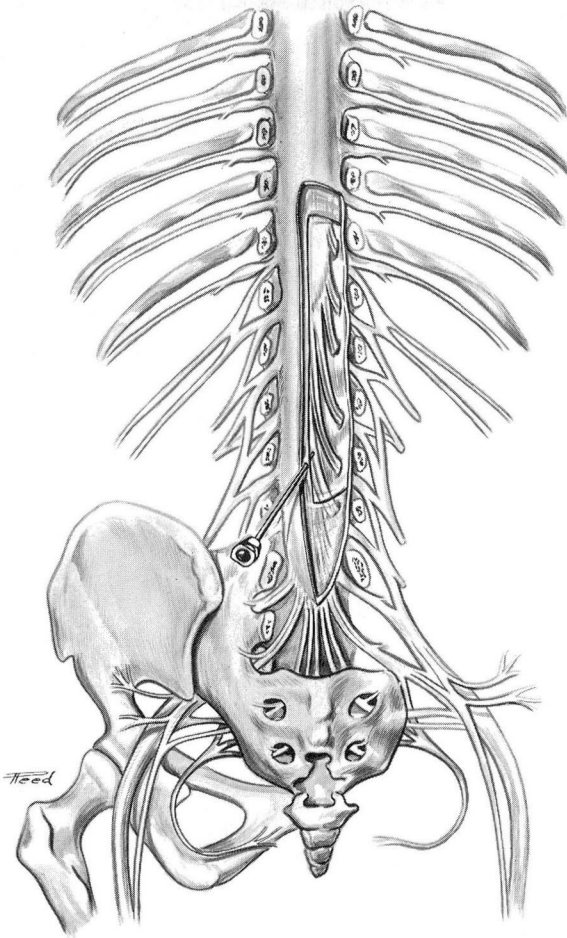


Fig. 1. Sketch showing placement of the needle into the subarachnoid space so that the therapeutic agent may follow the naked nerve roots into their dural sleeves.

Results

A follow-up of from 2 to 11 months has disclosed complete relief of sciatica in 14 patients and at least 50 per cent relief in 12 (*Table 1*). These 26 patients were able to resume their daily work without need for analgesics. Ten patients had little or no relief. In two of these, cerebrospinal fluid was not encountered at lumbar puncture presumably because of obliteration of the subarachnoid space by arachnoiditis. There is thus no proof that an intradural injection was accomplished. In two patients unrelieved, subsequent psychiatric diagnosis was "conversion reaction."

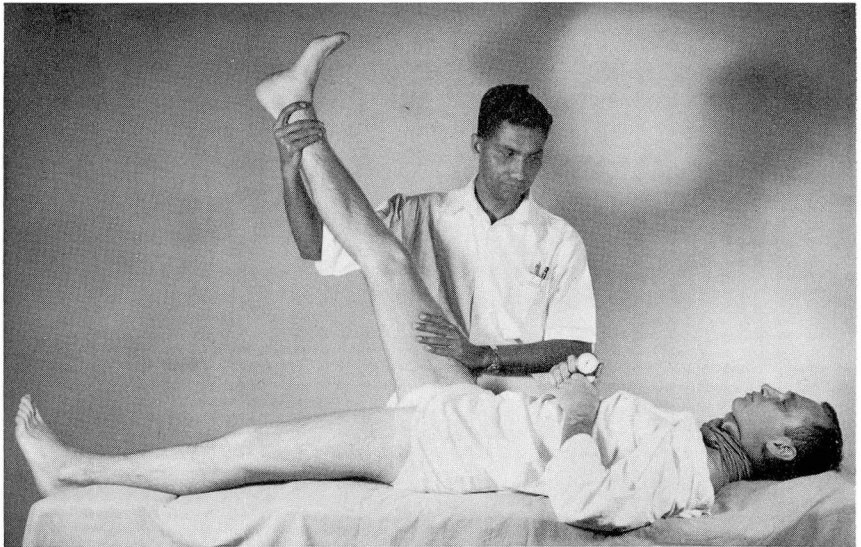


Fig. 2. Straight-leg raising combined with jugular compression to stretch subarachnoid adhesions and to encourage further dissemination of the therapeutic agent.

Table 1.—Data on 36 patients with sciatica treated by intradural injections of corticosteroids

Brand of corticosteroid	Each dose, mg.	Injections, total number	Transient severe pain in legs	Results, number of patients		
				Good	Fair	Poor
Hydrocortone†	100	4	1	0	2	1
Solu-Cortef‡	100	11	3	1	3	3
Solu-Medrol‡	40 to 80	21	7	6	5	4
Depo-Medrol‡	40 to 80	12	0*	7	2	2
		Total	11	14	12	10

*An additional 40 patients have since received Depo-Medrol without clinical reaction, but with occasional transient pleocytosis.

†Merck, Sharp & Dohme.

‡The Upjohn Company.

Cell counts and protein estimations of the cerebrospinal fluid were made in several instances at various intervals after injection, and seldom showed significant change. Prompt clinical reactions consisting of intermittent, spasmodic, severe pain in the lower back and in the legs occurred in 11 patients. These symptoms

cleared in from two to three hours and did not affect the final result. They may have been due to substances added to increase the solubility of the corticosteroid since they have not occurred with the use of methylprednisolone acetate that contains no such substances.

Discussion

Intradural adhesions may result from nerve root compression, from trauma, surgical and otherwise, and from myelography, particularly when blood also is present in the subarachnoid space. Corticosteroids, by their antiinflammatory and antiallergenic action, reduce congestion and inflammation. Hydrocortisone, particularly, inhibits the development of foreign-body giant-cell granulomata and fibrous tissue that produces the piarachnoidal adhesions² from retained contrast medium or from trauma. The effect of corticosteroids on mesodermal elements (of which the arachnoid is one) is a direct one, and local application is more effective than is the systemic.²

Aside from the transient reactions described, no harmful effects followed single or repeated intrathecal injections of corticosteroids. Tissue study in experimental animals by Feldman, Behar, and Samueloff,² and clinical and pathologic study by Pieper and Fields³ of patients treated for amyotrophic lateral sclerosis, likewise have revealed no harmful effects on the piarachnoid or nerve roots.

Conclusion

The intradural administration of corticosteroids has been used in 36 cases of sciatica presumed to be due to intradural lesions. The preliminary results, we believe, justify the cautious use of this therapy in carefully selected cases.

References

1. Goebert, H. W. and associates: Sciatica: treatment with epidural injections of procaine and hydrocortisone. *Cleveland Clin. Quart.* 27: 191-197, 1960.
2. Feldman, S.; Behar, A. J., and Samueloff, M.: Effect of cortisone and hydrocortisone on piarachnoid adhesions; experimental study. *A.M.A. Arch. Neurol. & Psychiat.* 74: 681-688, 1955.
3. Pieper, S. J. L., and Fields, W. S.: Failure of amyotrophic lateral sclerosis to respond to intrathecal steroid and vitamin B₁₂ therapy. *Neurology* 9: 522-526, 1959.