

ARTIFICIAL HIBERNATION

Report of Three Cases Including Two with Dialysis

JAMES R. GEYER, M.D.,*

Department of Urology

and

SATORU NAKAMOTO, M.D.†

Department of Artificial Organs

ARTIFICIAL hibernation has been used at the Cleveland Clinic Hospital only as a last resort in the treatment of extremely ill patients. Its status is that of adjunctive, not specific, therapy. In 1955, Kolff¹ reported nine patients in whom the chief indications for hibernation were hyperpyrexia, uncontrollable deterioration, uncontrollable fall in blood pressure, ileus with severe distention, convulsions, extreme restlessness, coma, and cyanosis. After artificial hibernation, beneficial effects were evident, though there were no long-term survivors. Black and Kolff² recently reported the cases of two patients whose recovery was helped by hibernation. A gratifying result in one patient was the cessation of gastrointestinal hemorrhage from a stress ulcer.

This study presents reports of three additional patients, in order to illustrate the current use of artificial hibernation. Two of the patients were also treated with hemodialysis. Because it has been described in detail previously,^{1,2} the technic, which is based on that of Laborit, Huguenard, and others,³ will not be discussed.

Case Reports

Case 1. A 58-year-old man‡ underwent operation at the Cleveland Clinic Hospital for removal of a large substernal nodular goiter and a left carotid body tumor. Insertion of a left internal carotid artery (freeze-dried) homograft was required. Postoperatively, the patient had right flaccid hemiplegia and remained comatose. The endotracheal tube that had been inserted at the time of operation had to be left in place. In the hope of preventing further brain damage, artificial hibernation was instituted in the recovery room by maintaining the rectal temperature between 86 and 93 F. with icebags and a water-cooled mattress while preventing shivering with lytic cocktails^{1,2} (meperidine hydrochloride, chlorpromazine, and promethazine hydrochloride). Chloramphenicol was administered prophylactically. The blood pressure was supported with 6 per cent dextran and *l*-norepinephrine bitartrate, and a hydrocortisone preparation was administered on one occasion. *Figure 1* shows the progression of vital signs and urinary output.

This study was prepared under the guidance and sponsorship of W. J. Kolff, M.D., Head of the Department of Artificial Organs.

**Fellow in the Department of Urology.*

†Fellow in the Department of Artificial Organs.

‡This patient was treated in collaboration with Dr. George Crile, Jr., Department of General Surgery.

ARTIFICIAL HIBERNATION

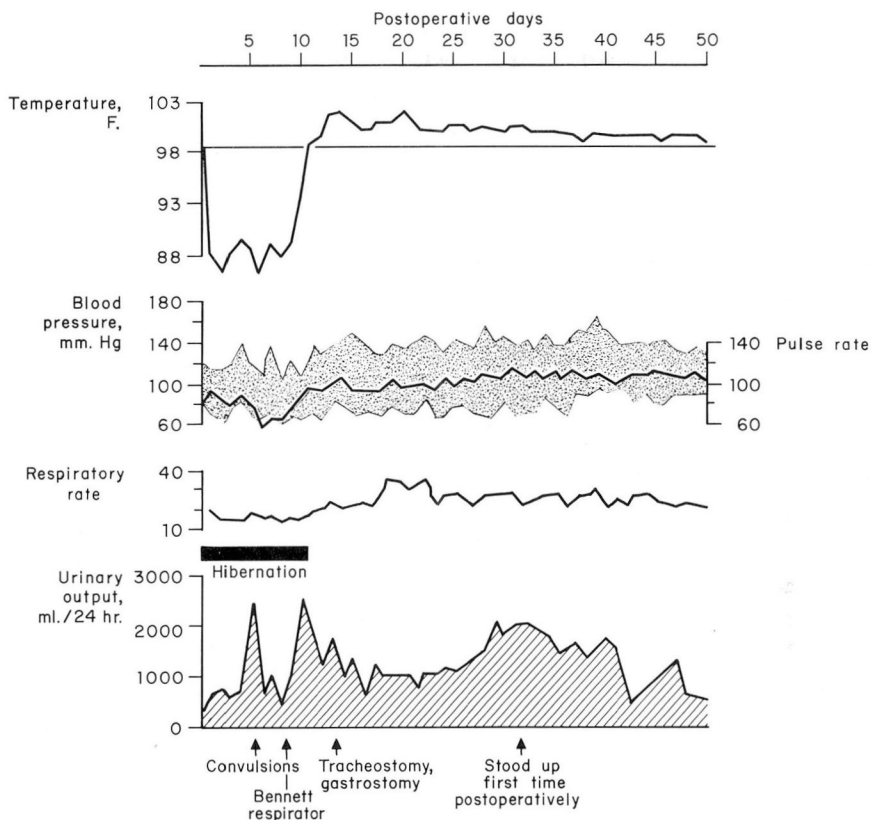


Fig. 1. Case 1. Artificial hibernation was started in the evening after surgery. The lowest temperature was 86 F. On the fifth day, convulsions occurred and papilledema was observed; diphenylhydantoin sodium was administered. A Bennett respirator was employed when the blood pH was 7.28 and the serum carbon dioxide was 32 mEq. per liter. Rewarming was accomplished during the ninth and tenth postoperative days.

On the fifth postoperative day, convulsions and papilledema were observed, and diphenylhydantoin sodium was administered. A Bennett respirator was used to correct respiratory acidosis (blood pH, 7.28, serum carbon dioxide content, 32 mEq. per liter). On the ninth postoperative day, rewarming to 95 F., and to 98 F. on the tenth day ended the artificial hibernation. Three days later a tracheostomy and a feeding gastrostomy were performed under local anesthesia.

Except for a morbilliform rash, a febrile episode (probably due to pneumonitis), and minimal bleeding from the gastrostomy, the patient gradually improved. He became more responsive, although aphasic, and finally was able to stand up for the first time 31 days after operation. Within two weeks the urethral catheter, tracheostomy tube, and gastrostomy tube were removed. On the fiftieth postoperative day the patient

was discharged from the hospital. He could ambulate with a cane, feed himself, partially dress himself, and speak a few words.

Comment. It was hoped that artificial hibernation would lessen the brain damage that had occurred after the clamping of the left carotid artery during the operation. The subsequent recovery of the patient indicated that artificial hibernation may have been a useful adjunct, but it is impossible to assess fully the value of this treatment.

Case 2. A 30-year-old man was admitted to the hospital in a stupor. Twelve years prior to admission he was in an automobile accident and sustained injuries that included a ruptured bladder. To provide urinary drainage, several operations were performed at another hospital: suprapubic cystostomy, left nephrostomy, and finally bilateral uretero-sigmoidostomies. Also, calculi were removed from the left kidney. These operations were followed by repeated attacks of pyelonephritis.

When first examined here, the rectal temperature was 105 F.; pulse rate, 160; respiratory rate, 132; and blood pressure, 100/60 mm. of Hg. He appeared pale, emaciated and dehydrated, and had nuchal rigidity, nystagmus, and generalized muscular fasciculations. The laboratory findings were: blood hemoglobin, 9.6 gm. per 100 ml.; blood cell volume, 30 ml. per 100 ml.; white cell count, 17,000 per cubic millimeter. Other data are summarized in *Table 1*. There was moderate uremia and severe acidosis.

Table 1.—*Changes in blood urea and serum electrolyte concentrations (case 2)*

Laboratory findings	Hospital day									
	1		2	3	4	5	6	7	8	9
	Hemodialysis									
	Before	After								
Blood urea, mg./100 ml.	129	52	97	117	—	66	—	94	—	—
Serum sodium, mEq./l.	127	127	132	132	132	134	—	148	—	146
Serum potassium, mEq./l.	3.0	4.6	3.8	4.6	4.6	4.9	—	5.1	—	3.9
Serum chloride, mEq./l.	93	94	96	—	—	—	—	114	—	113
Serum/carbon dioxide content, mEq./l.	11.2	18	17.2	—	—	—	—	18.9	—	15.1

Immediate hemodialysis with the artificial kidney improved his general condition, and further investigation was undertaken. The spinal fluid pressure was 164 mm. of water, and a specimen of fluid was cloudy with many white cells, but no organisms. The culture remained sterile. Penicillin and sulfadiazine were administered intravenously, and streptomycin was injected intramuscularly.

On the third hospital day, seizures developed and the patient lost consciousness. Coagulase-positive *Staphylococcus aureus* was cultured from the blood on two occasions. Administration of streptomycin and sulfadiazine was discontinued since the blood sulfa

ARTIFICIAL HIBERNATION

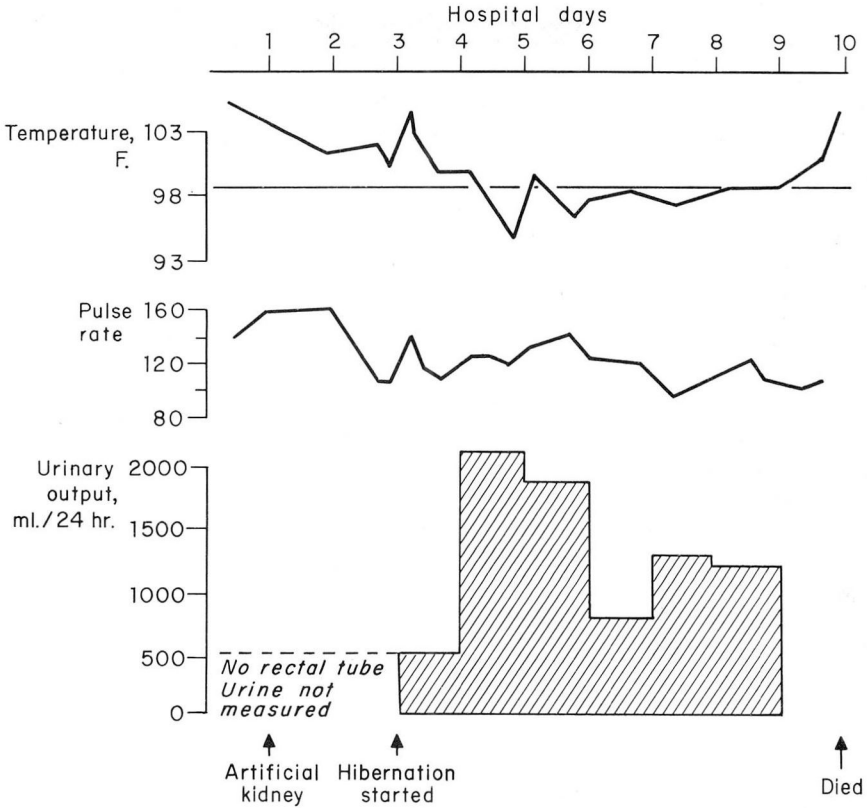


Fig. 2. Case 2. Artificial hibernation was started on the third hospital day because of septicemia and hyperpyrexia. The temperature was reduced to 95 F. in 48 hours, and the pulse rate was decreased. The patient improved temporarily, but treatment was unsuccessful and he died on the tenth hospital day.

concentration was 32 mg. per 100 ml.; chloramphenicol was administered. Since his clinical condition was unquestionably out of control and the course was rapidly deteriorating, artificial hibernation was instituted that day with the use of ice packs, chlorpromazine hydrochloride, and promethazine hydrochloride. The temperature was reduced from 104 to 100 F. in 24 hours, and to 95 F. in 48 hours. The temperature was then maintained at about 98 F. for six days (ninth hospital day). *Figure 2* shows the course of the temperature, pulse rate, and urinary output.

Improvement in his responsiveness and the ability to take some fluid by mouth were encouraging changes. Nevertheless, his condition deteriorated later with the development of conjunctival petechiae, systolic cardiac murmur, disappearance of left popliteal and ankle pulses, decrease of urinary output as measured by an indwelling rectal tube, increase of blood urea content, severe anemia, and decrease in the number

of blood platelets. Intravenous administration of novobiocin and low-molecular dextran, left lumbar sympathetic block, and transfusion of packed blood cells could not reverse the situation. He died on the tenth hospital day, in stupor, having a spiking fever, generalized ecchymoses, and hypotension.

The autopsy revealed the presence of bilateral ureterosigmoidostomies; chronic pyelonephritis; coagulase-positive staphylococcus (blood culture); acute bacterial endocarditis; vegetative aortic valvulitis; multiple myocardial abscesses; cerebellar abscesses; emboli to the spleen, right kidney, and left lower extremity; active duodenal ulcer; and hypoplastic adrenal cortex.

Comment. This patient was moribund when transferred from another hospital. Dialysis with the artificial kidney and artificial hibernation helped to extend his life.

Case 3. A 39-year-old woman* underwent open-heart surgery with the disc oxygenator, for the repair of a large interatrial septal defect. Her recovery was satisfactory except for fever until the fifth postoperative day when an acute schizophrenic episode occurred. Chlorpromazine, 100 mg. every six hours, was administered, and she became depressed and occasionally even catatonic. Roentgenograms of the chest showed evidence of clearing of atelectasis, but the temperature remained between 100 and 101 F. A brief episode of atrial fibrillation occurred, which converted spontaneously to sinus rhythm. On the eleventh postoperative day, administration of chlorpromazine was discontinued because of slurred speech and cogwheel rigidity of the arms. The persistent unexplained fever was now accompanied by hyperactivity. Chloramphenicol was administered, then prednisone for three days, since it had been useful in other patients who had unexplained fever (commissurotomy syndrome or "pump fever") after open-heart surgery.

Clinically, the picture changed from acute psychosis to toxic delirium with progressively elevated temperature and leukocytosis. There was no apparent site of infection, and the neurologic examination revealed nothing abnormal. A chest roentgenogram was normal; blood cultures were sterile; and spinal fluid was normal. A urine culture contained *Proteus vulgaris*, but urinary symptoms were absent. Empirically, erythromycin and chloramphenicol, then penicillin and chloramphenicol were given in large doses.

On the twenty-second postoperative day, laboratory studies revealed that serum sodium concentration was 166 mEq. per liter; serum potassium, 4.1 mEq. per liter; serum chloride, 133 mEq. per liter; serum carbon dioxide content, 19.5 mEq. per liter; blood urea, 143 mg. per 100 ml.; hemoglobin, 14.3 gm. per 100 ml.; cell volume, 40 ml. per 100 ml.; white cell count, 20,800 per cubic millimeter. The next day, dialysis with the artificial kidney was performed and artificial hibernation was instituted; the temperature declined to 94 F. *Figure 3* shows the course of the vital signs and the urinary output. In spite of a large urinary output, the blood urea concentration was 252 mg. per 100 ml. on the twenty-seventh postoperative day. The body temperature was allowed to return to 98 F., and artificial hibernation was discontinued after five days. The patient's mental condition improved, although she was still depressed.

*This patient was treated in collaboration with Dr. Donald B. Effler, Department of Thoracic Surgery.

ARTIFICIAL HIBERNATION

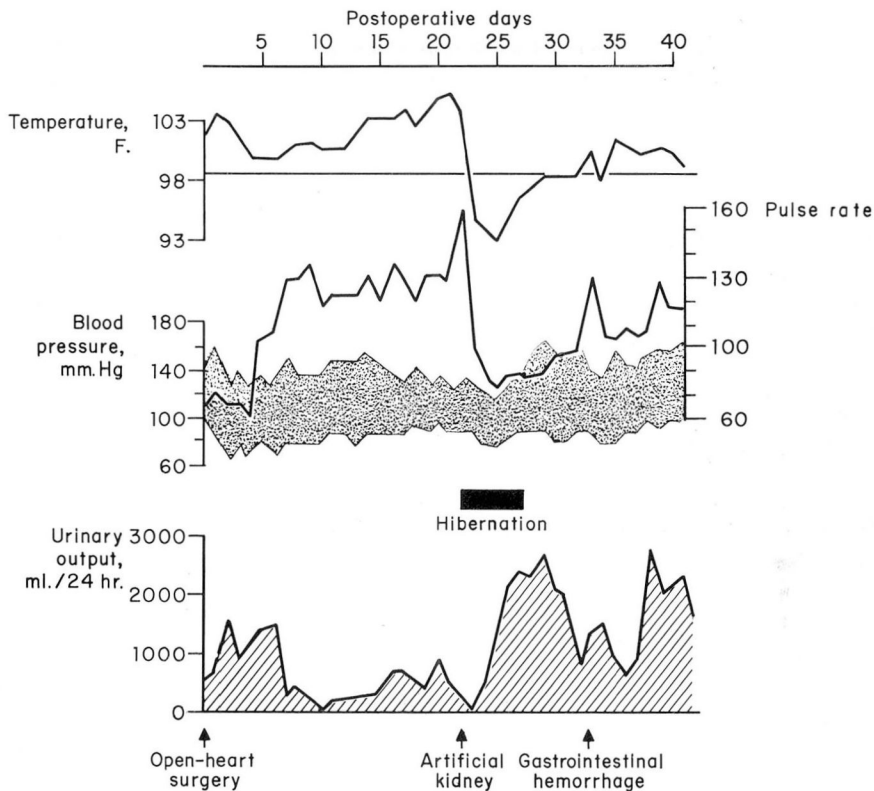


Fig. 3. Case 3. Artificial hibernation was administered after treatment with the artificial kidney on the twenty-third postoperative day. The temperature was reduced to 93 F. and the pulse rate was also reduced significantly. After cooling was discontinued, the temperature and the pulse rate remained normal until gastrointestinal hemorrhage occurred on the thirty-third postoperative day.

The blood urea content decreased to 47 mg. per 100 ml. by the thirty-third postoperative day. Then, when an upper gastrointestinal hemorrhage occurred, the patient received a transfusion of 1500 ml. of whole blood. Medical management for peptic ulcer was instituted. For the first time since artificial hibernation, fever recurred and lasted one week. Proctoscopic examination and gastrointestinal roentgenograms revealed no evidence of a lesion.

Without further incident the patient gradually improved both mentally and physically. Blood urea values returned to normal. Throughout the entire postoperative period the preoperative murmur was absent and the chest roentgenograms showed evidence of a decrease in cardiac size. Fifty days after operation she was well enough to return home.

Comment. This bizarre postoperative course reached a peak with delirium, fever, leukocytosis, and electrolyte imbalance. Despite the fact that a satisfactory explanation was never obtained, treatment with the artificial kidney and artificial hibernation helped recovery.

Summary

Three cases have been presented in which artificial hibernation was used. In two patients the artificial kidney was also employed. Although one patient died, artificial hibernation was thought to be beneficial in cerebral infarction, hyperpyrexia, septicemia, and in a complex of postoperative problems including unexplained pyrexia and delirium.

References

1. Kolff, W. J.: Artificial hibernation; technic, and observation on seriously ill patients. *Cleveland Clin. Quart.* 22: 109-123, 1955.
2. Black, M. W., and Kolff, W. J.: Artificial hibernation. A report of two patients treated successfully by the French technique and a new pulsating cooling mattress. *Ohio M. J.* 56: 943-947, 1960.
3. Laborit, H.; Huguenard, P., and others: *Pratique de l'Hibernothérapie en Chirurgie et en Médecine*. Paris: Masson & Cie., Éditeurs, 1954, 256 pp.